

Achieving Target Refraction After Phakic Visian ICL

Rawan M. Al Hedaithy OD¹, Anoud F. Al Saati MD², Tahani A. Al Qahtani MSc³, and Sultan E. Al Zaaidi MD²

¹Optometry Doctor, College of Applied Medical Sciences, Optometry and Vision Science, King Saud University, Riyadh, Saudi Arabia.

²Consultant Ophthalmologist, Prince Sultan Military Medical City, Riyadh, Saudi Arabia.

³Lecturer, College of Applied Medical Sciences, Optometry and Vision Science, King Saud University, Riyadh, Saudi Arabia.

*Correspondence:

Rawan Mogbil Al Hedaithy, Department of Optometry and Visual Sciences, College of Applied Medical Sciences, King Saud University, Saudi Arabia, Tel: +966568888009.

Received: 24 November 2019; Accepted: 28 December 2019

Citation: Rawan M. Al Hedaithy, Anoud F. Al Saati, Tahani A. Al Qahtani, et al. Achieving Target Refraction After Phakic Visian ICL. *Ophthalmol Res.* 2019; 2(1): 1-3.

ABSTRACT

Purpose: To study the experience of phakic Visian Implantable Collamer lens (ICL) in single center.

Methods: Retrospective chart review of patients with myopia ranging from -3.25 to -21.00 D, who underwent ICL implantation, during the period between February 2010 to August 2016 in Prince Sultan Military Medical City (PSMMC) in Riyadh and completed at least 3 months of follow up.

Results: Total of 50 eyes of 29 patients who underwent implantation of Visian ICL phakic lenses were included. Twenty-two patients were female (75.9%) and 7 were male (24.1%) with mean age \pm standard deviation (SD) 28.59 \pm 5.82 (range 20 – 43 years). The results showed significant improvement in spherical equivalent (SE), between preoperative and postoperative sphere, cylinder, and BCVA ($P < 0.001$). Preoperatively the mean SE was -10.35 \pm 3.52D (range -4.00 to -22.50D) and postoperatively -0.41 \pm 0.86D (range +0.50 to -3.75D). Preoperative LogMAR BCVA was 0.07 \pm 0.13 and postoperative was 0.01 \pm 0.04. There was no significant difference in intraocular pressure (IOP) between preoperative (mean=14.18 \pm 1.94 mmHg) and postoperative (mean = 15.13 \pm 5.57), ($P = 0.499$). The vault of ICL was low in 3 eyes, high in 5 eyes, and good in 42 eyes. One eye had elevation of IOP postoperatively required ICL explanation and other complication occurred related to the ICL or the surgery.

Conclusion: ICL implantation is an effective surgical option for correction of moderate to high myopia. Further studies are needed for its long-term effect and safety.

Keywords

Implantable Collamer Lens, Posterior chamber intraocular lens, Phakic IOL, ICL implantation, Myopia, Visual acuity.

Introduction

Refractive surgery has been performed for many years. However, there are limitations that prevents surgeons from performing corneal procedures such as high refractive errors, low corneal thickness or borderline corneal indices. One of the surgical options is the phakic lens (Visian Implantable Collamer Lens (ICL)) which was developed for treatment of refractive errors. There are three designs of phakic IOL available: angle supported, iris-fixated and posterior chamber phakic lenses [1]. The current study looked at the the Visian Implantable Collamer Lens (ICL) which was

developed as a posterior chamber phakic IOL. It was approved by FDA in December 2005 for correction of spherical myopia and myopic astigmatism. The ICL has been reported to be effective for the correction of moderate to high ametropia [2-4].

This study included 50 eyes of 29 patients with age range from 18-40 years of old who underwent unilateral or bilateral ICL implantation.

Patients who failed to complete follow up, age below 18 or above 40, or hypermetropic were excluded. Also, any patient who had ophthalmic disease, keratoconus, forme fruste keratoconus cornea (FFKC), ectasia, post crosslinking, post refractive surgery, or had systemic diseases such as diabetes mellitus (DM), rheumatological

disease, thyroid disease, or atopy were excluded.

The patients were identified from the operating room records and the ICL log books. Retrospective review of the charts done by the investigators utilizing the data collection sheet.

Patients were evaluated clinically by the following:

Full ophthalmic examination, best correct visual acuity (BCVA) by dry and wet refraction, corneal topography using Oculus Scheimpflug camera (Pentacam), Internal anterior chamber depth (endothelial to anterior phakic lens capsule) 3 mm or more, specular microscopy, IOP using Goldmann applanation tonometry, and white to white measurement using Caliber/Optical (IOL Master) or both.

The data collection sheet included:

- Demographic data (age and gender).
- Preoperative data: the refractive error, spherical equivalent, best corrected visual acuity (BCVA), anterior chamber depth, intraocular pressure (IOP), white to white diameter, corneal thickness, k-readings (steep, flat & average K), calculations of the ICL power, and model of the implanted ICL.
- Inter-Operative complications.
- Postoperative data: follow up date, uncorrected visual acuity (UCVA), BCVA and the refraction if UCVA less than 20/20, spherical equivalent, IOP, status of the ICL vault & rotation if indicated), and status of the crystalline lens at last follow up.

Statistical Analysis

Statistical analysis was done using Wilcoxon test in SPSS software, version 22.0. The results were expressed as mean ± standard deviation (SD), and a value of P < 0.001 was considered statistically significant.

Ethical consideration

Ethical approval was obtained from the Research Ethics Committees of Collage of Applied Medical Sciences, King Saud University & Prince Sultan Military Medical City.

Results

In this study, a total of fifty eyes of twenty-nine patients who underwent implantation of spheric and toric Visian ICL phakic lenses were included. Twenty-two patients were female (75.9%) and 7 were male (24.1%) with mean age of 28.59 ± 5.82 years (range 20-43 years). Eight eyes (16%) were treated with spheric ICL and 42 eyes (84%) were treated with toric ICL.

Table 1: Preoperative information of the study population underwent ICL implantation. SD: standard deviation.

	Anterior chamber depth (mm)	White to white diameter (mm) (IOL Master)	Central corneal thickness (µm) (Pentacam)	K-reading (Diopter) (Pentacam)
Mean ± SD	3.25 ± 0.22	11.89 ± 0.31	525.90 ± 37.19	44.10 ± 1.17
Maximum	3.72	12.50	586	46.30
Minimum	2.84	11.50	450	40.95

Table 2: Preoperative and postoperative clinical data comparison in patients who underwent ICL implantation.

	Preoperative			Postoperative			p Value
	Mean ± SD	Range		Mean ± SD	Range		
Spherical Equivalent (Diopter)	-10.35 ± 3.52	-4.00	-22.50	-0.41 ± 0.86	+0.50	-3.75	0.000
Sphere (Diopter)	-9.32 ± 3.24	-3.25	-21.00	-0.24 ± 0.84	+0.50	-3.75	0.000
Cylinder (Diopter)	-2.08 ± 1.31	0.00	-5.25	-0.42 ± 0.62	0.00	-2.50	0.000
LogMAR BCVA	0.07 ± 0.13	0.60	0.00	0.01 ± 0.04	0.20	-0.04	0.000
IOP (mmHg)	14.18 ± 1.94	18	10	15.13 ± 5.57	50	10	0.499

Abbreviation: SD: standard deviation; LogMAR: logarithm of the minimal angle of resolution; BCVA: best corrected distance visual acuity; IOP: intraocular pressure.

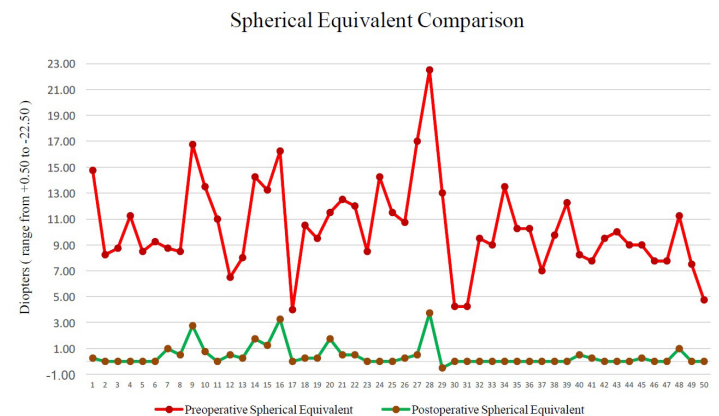


Figure 1: Comparison between preoperative and postoperative spherical equivalent.

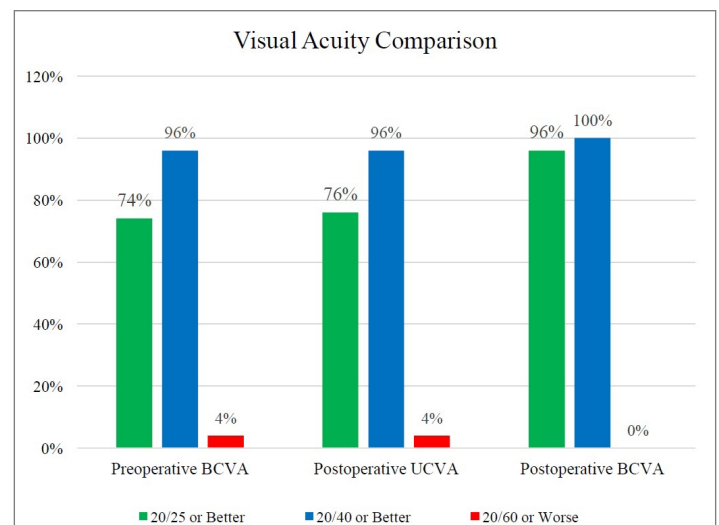


Figure 2: Comparison between preoperative and postoperative visual acuity.

Discussion

The results showed a remarkable improvement in visual acuity and refraction clinically and statistically (P < 0.001). The efficacy of

the ICL implantation has been demonstrated in previous studies. Similarly, Al Sabaani et al. reported a spherical equivalent within $\pm 0.50D$ in 69.8% of the total of 69 eyes and $\pm 1.00D$ in 84.1% of the eyes. The mean improvement of BCVA was 1 line. They concluded that ICL implantation procedure provides good visual and refractive results for myopia correction [5]. Also, Parkhurst et al. reported good results of ICL implantation, the mean postoperative spherical equivalent refraction achieved $-0.19 \pm 0.31D$ [6]. Another study reported the effectiveness of ICL in 82 eyes. The mean postoperative manifest spherical equivalent refraction was $-1.85 \pm 0.72D$, with 96.34% of eyes gaining 1 line of BCVA after 3 months of follow up [1]. The present study showed mean spherical refraction preoperatively $-10.35 \pm 3.52D$ range from -22.00 to $-4.00D$, and postoperatively equal to $-0.41 \pm 0.86D$ range from -3.75 to $+0.50D$ with BCVA of 0.01 ± 0.04 logMAR. The outcome of $-3.75D$ spherical equivalent refraction was found in one eye which was as expected refraction preoperatively related to ICL power available for high preoperative refraction. The preoperative BCVA was 6/9.5 which improved after surgery to 6/6. Then, the resultant refraction for this case was treated with Photorefractive keratectomy (PRK) which was explained to the patient before the surgery.

In comparison of preoperative and postoperative IOP, there was no statistical significance. The mean postoperative IOP was 15.13 ± 5.57 (range 10 – 50 mmHg), after excluding the complicated case, the postoperative IOP range from 10 – 19 mmHg. Slightly elevation of IOP was found in most cases one day after surgery that did not required treatment. The elevation was secondary to the residual viscoelastic substance used during the surgery to facilitate ICL positioning. This rise was in some cases managed with topical medications [7].

In term of postoperative complications, two cases were reported in this study. One case had elevation of IOP (50 mmHg) two months after surgery required ICL removal and PI to reduce IOP. This case was suspected to have glaucoma preoperatively and managed by glaucoma medications. After ICL removal and continuous follow up, patient was diagnosed with juvenile glaucoma. Similarly, a study reported postoperative increased IOP one day after surgery that required pressure lowering medication. They reported two eyes required ICL removal to control IOP. The IOP was controlled and remained within normal limits in all eyes after secondary intervention [5]. Also, another study found elevation of IOP up to 30 mmHg in 7 eyes shortly after surgery, which became normal after topical treatment in three to four days with no surgical intervention. They found that there was no vision threatening complication occurred throughout the follow up period [1].

The second case had ICL rotation of 15-20 degrees diagnosed two weeks after surgery following a change of her early postoperative vision. This rotation thought to be due to extensive exercise or eye rubbing after surgery. This case also has slightly high ICL

vault which could be due to oversizing of either white to white diameter or ICL diameter. ICL rotation was also reported in other studies, Al Sabaani et al. reported a case which had off axis toric ICL implantation that required ICL reposition. Also, they reported 3 cases of ICL decentration which was correctable with spectacles in 2 eyes and required repositioning of ICL in 1 eye [5].

Cataract formation is a potential complication in ICL implantation procedure. Al Sabaani et al. reported 3 eyes with anterior subcapsular cataracts, two of them had low vault [5]. Moreover, Gonvers et al. found that the rate anterior subcapsular cataract increased with the duration of follow up [8]. The present study did not report any cataract formation.

There are some limitations in the present study, the small study population and the short follow-up period in some cases secondary to the tight time allowed to complete the principal investigator's project.

This study showed that the ICL implantation is an effective and safe procedure as 96% of the patients achieved postoperative UCVA 20/40 or better, and 96% achieved BCVA 20/25 or better, the remaining 4% are having element of amblyopia, while 100% achieved BCVA 20/40 or better.

Further studies with larger population and long-term follow-up period needed for further assessment of the long term ICL visual outcome and ways to improve it.

References

1. Ju Y, Gao XW, Ren B. Posterior chamber phakic intraocular lens implantation for high myopia. *International Journal of Ophthalmology*. 2013; 6: 831-835.
2. Chaudhry IA, El Danasoury AM. Phakic intraocular lenses. *Saudi Journal Ophthalmology*. 2013; 27: 231-233.
3. <http://www.kellogg.umich.edu>.
4. Alió JL, Perez-Santonja JJ. *Refractive Surgery with Phakic IOLs Fundamentals and Clinical Practice*. illustrated ed. New Delhi: JP Medical Ltd. 2012.
5. Al Sabaani N, Al Assiri A, Al Torbak A, et al. Outcome of posterior chamber phakic intraocular lens procedure to correct myopia. *Saudi Journal of Ophthalmology*. 2013; 27: 259-266.
6. Parkhurst MGD, Psolka LM, Kezirian GM. Phakic Intraocular Lens Implantation in United States Military Warfighters: A Retrospective Analysis of Early Clinical Outcomes of the Visian ICL. *Journal of Refractive Surgery*. 2011; 27: 473- 481.
7. Azar DT, Melki S A. *101 Pearls in Refractive, Cataract, and Corneal Surgery*. 2nd Edition ed. Chicago: SLACK Incorporated. 2006.
8. Gonvers M, Bornet C, Othenin-Girard P. Implantable contact lens for moderate to high myopia. *Journal of Cataract and Refractive Surgery*. 2003; 29: 918-924.