

Assessing the Buccolingual Position and Angulation of Single Implants Restored in the Predoctoral Dentistry Program

Waad Kheder^{1*} and Prof. Hasan Alkumru²

¹Prosthodontist and Lecturer, Department of Preventive and Restorative Dentistry, College of Dental Medicine, University of Sharjah, UAE.

²Associate Professor, Department of Prosthodontics, University of Western Ontario, Schulich School of Medicine and Dentistry, Canada.

*Correspondence:

Waad Kheder B.D.S, Prosthodontist and Lecturer, Department of Preventive and Restorative Dentistry, College of Dental Medicine, University of Sharjah, Tel: +97165057378; Fax: +97165585641; E-mail: wkheder@sharjah.ac.ae.

Received: 21 October 2017; Accepted: 09 November 2017

Citation: Kheder W, Alkumru H. Assessing the Buccolingual Position and Angulation of Single Implants Restored in the Predoctoral Dentistry Program. Oral Health Dental Sci. 2017; 1(1); 1-7.

ABSTRACT

Objective: To assess if single implants restored in the undergraduate clinic at the Faculty of Dentistry, University of Toronto, are placed in a compromised buccolingual position and angulation relative to the adjacent natural teeth.

Materials and Methods: The study sample consists of 108 patients treated with single implants placed in the Implants Placement Unit and restored by predoctoral students at the Faculty of Dentistry, University of Toronto. Assessing the buccolingual angulation and position of implant relative to adjacent teeth were conducted by using the measurement tool in the three dimensions scanner.

Results: The results showed that 11.1 % of the implants included in the study were placed in a non-ideal buccolingual position (more lingually). The percentage of non-ideal buccolingual implant angulation was low.

Discussion: The challenges in placing the dental implant in an ideal buccolingual angulation were less than that to place the implants in an ideal buccolingual position. The placement of the implant in a non-ideal position/angulation may be due to: Gingival biotype, buccal cortical plate concavity and selected implant diameter.

Conclusion: Cone beam computed tomography might be considered as an aid, especially for comprised cases, in order to place implants in an ideal angulation and/or position.

Keywords

Angulation, Buccal, Implant, Lingual, Predoctoral.

Introduction

The placement of dental implants in a functionally and esthetically correct position and angulation is still considered a challenge in spite of major advances in surgical techniques and devices. Therefore, it is important to place the dental implants in a correct angulation and position in relation to each other, adjacent teeth, and to the underlying bone, since alveolar bone loss following tooth extraction often makes ideal implant placement difficult [1]. Furthermore, non-axial loading of implant-supported prostheses

may occur due to incorrectly positioned and non-parallel dental implants which may cause improper occlusal load distribution, overloading of the implant and ultimately failure of osseointegration [1,2]. The use of dental implant therapy in the treatment of dentate patients has become a well-established clinical procedure due to its predictability and success in practice [3,4]. The introduction of implant dentistry education greatly varies from one school to another. For example, at the University of Illinois-Chicago College of Dentistry, responsibilities of predoctoral dental students as part of a predoctoral implant program include: Identification of diagnostic criteria for implant placement, diagnostic wax-ups, fabrication of radiographic and surgical templates, and assisting

in surgery [5].

Implant osseointegration is not the only factor which affects the success of implant-supported restorations; the position and angulation of the implant may affect the success, esthetics and function of the restoration [6]. Adverse outcomes relating to an implant's position and angulation may affect the longevity and success of a prosthetic rehabilitation. A 3D scanner may be used to assess the angulation and position of the implant by scanning a stone model with implant replica and healing abutment [7].

Proper buccolingual implant position results in a proper emergence profile, simplifies the restorative procedure, and facilitates oral hygiene. At least 1 mm buccal wall thickness must be maintained to prevent gingival recession and improve esthetics. In general, placing the implant too far facially or lingually can create a number of complications at the prosthetic phase of treatment, because soft-tissue topography follows the underlying osseous contour dehiscence of the buccal cortical plate and gingival recession may occur as a result of placing the implant too far buccally [8,9].

The implant should be placed in such a way which makes the crown emerges from the soft tissue scaffold and creates the illusion of a natural tooth. To accomplish this, the implant centerline must regularly be located at or near the center of the replaced tooth; in some situations, this requires placing the implant in a more palatal position (e.g., implant site with a thin gingival biotype). On the other hand, it is preferable to place the implant slightly labially to harmonize with the occlusion of the opposing teeth, mainly in cases involving excessive vertical overlap [8]. Accordingly, evaluation of gingival biotype and type of occlusion at the area of implant placement is necessary before planning the position of implant placement.

The palatal danger zone is located about 1.5-2 mm from the imaginary line drawn between the emergence of the implant adjacent teeth and/or planned restoration. The labial danger zone is located anywhere facially to that imaginary line (Figure 1) [10].

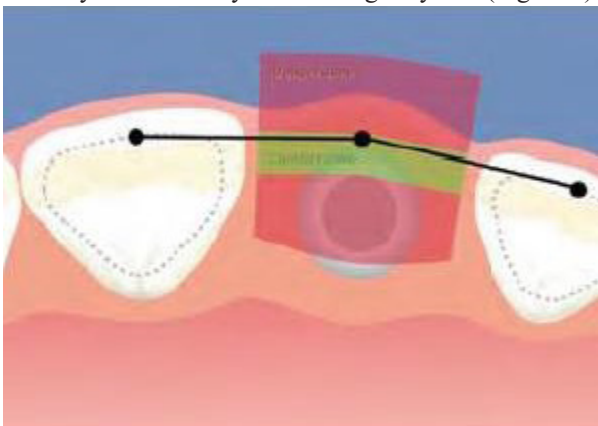


Figure 1: Ideal implant position in the buccolingual dimension [10].

Materials and Methods

The study commenced after obtaining approval for scientific

merit from the Research Committee at the Faculty of Dentistry, University of Toronto. The study sample consisted of 128 maxillary and mandibular stone models for patients treated with anterior and/or posterior single implants in the Implants Placement Unit (IPU) and restored by predoctoral students at the Faculty of Dentistry, University of Toronto. Only 108 models fitted the inclusion criteria for this study, and the 108 models included in the final appraisal. Any model with broken stone teeth adjacent to the implant or with defective stone at the area of the single implant were excluded from the study (Figure 2); in addition, stone models for patients with gingival recession of the teeth adjacent to the single implant were excluded from the study (Figure 3).




Figure 2: Defective tooth adjacent to the single implant.

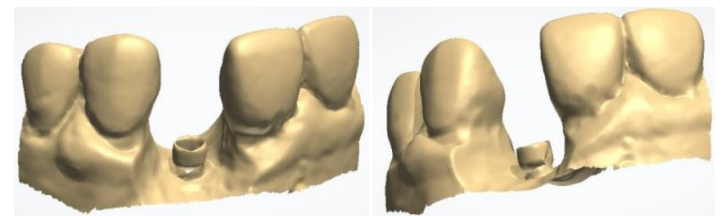


Figure 3: Gingival recession of the teeth adjacent to the single implant.

On the stone model, the location of the original implant was represented by an implant replica which was connected to a 10 mm high healing abutment. The healing abutment helped in the process of stone model scanning and measurements by using the measurement tools available in the 3Shape Dental Manager software of the scanner, to determine single implant buccolingual position in relation to adjacent teeth. The healing abutments has the same diameter of the implant as this helped to simulate the implant diameter at the level of adjacent teeth cemento-enamel junction where the distance between the implant and the adjacent tooth was measured.

Stone model scanning

A high resolution stationary scanner, a 3Shape D810 dental laboratory scanner (3Shape A/S, Copenhagen, Denmark), was used for scanning the stone models to identify the buccolingual position of the single implant in relation to adjacent natural teeth. A 10 mm high healing abutment was used to help in identifying the buccolingual position of single implant in relation to the adjacent teeth. A 3 mm diameter attachment screw was attached to the implant replica on the stone model to help in the scanning of the model and assessing the buccolingual implant angulation in relation to the adjacent teeth.

The 3Shape scanner provides three dimensional scanning of the stone models, as well as metal implant bars and full-arch bridges. This technology includes 5.0 MP cameras, adaptive impression

scanning, and texture-capture capabilities (3D Scanner manual) (Figures 4a & 4b).



Figures 4a & 4b: 3Shape D810 dental laboratory scanner (3Shape A/S, Copenhagen, Denmark).

Implant position assessment technique

All measurements for assessing the buccolingual implant position for anterior and posterior single implant in relation to the adjacent teeth were conducted by using the measurement tools available in the 3Shape Dental Manager Software of the 3D scanner. The measurements depended on the lines which were drawn in relation to the implant and the anatomical landmarks of adjacent teeth. During stone model scanning, a 10 mm high healing abutment was attached to the implant replica, representing the occlusal extension of the implant to help in assessing buccolingual single implant position.

Buccolingual implant position assessment

Two lines were drawn to be used as reference points to determine the buccolingual position of the single implant in relation to mesial and distal adjacent teeth. The first line is represented by the facial curvature of the arch at the level of the gingival margin (Figures 5 & 6). The second line connects the lingual sides of the adjacent teeth at the level of the gingival margin (Figures 7 & 8). These lines were drawn while looking at a right angle to the occlusal surface of the implant; if it was not at a right angle, this would affect the accuracy of the implant position assessment technique (Figure 9).




Figure 5: Buccal sides of teeth adjacent to the implant as reference points, tooth # 11.




Figure 6: Buccal sides of teeth adjacent to the implant as reference points, tooth # 36.

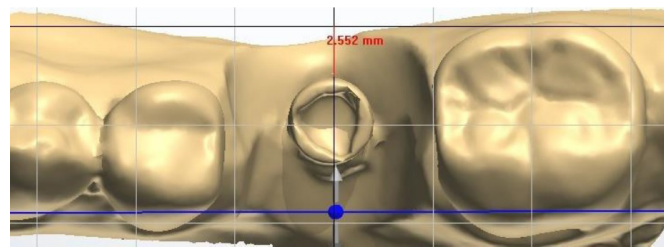


Figure 7: Lingual sides of teeth adjacent to the implant as reference points, tooth # 36.




Figure 8: Lingual sides of teeth adjacent to the implant as reference points, tooth # 11.

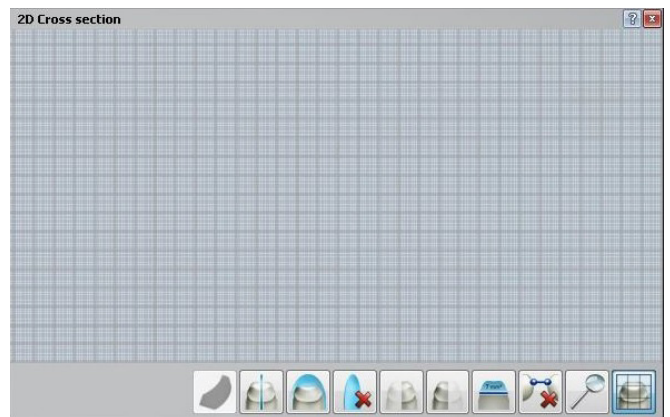


Figure 9A: 2D cross section graph image.

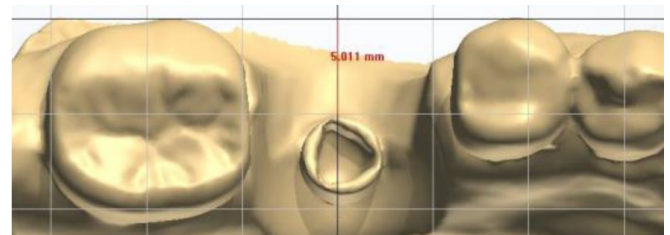


Figure 9: Looking at anon-right angle to the occlusal surface of the implant # 36.

To place the implant in an ideal buccolingual position in relation to the adjacent teeth, the implant should be located between the two reference lines representing the buccal and lingual sides of the adjacent teeth at the gingival margin level, and the distance from the facial surface of implant platform to the buccal reference line is 1.5 mm [9,10]. The first non-ideal buccolingual implant position is when its platform is located less than 1.5 mm from the buccal reference line. The second non-ideal buccolingual implant position is when its platform is located partially or completely lingual to the lingual reference line.

For posterior teeth, when the implant was located too far lingually, the lingual reference line was represented by a line that was in contact with the comparable adjacent tooth (at the level of gingival margin) and parallel to the 2D section line which was in contact with the buccal surface of the implant adjacent teeth (Figure 10).

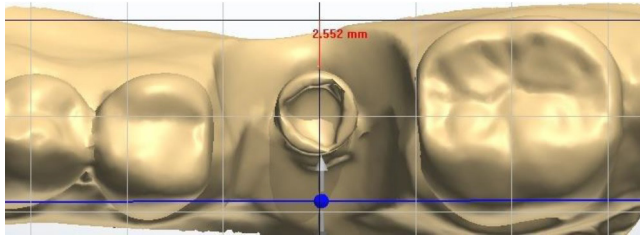


Figure 10: Lingual sides of teeth adjacent to the implant as reference points, tooth # 36.

Implant angulation assessment technique

Implants should be placed in angulation to make the implant abutment resemble the preparation of a natural tooth. Poor implant angulation (too much toward the palatal or the buccal side) can alter screw placement, and often compromise esthetics and impact home care. When the implant is placed in an ideal angulation parallel to the adjacent tooth, the access hole for the abutment screw ideally is supposed to be located at the mid-point of the buccolingual distance of the implant supported crown.

There was no “standard reference point” to be used as a reference for the measurement of the angle between the implant and the adjacent tooth, and no “specific or standard angle” that may be consider as an ideal angle (ideal angulation) between the implant and the adjacent tooth. In addition, there was no information in patient’s record to confirm if the surgeon placed the implant in relation to the angulation of the mesial or distal adjacent tooth. So it was not reliable or practical to assess the angulation of the implant based on measuring the angle between the implant and the adjacent tooth. Accordingly, the assessment of implant angulation in relation to the mesial and/ or distal adjacent tooth was based on the distance from line in contact with the buccal or lingual surface of the adjacent tooth, at the occlusal or incisal level, to the buccal or lingual surface of the attachment screw that is representing the abutment screw of the implant supported restoration.

This technique of measurement helped to determine the percentage of the implants in a non-ideal buccolingual angulation when there is less than 1 mm (minimum thickness of the porcelain for implant supported restoration) between the implant and the buccal and/ or lingual adjacent tooth at the level of the incisal edge for the anterior teeth and the marginal ridge for the posterior teeth.

All measurements for buccolingual implant angulation, for anterior and posterior single implants in relation to the adjacent teeth, were conducted by using the measurement tool available in the 3Shape Dental Manager Software of the 3D scanner. The abutment screw that connects the implant to the crown restoration was represented on the stone model by a 3 mm diameter attachment screw which was attached to the implant replica, and this helped in assessing the

buccolingual single implant angulation in relation to the adjacent teeth.

Buccolingual implant angulation assessment Posterior implant

The buccolingual angulation of the single posterior implant was assessed depending on the relation of the attachment screw to the buccal reference line which connects the buccal height of contour of the teeth adjacent to the implant (Figures 11a & 11b). One mm is the minimum distance required between the facial surface of the attachment screw and the line connecting the buccal height of the contour of the implant adjacent teeth; this line was drawn while looking at a right angle to the occlusal surface of the implant [11].

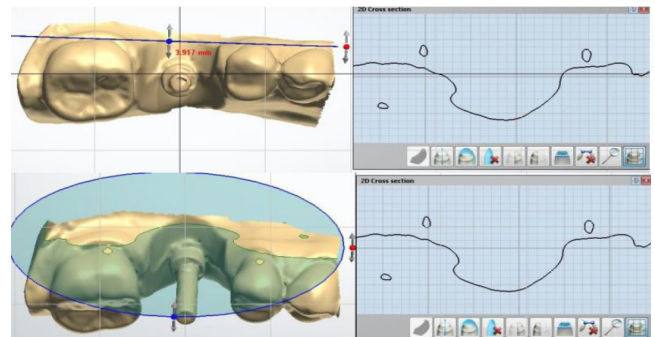


Figure 11a & 11b: Buccolingual implant angulation-buccal height of contour as a reference point (tooth # 36).

When the implant was located too far lingually, the angulation of the implant was assessed depending on the distance from the lingual surface of the attachment screw to the lingual reference line that was in contact with the comparable adjacent tooth at the lingual height of contour level, and parallel to the “graphic image line” that was in contact with the lingual surface of the attachment screw (e.g., if the implant replaced the mandibular first molar tooth, the comparable adjacent tooth would be the mandibular adjacent second molar) (Figures 12a & 12b).

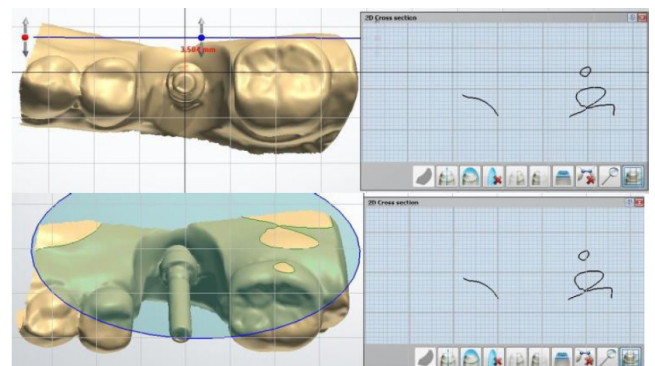


Figure 12a & 12b: Buccolingual implant angulation-lingual height of contour as a reference point (tooth # 36).

Accordingly, the ideal buccolingual implant angulation was when the distance 1 mm or more from the facial surface of the attachment screw to the buccal reference line or when it was 1 mm or more from the lingual surface of the attachment screw to the lingual reference line. The non-ideal buccolingual implant angulation was when the previously mentioned distances were less than 1 mm.

Anterior implant

A line was drawn to connect the buccal height of contour of the implant adjacent teeth (Figures 13a & 13b). This line was used as a reference point to determine the buccolingual implant angulation in relation to the adjacent teeth, and was drawn while looking at a right angle to the occlusal surface of the implant. The minimum distance required between the facial surface of the attachment screw and the line connecting the buccal height of contour of the implant adjacent teeth was 1mm as a clearance for the porcelain of the implant supported crown [12]. Accordingly, the buccolingual implant angulation was considered ideal when the distance from the facial surface of the attachment screw to the line connecting the buccal height of contour of the implant adjacent teeth was 1 mm or more and non-ideal buccolingual implant angulation when that distance was less than 1 mm.

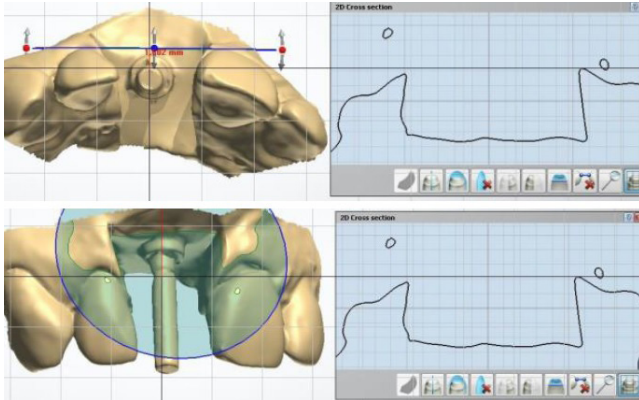
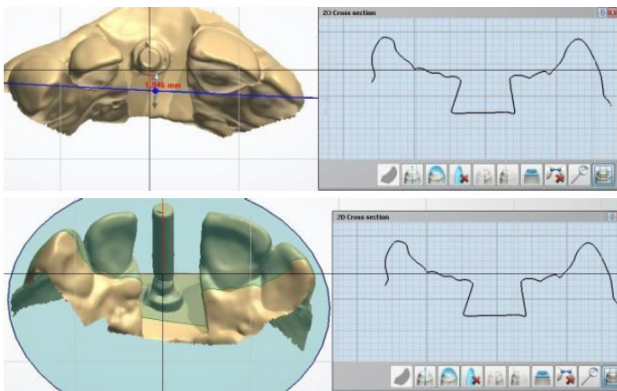


Figure 13a and 13b: Buccolingual implant angulation-buccal height of contour as a reference point (tooth # 11).

When the implant was located too far lingually in relation to the adjacent anterior teeth, the implant was in an ideal buccolingual angulation when the distance from the lingual surface of the attachment screw to the reference line that was in contact with the cingula of the implant adjacent teeth was 1 mm or more, and non-ideal when the distance was less than 1 mm (Figures 14a & 14b).



Figures 14a and 14b: Buccolingual implant angulation-implant adjacent teeth cingula as a reference point (tooth # 11).

Statistical Analyses

Statistical analysis was performed by using SPSS software to conduct a descriptive analysis of the data collected after stone models scanning. SPSS software was used to find Median, Mean,

Standard deviation and Range for the buccolingual implants position/angulation from the mesial and distal sides separately.

Results

The histogram (Figure 15) shows the percentages of the implants placed in a non-ideal buccolingual position; 32.3% of the implants included in this study were placed in a non-ideal buccolingual position, with 21.2 % were placed more buccally and 11.1 % were placed more lingually.

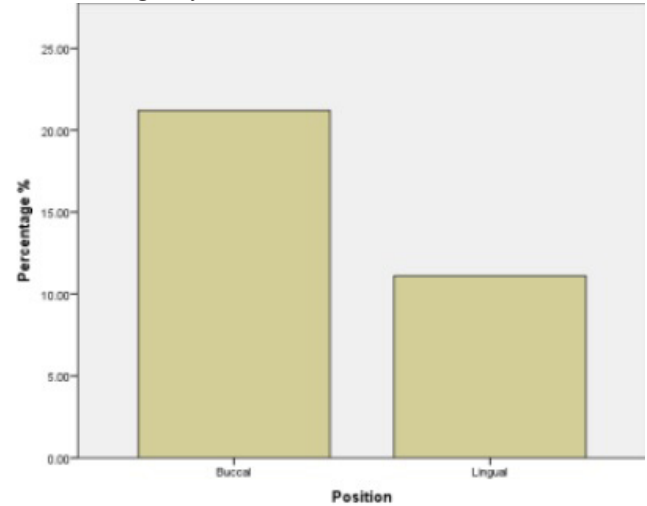


Figure 15: Buccolingual implant position histogram.

The histogram (Figure 16) shows the percentages of the implants placed in a non-ideal buccolingual angulation; 4.5 % of the implants included in the study were placed in a non-ideal buccolingual angulation, with 2.7 % were angulated more buccally and 1.8 % were angulated more lingually.

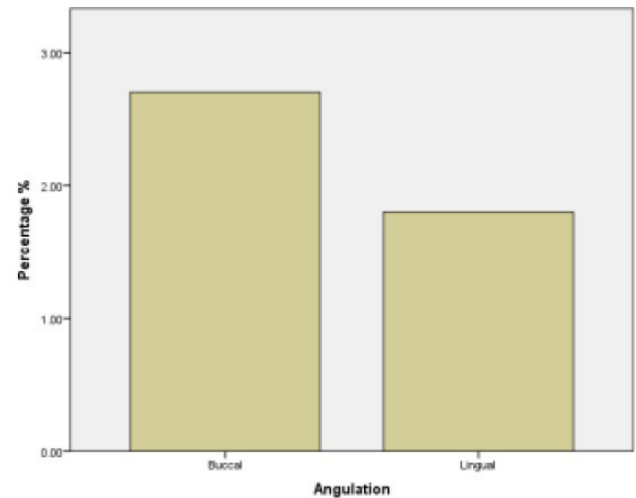


Figure 16: Buccolingual implant angulation histogram.

Discussion

This retrospective study assessed buccolingual position and angulation of the single implants restored by predoctoral students at the Faculty of Dentistry, University of Toronto, and determined the percentage of the implants placed in a non-ideal buccolingual angulation and position. The results showed that some of those

implants were placed in a non-ideal angulation and/or position. This study included implants that replaced teeth in different areas of the dental arches in different patients. Accordingly, the reason(s) for the non-ideal angulation and/or position may differ from one case to another and may be due to one or more of the following reasons:

Selected implant diameter

Failure to select the proper implant diameter to correspond with the available bone volume in the buccolingual dimensions is one of the reasons for a non-ideal implant placement in the buccolingual position. The non-ideal position of the implants included in this study may be due to the improper implant diameter selection; For instance, when the buccolingual distance at the area of a missing molar tooth is enough to place a wide platform implant, placing a narrow platform implant, due to inadequate buccolingual bone width, will increase the distance between the implant and the adjacent tooth (more than the maximum ideal distance/2mm) leading to non-ideal mesiodistal implant position.

In this study, based on the implant curriculum for predoctoral students, all patients treated by predoctoral students should have implant site with enough bone volume to place the implant in an ideal buccolingual position. However, the non-ideal deep apicocoronal implant position due to inadequate buccolingual distance had positive impact in the restoration of the implant because deep implant placement will help to provide proper emergence profile of the restoration. This is in agreement with Lops et al. who found that inadequate buccolingual bone distance at the area of implant site is an explanation for deep implant placement. In addition, Spray et al. found that the facial crest resorption was more pronounced when the facial bone thickness was decreased.

Gingival biotype

Gingival biotype affects the buccolingual position of the implants and it is related to severe gingival recession and presence/absence of interproximal papilla after implant placement [10]. A thin gingival biotype dictates placement of the implant in a slightly more palatal position to reduce the chance of recession and prevent the shadow of titanium from showing through the thin gingival tissue [8,12].

The results showed that 11.1 % of the implants included in the study were placed in a non-ideal buccolingual position (more lingually), Although the gingival biotype wasn't assessed clinically, thin gingival biotype might be one of the reasons for placing of implants included in the study in a more lingual; this approach to place the implant will help to avoid gingival recession and esthetic risk that will occur as a result of placing those implants in a more buccal position. In this study, the assessment of implants' positions and angulations performed by using the stone models, thus there was no opportunity for intraoral assessment of the soft tissue and gingival biotype. The finding of this study was in agreement with Si et al. [13], who found that a thin gingival biotype requires implant placement in a slightly more lingual position to reduce the chance of gingival recession and to prevent the shadow of the

titanium from showing through the thin gingival tissue.

Buccal cortical plate concavity

The presence of buccal plate concavity may cause non-ideal buccolingual implant angulation and/or position. The thickness of the buccal cortical plate varies throughout the mouth and traumatic tooth extractions can cause noticeable buccal concavities, thin plates, and overall alveolar ridge width deficiency [14].

A low percentage of the implants included in this study (2.7 %) were placed in a non-ideal buccolingual angulation (more buccally), and this suggests the presence of buccal plate concavity at the area of implant site. Regarding the non-ideal buccolingual implant position, 21.2 % of the implants were placed more buccally and 11.1 % were placed more lingually. This percentage is considered high as the implants included in this study were placed by using the surgical guide which was fabricated based on the tooth set up in relation to the opposing teeth. Thus, the implants were placed more buccally or more lingually to avoid perforation of the buccal cortical plates, which might occur due to the presence of buccal concavity at the implant site.

This finding regarding the buccolingual implant position and/or angulation is in agreement with Tinti et al. [15], who found that some clinicians might place the implant in a non-ideal buccolingual angulation and/or position to avoid fenestration or dehiscence implant defect that results from placing the implant in an ideal buccolingual position and/or angulation when there is buccal/lingual plate concavity.

Conclusion

The challenges in placing the dental implant in an ideal buccolingual angulation were less than that to place the implants in an ideal position. Cone beam CT might be considered as an aid, especially for comprised cases, in order to place implants in an ideal angulation and/or position. To confirm that thin gingival biotype at the implant site is the main reason behind placing some of the implants in a non-ideal buccolingual position a clinical assessment of the soft tissue at the implant site is required. In addition, this clinical assessment is necessary to find the effect of non-ideal implant placement on severe gingival recession and presence/absence of interproximal papilla.

References

1. Talwar N, Chand P, Singh B, et al. Evaluation of the efficacy of a prosthodontic stent in determining the position of dental implants. *J Prosthodont.* 2012; 21: 42-47.
2. Saab X, Griggs J, Powers J, et al. Effect of abutment angulation on the strain on the bone around an implant in the anterior maxilla: A finite element study. *J Prosthet Dent.* 2007; 97: 85-92.
3. Afsharzand Z, Lim M, Rashedi B, et al. Predoctoral implant dentistry curriculum survey: European dental schools. *Eur J Dent Educ.* 2005; 9: 37-45.
4. Petropoulos V, Arbree N, Tarnow D, et al. Teaching implant

-
- dentistry in the predoctoral curriculum: A report from the ADEA implant workshop's survey of Deans. *J Dent Educ.* 2006; 70: 580-588.
5. Lee D, Harlow R, Yuan J, et al. Three-year clinical outcomes of implant treatment provided at a predoctoral Implant Program. *Int J Prostho.* 2011; 24: 71-76.
 6. Park C, Raigrodski A, Rosen J, et al. Accuracy of implant placement using precision surgical guides with varying occluso-gingival heights: An in vitro study. *J Prosthet Dent.* 2009; 101: 372-381.
 7. Hollenbeck K, Allin T, Van der Poel M. Dental Lab 3D Scanners – How they work and what works best. 3Shape Technology Research. 2012.
 8. Al-Sabbagh M. Implants in the Esthetic Zone. *Dent Clin N Am.* 2006; 50: 391-407.
 9. Froum S. Prosthodontic complications related to non-optimal dental implant placement. *Dental Implant Complications.* 2010, Chapter 9. John Wiley & Sons Ltd, United Kingdom.
 10. Buser D, Belser C, Martin W. Optimizing Esthetics for Implant Restorations in the Anterior Maxilla: Anatomic and Surgical Considerations. *Int J Oral Maxillofac Implants.* 2004; 19: 43–61.
 11. Shillingburg HT. *Fundamentals of Fixed Prosthodontics.* 2012. Chapter 28 & 29. Quintessence Publishing Co. Inc. USA.
 12. Pagni G, Pellegrini G, Giannobile W, et al. Postextraction alveolar ridge preservation: biological basis and treatments. *International Journal of Dentistry.* 2012; 4: 1-13.
 13. Si M-S, Zhuang LF, Huang X, et al. Papillae alterations around single-implant restorations in the anterior maxillae: thick versus thin mucosa. *International Journal of Oral Science.* 2012; 4: 94-100.
 14. Katranji A, Misch K, Wang HL. Cortical bone thickness in dentate and edentulous human cadavers. *J Periodontol.* 2007; 78: 874-878.
 15. Tinti C, Parma-Benfenati S. Clinical classification of bone defects concerning the placement of dental implants. *Int J Periodontics Restorative Dent.* 2003; 23: 147-155.