

## How to Deal with Posterior Lenticonus – Two Different Approaches

Hévila Rolim<sup>1,2,\*</sup>, Ana Flávia Lacerda Belfort<sup>2</sup>, Marina Trigueiro<sup>3</sup> and Luis Felipe da Silva Alves Carneiro<sup>2</sup>

<sup>1</sup>Medicine College, Universidade Federal de Rondonia, Porto Velho, Brazil.

<sup>2</sup>Department of Ophthalmology, Santa Casa de Belo Horizonte, Belo Horizonte, Brazil.

<sup>3</sup>Medicine student – FIMCA Rondonia, Porto Velho, Brazil.

### \*Correspondence:

Hévila Rolim, MD, PhD, Depto de Medicina – UNIR Campus José Ribeiro Filho, Porto Velho, RO, Brazil, Tel: +55 (69) 98129-7511; E-mail: hevilarolim@unir.br.

**Received:** 27 December 2018; **Accepted:** 30 January 2018

**Citation:** Hévila Rolim, Ana Flávia Lacerda Belfort, Marina Trigueiro, et al. How to Deal with Posterior Lenticonus – Two Different Approaches. *Ophthalmol Res.* 2017; 1(7): 1-3.

### ABSTRACT

**Introduction:** Posterior lenticonus is a rare ectasia of the posterior capsule of the lens and has a prevalence of 1-4/100,000 and is associated with crystalline opacity in 14% of unilateral cases and 9% of bilateral cases. Depending on the degree of opacity and visual impairment, there is a risk of developing amblyopia but the effect on vision is extremely variable. We report two different treatment approaches to the disease.

**Case Report:** The first case is a 10 months male patient with Down syndrome attended for evaluation of cataract with good fixation and no strabismus. Initially a non surgical treatment was chosen but later he developed an aggressive behavior and a posterior lenticonus associated with posterior polar cataract was observed, which lead to the decision of a surgical treatment. The second case is a 7 years old patient with history of low visual acuity and posterior polar cataract in the left eye associated with posterior lenticonus discretely displaced superiorly. He was treated with tropicamide and occlusion of the right eye for thirty days.

**Discussion:** The two cases shows how is it possible to manage posterior lenticonus with surgical ou clinical treatments. There is a tendency for patients who underwent cataract surgery to have a better visual acuity improvement compared with patients who did not have surgery, however this data was not statistically significant.

**Conclusion:** The ophthalmologist should be able to recognise this finding during examn and decide wich treatment, surgical or clinical, will bring the best visual outcome for his pacients.

### Keywords

Cataract, Down syndrome, Posterior lenticonus, Surgery.

### Introduction

Posterior lenticonus is a rare ectasia of the posterior capsule of the lens and has a prevalence of 1-4 / 100,000 [1] and is associated with crystalline opacity in 14% of unilateral cases and 9% of bilateral cases [2]. Unlike the unilateral posterior lenticonus that is sporadic, bilateral cases are associated in 58% with a family history of early-onset cataract [2]. Russel-Egit suggests that an X-linked gene mutation, affecting primarily the posterior capsule, may be responsible for some cases of posterior lenticonus but an autosomal dominant inheritance with variable expression could occurs in some cases [2]. Posterior lenticonus is considered a rare manifestation of Alport syndrome [1], but it is not commonly described as a manifestation in Down syndrome.

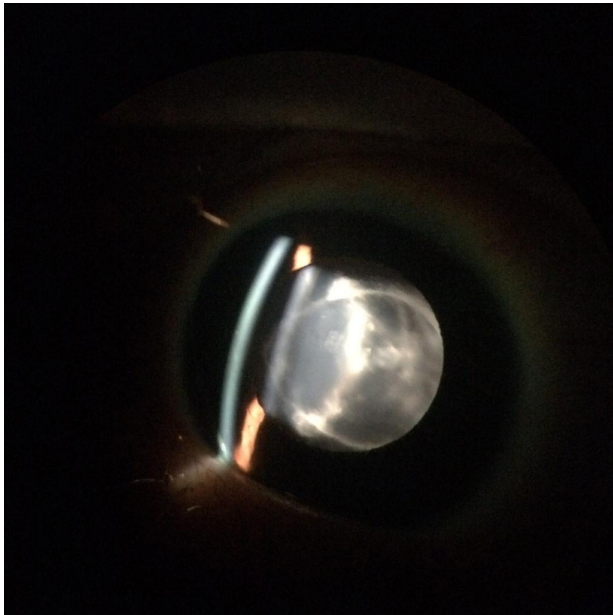
Depending on the degree of opacity and visual impairment, there is a risk of developing amblyopia but the effect on vision is extremely variable [3]. We report two different approaches that can be used to treat the disease, one surgical in a patient with Down syndrome and other clinical.

### Case Report

#### Case 1

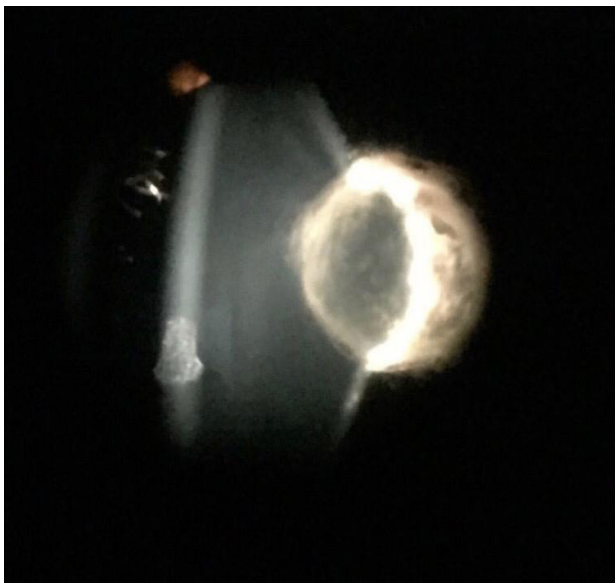A 10 months male patient with Down syndrome attended for evaluation of cataract with good fixation and no strabismus. At biomicroscopy he had transparent corneas, posterior polar cataract (+ 1/4 + right eye + 1-2 / 4 + left eye) with partially free visual axis and fundoscopy without alterations. After consultation with the strabismus department, conservative treatment was chosen. At 2 years old he was referred with aggressive behavior for surgical evaluation due to the irregularity of the band at retinoscopy in

the right eye and absence in the left eye, without strabismus. On examination it was noticed posterior lenticones with posterior polar opacity on both eyes (bigger on the left eye) (Figure 1), Intraocular pressure of 10mmHg on both eyes, corneal diameters of 11.75mm on both eyes and axial length of 23.48mm on the right eye and 23.98mm on the left eye. Phacoemulsification without intraocular lens implantation (IOL) was chosen, with bilateral pars plana vitrectomy. In the postoperative period, he evolved without complication with free visual axis, good fixation, without strabismus and with support for secondary implant. One year later, using corrective lenses (+ 11.00 both eyes), he presented with preserved ocular motility, good response to stimuli, and improved social interaction.



**Figure 1:** Posterior polar cataract associated with posterior lenticonus.

## Case 2



**Figure 2:** Posterior polar cataract associated with posterior lenticonus

discretely displaced superiorly.

Patient of 7 years with history of low visual acuity. The exam presented visual acuity without correction of 20/20 in the right eye and 20/70 in the left eye. Post-cycloplegia visual acuity of 20/20 in the right eye and 20/50 in the left eye. The biomicroscopy presented transparent corneas, posterior polar cataract in the left eye associated with posterior lenticonus discretely displaced superiorly (Figure 2). Fundoscopy without alterations. Due to the patient's age and visual acuity, conservative treatment with 1% tropicamide once daily associated with occlusion of the right eye for 30 days was chosen.

## Discussion

The first report addresses the case of a child with Down syndrome, posterior lenticones associated with bilateral posterior polar cataract, without the presence of strabismus, initially treated conservatively and, with worsening of the condition, surgically. The treatment of choice was surgical without IOL implantation due to left eye lenticones size, bilaterality and Down's Syndrome. The second case shows a seven year old patient in which the clinical treatment with tropicamide and occlusion was chosen.

Travi et al. reported a tendency for patients who underwent cataract surgery to have a better mean BCVA after surgery and a better BCVA improvement compared with patients who did not have surgery [4], however it was not statistically significant. They reported a success rate of approximately 67% in treating this amblyopia without surgery [4].

Both patients had posterior polar cataract associated with posterior lenticonus. Nagatomo et al. found that posterior lenticonus was more often seen in eyes with posterior subcapsular/ polar cataract than those with other cataract morphology [5]. Posterior lenticonus is more common than anterior lenticonus and is usually unilateral and sporadic. It has been described as associated with Lowe's syndrome and Alport syndrome [6] but not with Down syndrome as our first case. Crouch recommended cataract surgery if vision of 20/100 or worse in unilateral cataract associated with posterior lenticonus as an attempt to rehabilitate the involved eye [7]. Our second patient had a vision of 20/50 after cycloplegia, which could indicate that the clinical treatment with tropicamide and occlusion might have a satisfactory result.

## Conclusion

Posterior lenticones are not uncommon and the ophthalmologist should be prepared to recognize the disease and investigate systemic and ocular associated findings. According to visual acuity and the age of the patient the doctor must be able to choose between clinical and surgical treatments in order to avoid amblyopia.

## References

1. Al-Mahmood AM, Al-Swailem SA, Al-Khalaf A, et al. Progressive Posterior Lenticonus in a Patient with Alport

- 
- Syndrome. Middle East African Journal of Ophthalmology. 2010; 17: 379-381.
2. Russell-Eggitt IM. Non-syndromic posterior lenticonus a cause of childhood cataract: evidence for X-linked inheritance. Eye (Lond). 2000; 14: 861-863.
  3. Schipper, Isaak et al. Diagnosis and management of bilateral posterior lenticonus in 7 members of the same family, Journal of Cataract & Refractive Surgery 2006; 32: 261 -263.
  4. Travi GM, Schnall BM, Lehman SS, et al. Visual outcome and success of amblyopia treatment in unilateral small posterior lens opacities and lenticonus initially treated nonsurgically. J AAPOS. 2005; 9: 449-454.
  5. Nagamoto T, Oshika T, Fujikado T, et al. Clinical characteristics of congenital and developmental cataract undergoing surgical treatment. Jpn J Ophthalmol. 2015; 59: 148-156.
  6. Bamotra RK, Meenakshi, Kesarwani PC, et al. Simultaneous Bilateral Anterior and Posterior Lenticonus in Alport Syndrome. J Clin Diagn Res. 2017; 11: ND01-ND02.
  7. Crouch ER, Parks MM. Management of posterior lenticonus complicated by unilateral cataract. Am J Ophthalmol. 1978; 85: 503-508.