

Should Empyema Space Be Surgically Closed?: A Case Report of Pleural Irrigation with Electrolyzed Saline for Postoperative Empyema

Kembu Nakamoto*, Kazuya Yoshida, Motohiro Takeshige, Toshiyuki Fujii, Hiroshi Hashiyada and Hiroshi Maruta

Division of General Thoracic Surgery, Department of Surgery, Shunan Memorial Hospital, 1-10-1, Ikunoya-minami, Kudamatsu, Yamaguchi, 730-0043 Japan.

*Correspondence:

Nakamoto K, Division of General Thoracic Surgery, Shunan Memorial Hospital, Kudamatsu, Yamaguchi, Japan, Tel: +0833-45-3330; Fax: +0833-45-3331; E-mail: nakamoto@hcsdojinkai.or.jp.

Received: 17 March 2018; Accepted: 22 April 2018

Citation: Kembu Nakamoto, Kazuya Yoshida, Motohiro Takeshige, et al. Should Empyema Space Be Surgically Closed?: A Case Report of Pleural Irrigation with Electrolyzed Saline for Postoperative Empyema. *Microbiol Infect Dis*. 2018; 2(2): 1-3.

ABSTRACT

Introduction: Acute empyema without bronchofistulae is now a well controllable disease by intrapleural irrigation with electrolyzed saline (ES), current ultimate disinfectant for biological tissues. ES irrigation was applied to postoperative empyema of esophagectomy, resulting hospital discharge without any surgical options.

A 67 year old male with esophageal cancer had acute empyema in the right side, caused by anastomotic leaks, on postoperative day 7 after esophagectomy with neck lymphnode dissection reconstructed with gastric conduit through retrosternal route. He had catheter drainage with 2000 ml/day of ES irrigation for 20 days immediately after diagnosis of empyema. Pathogens were promptly eliminated, and empyema space was spontaneously closed. He had second empyema caused by gastric conduit rupture at the stapled line after 38 days of the cure in the first empyema. The patient had second ES irrigation under catheter indwell, and recovered for three weeks according to the spontaneous closure of the conduit leaks, and finally discharged our hospital after dilation of anastomotic stricture and swallowing rehabilitation.

Conclusions: ES irrigation promptly controlled postoperative empyema of esophagectomy without surgical options for residual deadspace.

Keywords

Electrolyzed saline, Postoperative empyema, Esophagectomy.

approval for this study (IRB #2602, SMH, March 24, 2015).

Patient consent was obtained.

Introduction

Postoperative empyema is a major complication of esophageal resection, requiring emergency surgery in high risk cardiopulmonary states [1,2]. Custom made electrolyzed saline (ES) with an electrolysis generator (Oxilyzer Medical C-L, Koken Ltd., Tokyo) using a 0.1% salt and tap water mixture is a current ultimate disinfectant for biological tissues [3], and its use for less invasive irrigation promptly cured empyema [4]. We performed ES irrigation for postoperative empyema from esophagectomy, and herein report the treatment strategies used in this case.

A 63-year-old male with mediastinal esophageal cancer (squamous cell carcinoma, stage IIIA after induction chemotherapy), had subtotal esophagectomy with radical neck lymph node dissection, which was reconstructed by gastric conduit through the retrosternal approach on September 14, 2016 (Figure 1). He had mechanical ventilator support for postoperative respiratory insufficiency. During respiratory support, he developed cervical anastomotic leaks on postoperative day (POD) 3, which progressed to acute empyema on POD 7 in the right lower posterior pleural cavity. A double lumen silicon catheter (Fr18 Phicon Samp Catheter, Fuji Systems Co., Fukushima) was manually indwelled under echo guidance through the primary chest drainage port for ES irrigation at a rate of 2000ml/day under 15-cm H₂O suction pressure at the

Case Presentation

The Institutional Review Board of our hospital granted ethics

bed side. The drained effusions promptly cleared with elimination of microbes and septic symptoms withdrew within a few days. The indwelled catheter was removed after the closure of the anastomotic leaks. He had second empyema caused by conduit rupture at the stapled line on POD 52. A catheter was indwelled through the anterior chest wall under fluorescence. Intrapleural ES irrigation for drainage of massive fibrin debris was resumed at an initial rate of 3000ml/day for a few days, and then reduced to 2000ml/day with 15-cm H₂O suction pressure after the drained effusion cleared with immediate withdrawal of septic conditions. He had intermittent positive expiratory pressure load (PEEP) by breath training equipment (Soufful® Kayaku Co, Ltd, Saitama) for facilitation of lung re-expansion to close the empyema space during ES irrigation. The indwelled catheter was finally removed after 23 days according to the spontaneous reduction in the dead space and closure of the conduit leaks (Figure 2). The patient commenced oral intake after dilation of the anastomotic stricture. He was discharged to his home on POD 165 and has been healthy for more than one year.

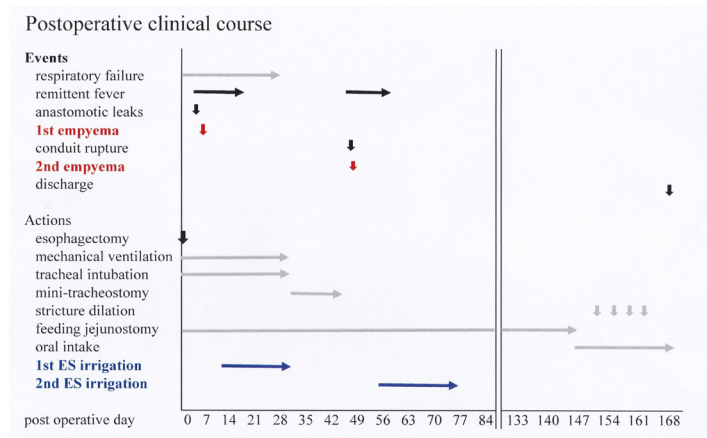


Figure 1: Diagram of the postoperative clinical course. ES: electrolyzed saline.

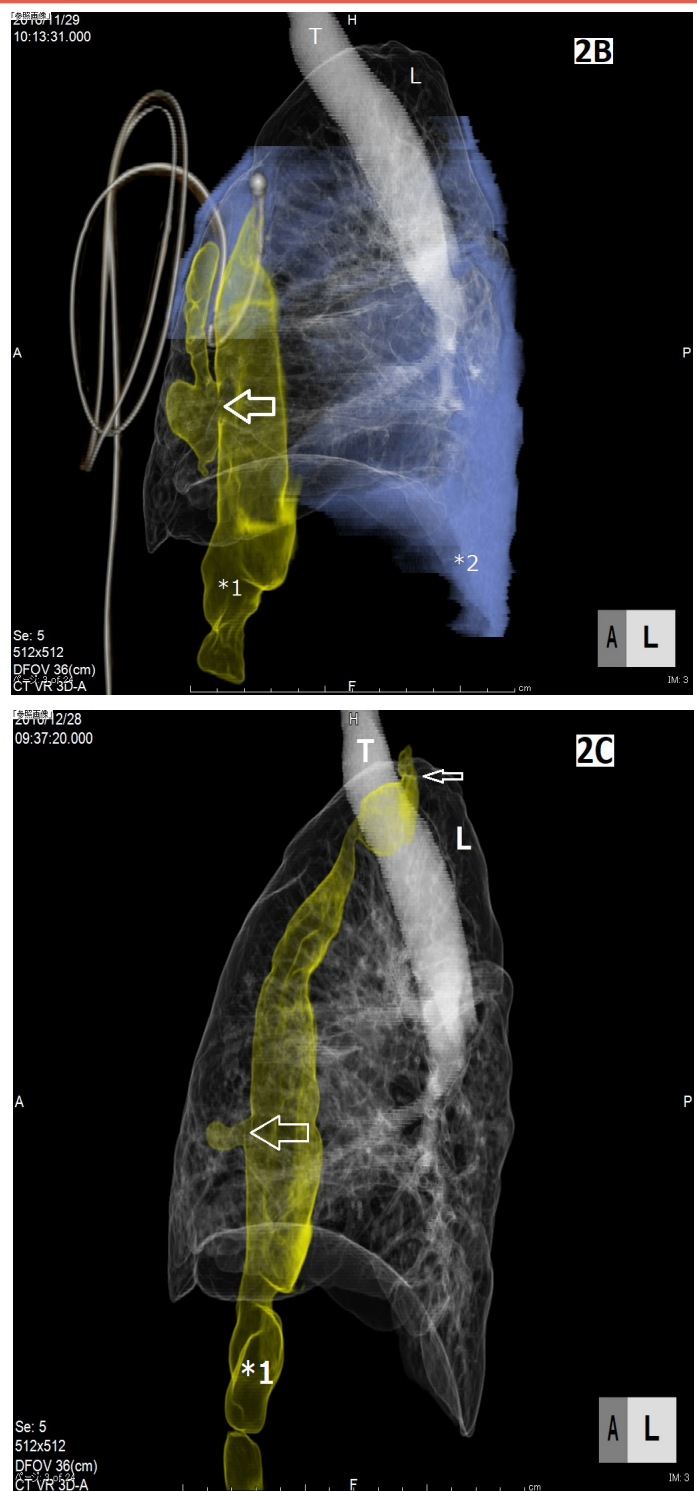


Figure 2: Three-dimensional images of the empyema space in the second episode. (Medial-lateral view) A: Before irrigation in the second episode; connection of the ruptured gastric conduit (yellow) to the empyema space (purple). The empyema/lung volume ratio was 581ml/704ml. B: Catheter irrigation; catheter tip was placed close to the conduit rupture and empyema space was promptly reduced. The empyema/lung volume ratio was 245ml/1213ml. C: A month after irrigation; former empyema space from both episodes completely disappeared with closure of the leaks and lung re-expansion. The empyema/lung volume ratio was 0ml/1644ml. The affected lung volume recovered to 82% of the preoperative volume.

*1: Gastric conduit, *2: Empyema space, Thick arrow: Ruptured site of stapled line, Thin arrow: Anastomotic stricture, L: Lung, mT: Mini-tracheostomy, T: Trachea.

Comments

Postoperative empyema from esophagectomy is a life-threatening major complication, which sometimes required emergency invasive surgery under high risk cardio-pulmonary conditions [1, 2]. The results of surgery are frequently poor with a high morbidity and mortality rate [2].

We have demonstrated that intrapleural irrigation with ES solution was an effective and less invasive strategy for parapneumonic empyema without bronchofistula [3]. ES solution has broad spectrum bactericidal activity, including for viruses and fungi, is superior to povidone iodine, and has no adverse effects on biological tissues because of immediate conversion to water after contact with organisms [3,5]. Prompt ES irrigation reduced the use of parenteral antibiotics [4].

Principal treatment for empyema is cleansing and closure of the infected pleural dead space [1]. ES irrigation promptly eliminated bacterial colonies in the empyema space and facilitated epithelization of the pleura under closed space drainage [3]. Organic or protein substances deactivated the bactericidal activities of ES solution, continuous irrigation was frequently required for the maintenance of the activity level [2] and the disruption of the microbe biofilms [5]. Persistent germ-free conditions were maintained in the closed space once pleural disinfection and epithelization was achieved. The cause of persistent bacterial colonization was residual empyema pockets, and that of disease relapse after ES irrigation was residual pathogens in fibrin sludge of the drainage port closed on catheter removal [4]. The residual sludge in the port was flashed out by Valalva maneuvers on catheter removal, and the port wound was left open with or without coverage by a sealing film after cleaning with ES solution. Complete elimination of bacterial

colonies with pleural epithelization allowed residual dead space to close spontaneously. Empyema with stiff organized pleura was also closed by facilitation of lung re-expansion under the support of the intermittent PEEP procedure. Surgical options for dead space closure, such as decortication or muscle flap packing, were unnecessary.

The medical cost for long term usage of custom made ES solution is inexpensive [3]. ES production is simple with an electrolysis generator without sterilization [3], and ES solution was listed in the 2008 CDC guidelines [3] as a novel disinfectant. ES solution has resolved postoperative empyema, a major complication of esophagectomy.

Acknowledgement

We thank Takashi Yamanaka, Ph.C., Kazuo Nagano, MT. and Yuya Nakamura, RT. for help with ES preparation, microbiological examinations and 3D image preparations.

References

1. Postlethwait RW. Replacement of the esophagus with the stomach. Ed by TW Shields General Thoracic Surgery. 2nd edn. 1983; 363-366.
2. Crestanello JA, Deschamp C, Cassivi SD, et al. Selective management of intrathoracic anastomotic leak after esophagectomy. J Thorac Cardiovasc Surg. 2005; 129: 254-260.
3. Nakamoto K, Takeshige M, Fujii T, et al. Electrolyzed saline irrigation for elimination of bacterial colonization in the empyema space. Surg Infect. 2016; 17: 724-729.
4. Nakamoto K, Yoshida K, Takeshige M, et al. Intrapleural irrigation with electrolyzed saline for acute empyema. Int J Cur Med Pharm Res. 2017; 3: 2440-2445.
5. Jaju S, Jaju PP. Newer root canal irrigants in horizon: a review. Int J Dentist. 2011; 9.