

A Rare Case of Klippel Trenaunay Syndrome in Pregnancy

Zara Arain, Mansi Tiwari*, Ali Nakhosteen, Ade Adeyemo, Abha Govind, Reeta Subba, Suchana Dhital and Beena Subba

Department of Obstetrics and Gynaecology, North Middlesex Hospital, London, UK.

*Correspondence:

Mansi Tiwari, Department of Obstetrics and Gynaecology, North Middlesex Hospital, London, UK, E-mail: drmansitiwari@gmail.com.

Received: 19 November 2018; Accepted: 11 December 2018

Citation: Zara Arain, Mansi Tiwari, Ali Nakhosteen, et al. The A Rare Case of Klippel Trenaunay Syndrome in Pregnancy. Food Sci Nutr Res. 2018; 1(1): 1-3.

ABSTRACT

Objective: This case study aims to review the management of pregnancy in a patient with Klippel Trenaunay syndrome (KTS), a rare condition characterised by venous malformations, affecting an estimated 1 in 30,000-100,000 live births (1). We focused on tailoring management to adverse outcomes specifically associated with this condition; including venous thromboembolism and postpartum haemorrhage.

Design: We followed the case of a 35 year old primip who had been identified as needing specialist input for KTS at 35 weeks pregnant. Obstetric management was based largely upon current literature as there are no specific guidelines for the management of this condition in pregnancy.

Methods: Recent literature was reviewed at the point of referral to antenatal clinic. Primary risks were identified including venous thromboembolism, post-partum haemorrhage, complicated administration of loco- regional anaesthesia and difficult delivery by caesarean section. In view of these risks, the patient was initiated on low molecular weight heparin, an MRI spine and pelvis was organised and a plan was made for induction at 38 weeks. Blood was crossmatched and readily available at delivery. The patient was reviewed by an anaesthetist and discussed in a multidisciplinary meeting prior to induction.

Results: The patient was induced at 38 weeks and had a forceps delivery, with 800ml of blood loss. She unfortunately sustained a 3c tear which was repaired.

Conclusion: Klippel-Trenaunay Syndrome is associated with significant morbidity at all stages of pregnancy and therefore requires careful multidisciplinary obstetric management. Specific anticipation of venous thromboembolism and post partum haemorrhage is needed. A guideline for management of KTS in pregnancy would be of great benefit.

Summary

We describe a case of pregnancy in a patient with Klippel Trenaunay syndrome (KTS), a rare condition characterised by venous malformations, affecting an estimated 1 in 30,000-100,000 live births [1]. A 35 year old primip is identified as needing specialist input for KTS at 35 weeks pregnant. Obstetric management was based largely upon current literature as there are no specific guidelines for the management of this condition in pregnancy. Primary risks were identified; including venous thromboembolism, post-partum haemorrhage, complicated administration of loco-

regional anaesthesia and difficult delivery by caesarean section. In view of these risks, the patient was initiated on low molecular weight heparin, and had an MRI spine and pelvis. She was induced at 38 weeks and went on to have a forceps delivery with 800ml blood loss. Unfortunately she also sustained a third degree tear. Both mother and baby are discharged soon after delivery and the patient is followed up for her perineal tear.

Background

Klippel-Trenaunay syndrome (KTS) is a rare vascular disorder

characterised by capillary malformation (port wine stain), venous malformation and limb hypertrophy [1]. Few cases have been described in pregnancy however the syndrome is associated with significantly increased risk of venous thromboembolism and post-partum haemorrhage [2]. We have described a case of KTS in a 35 year old primip.

Case

A 35 year old primip, presents to antenatal clinic when she is 35 weeks pregnant. She had forgotten to disclose a known diagnosis of Klippel Trenaunay Syndrome at booking and subsequently was reviewed later in pregnancy by the consultant team. On examination the patient's right leg had prominent veins and a large port wine stain extending up to the buttock and lumbar spine. She had previously undergone vein stripping in 2012 at a tertiary unit, where a diagnosis of KTS was made based on her clinical presentation and histology post-procedure. Her past medical history is otherwise unremarkable. Since her diagnosis the patient has been wearing compression stocking daily.

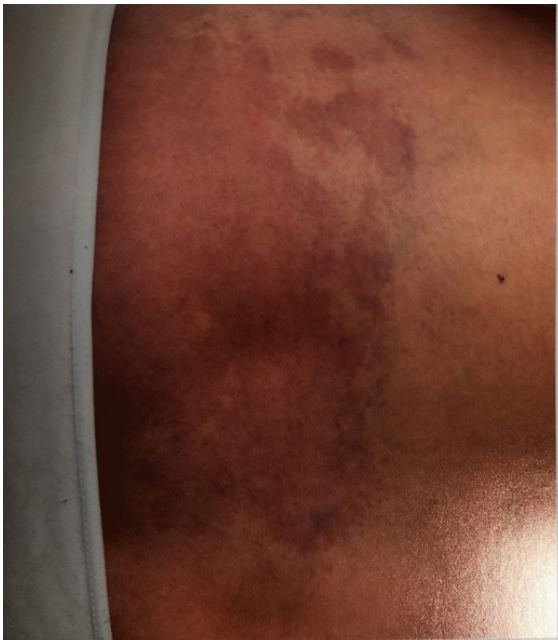

Figure 1: Posterior aspect patient's left leg showing large port wine stain characteristic of Klippel Trenaunay syndrome.

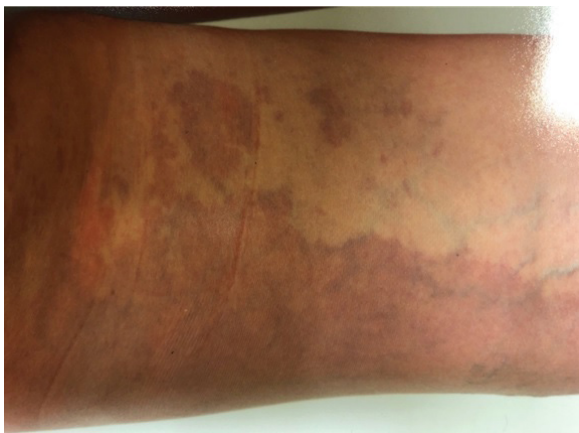


Figure 2: Large Port wine stain seen in figure 1 extends up to cover the patient's lumbar spine as shown.

Investigations

A coagulation screen was performed which was normal. An MRI Spine and Pelvis showed evidence of bilateral pelvic varicoceles but no tissue haemangiomas. No concerning features were seen on imaging of the spine.

Treatment

The patient was admitted for induction of labour at 38 Weeks, She progressed well to full dilation and required an epidural for analgesia. She had a forceps delivery and episiotomy due to failure to progress in the second stage. Unfortunately she also sustained a 3c tear which was repaired in theatre. Total blood loss was 800ml, there were no prominent vessels noted at delivery.

Outcomes

The patient was discharged several days after admission. She was reviewed 4 weeks following delivery in view of her third degree tear.

Discussion

Klippel Trenaunay syndrome, is a rare non hereditary disease, with an estimated prevalence of 1 in 30 000–100 000 live births [1]. It is characterised by venous malformations typically affecting the extremities however these can also extend to the pelvis and genitalia [2,3]. Certain physiological changes in pregnancy; including the development of pedal odema, venous stasis and increased venous pressure, can exacerbate the condition [3]. In view of this, careful obstetric management is required at each stage of pregnancy. Development of venous thrombosis and pulmonary thromboembolism are the main risks antenatally [1,3,4, 6]. Prophylactic low molecular weight heparin should be offered and continued up to 6 weeks postnatally.

Antenatal anaesthetic review is highly recommended. There is potential for neurovascular malformations in the spinal cord and surrounding structures [5,6]. These could complicate the administration of loco-regional anaesthesia and should be assessed by magnetic resonance imaging of the spine. In addition imaging of the pelvis can identify any significant pelvic varices or haemangiomas which could lead to excessive bleeding at caesarean section [3]. If a general anaesthetic is needed, there is potential difficulty in airway management as some patients with KTS have soft tissue hypertrophy in the mouth, hypopharynx and facial anomalies [6]. Chronic coagulopathies including disseminated intravascular coagulation also can be encountered [6,7].

Bleeding risk is high at the time of delivery in both vaginal delivery and caesarean section. Patients can present with vulvo-vaginal varicosities which may even obstruct the vaginal introitus [3]. Vascular malformations can also affect the cervix and a case of cervical cavernoma has even been described [8]. Massive Postpartum Haemorrhage should therefore be anticipated and

blood products should be made easily available at delivery.

As aforementioned, pelvic varices and haemangiomas may lead to excessive bleeding at the time of caesarean section. It would be appropriate to counsel patients on the possibility of hysterectomy, utilise cell salvage, have blood products on standby and to also have a consultant leading the operation if possible. Neonatal review to screen for the condition is recommended however transmission to baby is rare, as the condition is likely the result of somatic mosaicism and generally regarded as non-hereditary [1].

Learning Points

- Klippel-Trenaunay Syndrome is a rare condition associated with significant morbidity at all stages of pregnancy.
- Careful, multidisciplinary obstetric management is highly recommended.
- Primary risks identified include venous thromboembolism and post partum haemorrhage, however risk for general and locoregional anaesthesia should also be assessed.
- If possible a consultant should be present at the time of delivery and adequate preparations should be made to anticipate massive obstetric haemorrhage.

References

1. Horbach SE, Lokhorst MM, Oduber CE, et al. Complications of pregnancy and labour in women with Klippel-Trenaunay

syndrome: a nationwide cross-sectional study. *BJOG*. 2017; 124: 1780-1788.

2. Klippel M, Trenaunay P. Naevus variqueux osteo-hypertrophique. *Archives Générales de Médecine*. 1900; 3: 641-672.
3. Tuğba Güngör Gündoğan, Jacquemyn Y. Case Report Klippel-Trenaunay Syndrome and Pregnancy. *Obstet Gynecol Int*. 201; 706850.
4. Gianlupi A, Harper RW, Dwyre DM, et al. Recurrent pulmonary embolism associated with Klippel Trenaunay-Weber Syndrome. *Chest*. 1999; 115: 1199-1201.
5. Barbara DW, Wilson JL. Anesthesia for surgery related to Klippel-Trenaunay syndrome: a review of 136 anesthetics. *Anesth Analg*. 2011; 113: 98-102.
6. Joon-Ho Lee, Hae-Un Chung, Mi-Soon Lee. An anesthetic management of a patient with Klippel-Trenaunay syndrome *JKorean J Anesthesiol*. 2012; 63: 90-91.
7. Ulf H Beier, Mary Lou Schmidt, Howard Hast, et al. Control of disseminated intravascular coagulation in Klippel-Trenaunay-Weber syndrome using enoxaparin and recombinant activated factor VIIa: a case report *Journal of Medical Case Reports*. 2010; 4: 92.
8. Pichierra A Piccirilli M, Passacantilli E, Frati A, Santoro A. Klippel Trenaunay- Weber Syndrome and intramedullary cervical cavernoma: a very rare association. Case report. *Surg neurol*. 2006; 66: 203-206.