

## Clinical Presentation and VRT-CT Features in Pediatric Patients with COVID-19 Infection

Hüseyin Avni Solgun<sup>1\*</sup> and Işıl Yurdaışık<sup>2</sup>

<sup>1</sup>Health Science University, Basaksehir Cam and Sakura Training and Research Hospital, Department of Pediatric Hematology and Oncology, Istanbul.

<sup>2</sup>Istinye University Medical Park Gaziosmanpaşa Hospital, Istinye University Medical Faculty, Department of Radiology, Istanbul.

### \*Correspondence:

Huseyin Avni Solgun, M.D., Health Science University, Basaksehir Cam and Sakura Training and Research Hospital, Department of Pediatric Hematology and Oncology, Istanbul, Tel: +90 212 909 60 00, +90 505 899 05 72.

Received: 14 Dec 2021; Accepted: 08 Jan 2022; Published: 11 Jan 2022

**Citation:** Solgun HA, Yurdaışık I. Clinical Presentation and VRT-CT Features in Pediatric Patients with COVID-19 Infection. J Med - Clin Res & Rev. 2022; 6(1): 1-6.

### ABSTRACT

**Objective:** The aim of this study is to discuss the clinical, laboratory, chest computed tomography (CT) and volumetric imaging technique (VRT) features in pediatric patients with novel coronavirus 2019 (COVID-19) infection.

**Material and Methods:** The clinical, laboratory, and chest CT features of 17 pediatric patients with COVID-19 infection those confirmed by pharyngeal swab COVID-19 polymerase chain reaction (PCR) were evaluated. All clinical and laboratory data have been recorded and analyzed during March-February 2021. Chest CT have been performed to all Covid 19 PCR confirmed patients and radiologically view have been noted.

**Results:** Seventeen pediatric patients with a history of close contact with COVID-19 diagnosed family members included to the study. Fever (10/17, 58%) and cough (13/17, 76%) were the most common symptoms. For laboratory findings, C reactive protein elevation (15/17, 88%) seem to be the most finding. A total of 4 patients presented with unilateral pulmonary lesions (4/17, 23%), 9 with bilateral pulmonary lesions (9/17, 52%) and 13 cases showed bilateral diffuse covid pattern on chest CT (13/17, 76%). Non-specific consolidation was observed in 8 patients (8/17, 47%), ground-glass opacities were observed in 11 patients (11/17, 64%), nodules were observed in 7 patients (7/17, 41%), and tiny nodules were observed in 2 patients (2/17, 11%).

**Conclusion:** In pediatric patients before confirmation positivity of COVID-19 nucleic acid test from pharyngeal swab samples; the early detection of lesions with chest CT especially by VRT (volumetric rendering technique)-CT technique can be efficient; in management and early treatment for pediatric patients. More clinical trials can suggest about the primeline screening and treatment options in pediatric covid-19 infection in future.

### Keywords

Pediatric, Covid-19, Viral pneumonia, Chest computed tomography (CT), VRT (volumetric rendering technique).

### Whats known

-From the early days of the outbreak to this moment; the disease showed that there were to less cases in children under the age of 15.

-Laboratory-diagnosed cases from all over China through January 29, 2020, indicated that 0.9% of patients were aged below 15

years, which means that COVID-19 can be spread within the whole age spectrum [6].

-In patients with positive COVID-19 nucleic acid test from pharyngeal swab samples and especially in course of cough and respiratory other symptoms; the early detection of lesions by chest CT is very efficient to decide life-saving treatment for pediatric patients.

### Whats add

-In this study; clinical and imaging features of pediatric patients with COVID-19 infection were presented in a series of 17 cases

who have been identified by the pharyngeal swab COVID-19 nucleic acid test.

-This is the first report in the literature discussing VRT-CT technique in this age group of COVID-19 pneumonia. Skilled imaging techniques will be useful especially symptom positive but covid-19 semar pcr negative patients.

## Introduction

A pneumonia epidemic broke out in Wuhan and then spread to other Chinese cities and several countries respectively in December 2019. A new type of coronavirus announced by the Chinese Center for Disease Control and Prevention on January 7, 2020 [1]. Finally; on February 11, 2020, the International Committee on Taxonomy of Viruses (ICTV) proposed to name the new virus SARS-CoV-2 and the WHO named the disease caused by SARS-CoV-2 infection COVID-19 [2,3]. As of today, 8 months after the onset of epidemic, China's domestic COVID-19 epidemic has been well controlled contravariouly the epidemic spreaded to many countries worldwide [4]. Lately; the virus outbreak in countries of Europe and America are severely affected at this moment, which means that COVID-19 has evolved from an epidemic to pandemic. From the early days of the outbreak to this moment; the disease showed that there were to less cases in children under the age of 15 [5]. Soon afterwards, laboratory-diagnosed cases from all over China through January 29, 2020, indicated that 0.9% of patients were aged below 15 years, which means that COVID-19 can be spread within the whole age spectrum [6].

In this study; clinical and imaging features of pediatric patients with COVID-19 infection were presented in a series of 17 cases who have been identified by the pharyngeal swab COVID-19 nucleic acid test.

## Material and Methods

Seventeen pediatric patients with COVID-19 infection confirmed by pharyngeal swab COVID-19 nucleic acid test from March to February 2021 in our university hospital were included in this study. All the patients were in accordance to the Diagnosis and Treatment Protocol for COVID-19 by the National Health Commission.

Clinical data including demography information, contact history, previous history, clinical symptoms, laboratory findings, and coinfection which defined as a concurrent infection of a patient with two or more pathogens simultaneously.

The chest CT were obtained from all subjects, as the plain chest X-ray cannot exclude the existence of pulmonary lesions, especially for the patients without symptoms and mild cases. For all the patients, noncontrast chest CT studies were performed on SOMATOM Definition AS 128 unit (Siemens medical system; Siemens, Germany) with the following parameters: 120 kV, 100 to 150 mA, 0.6-mm collimation, and 1:1 pitch. The scanning range covered from lung apex to diaphragm on axial plane taken under free breathing with the patients in the supine position. Chest CT images were reconstructed with 3 or 4 mm collimation with a standard algorithm and then sent to the picture archiving and

communication system (PACS) for analyzing. Chest CT images were evaluated using a lung window with a window level of -600 HU a window width of 1500 HU, and the soft-tissue window with a window level of 40 HU and window width of 300 HU. All the images were stored in PACS and reviewed by experienced pediatric radiologists. Chest VRT-CT imaging of all patients included in the study were also done in the same time with conventional chest CT. The chest CT features were evaluated as follows: (a) ground-glass opacities, (b) consolidations with surrounding halo sign, (c) nodules, (d) fine mesh shadow, (e) pleural effusion, (f) lymphadenopathy, (g) unilateral or bilateral, (h) subpleural or nonsubpleural, and (i) residual fiber strips. Pharyngeal swab samples of all the subjects in this group were collected, and the COVID-19 RNA was identified by a reverse transcription-polymerase chain reaction.

The protocol for this retrospective study was approved in 07.07.2020 by the Ethics Committee of Istinye University Medical Park GOP Hospital with no: 2/2020.K-048 and the written informed consent was taken from patients parents'. This study had been conducted according to Helsinki declarations guidance.

## Results

Seventeen pediatric patients with a history of close contact with COVID-19 diagnosed family members included to the study. Fever (10/17, 58%) and cough (13/17, 76%) were the most common symptoms. The clinical features of pediatric patients with COVID-19 infection were displayed in Table 1.

**Table 1:** The clinical features of pediatric patients with COVID-19 infection.

Characteristic	Number (%)
Sex	Boy 9 (53%)
	Girl 8(47%)
Age	2< 3(17%)
	2-5 2(11%)
	5-10 4(23%)
	10> 8(47%)
Contact history	Yes 10 (59%)
	No 7 (41%)
Symptom	Cough 11 (64%)
	Tachypnea 4 (29%)
	Fever 9 (52%)
	Nasal discharge 4 (23%)
	Diarrhea 3 (17%)
	Fatigue 2 (11%)
	Cardiac arrhythmia 1 (5%)
	Other (otit,abdominal pain...) 3 ( 17%)

For laboratory findings, c reactive protein elevation (15/17, 88%) seem to be the most finding. Other laboratory features of pediatric patients with COVID-19 infection for alanin amino transferase, aspartat amino transferase, blood urea nitrogen, creatinine, white blood cell, hemoglobuline, prothrombine time, activated parsiel thromboplastine time, troponin t, creatinin cinase were not markible at all.

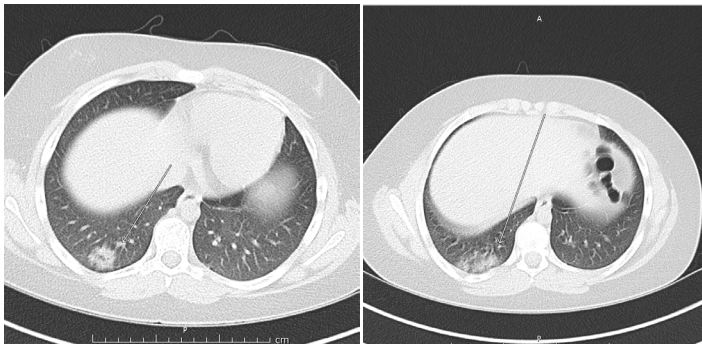A total of 4 patients presented with unilateral pulmonary lesions (4/17, 23%), 9 with bilateral pulmonary lesions (9/17, 52%) and 13 cases showed bilateral diffuse covid pattern on chest VRT-CT (13/17, 76%). Non-specific consolidation with was observed in 8 patients (8/17, 47%), ground-glass opacities were observed in 11 patients (11/17, 64%), nodules were observed in 7 patients (7/17, 41%), and tiny nodules were observed in 2 patients (2/17, 11%).

The CT imaging features of pediatric patients with COVID-19 infection were displayed in Table 2.

**Table 2:** The CT imaging features of pediatric patients with COVID-19 infection

Features	Number of patients (%)
Pulmonary involvement	
Focal	2 (11%)
Unilateral diffuse	3 (17%)
Bilateral diffuse	12 (70%)
Subpleural lesions	15 (88%)
Nonspecific consolidation	2(11%)
Ground-glass opacification	12 (70%)
Nodules	1 (5%)

For CT imaging findings; The lesion density was heterogeneous, accompanied by ground-glass opacities and pleural thickening (Figure 1A). 12 year old girl. After 5 days, the opacity in ground glass density in the posterior basilar segment of the right lower lobe increased in size. (Figure 1B). There were no other accompanying thoracic findings in chest CT imaging of this 12 years old girl patient.



**Figure 1a,1b:** 12 year old girl. It was observed that opacity in ground glass density in the posterior basilar segment of the right lower lobe increased in size after 5 days. There were no other accompanying thoracic findings.

In another 16-year-old male patient, the first Chest CT imaging finding was observed with an increase in subpleural ground glass density in the left lower lobe posterior segment. (Figure 2A) When viewed immediately, ie 2 to 4 days later, the density began to decrease and the contour clarity began to disappear (Figure 2C). The lesion size and density increased significantly 6 days after this diagnosis (Figure 2C). After 14 days (24 days after initial detection) taken for the 4th time, the lung parenchyma is observed normally. (Figure 2D). Chest VRT (volumetric rendering technique)-CT images of the same patient were similar in discussion with better identification (Figures 3A, 3B, 3C, 3D). The chest VRT-CT image is more valuable to see ground glass consolidation and other signs

of COVID-19 pneumonia in children. This is the first report in the literature discussing chest VRT-CT imaging in this age group of COVID-19 pneumonia.

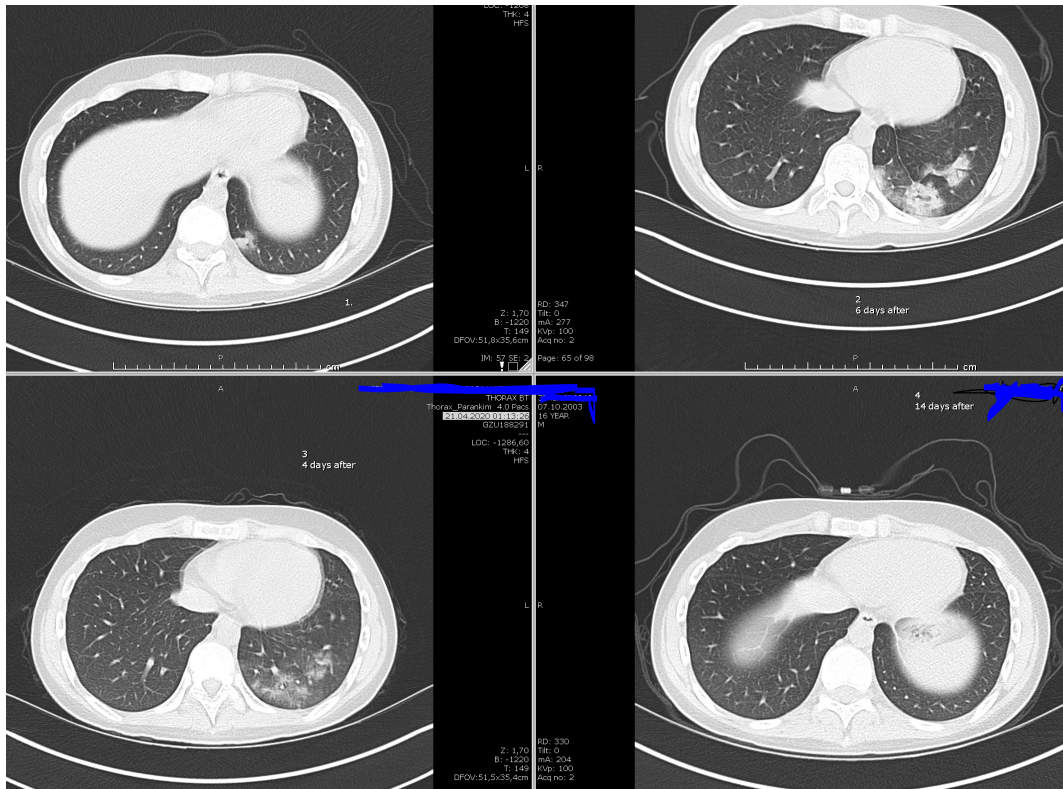
## Discussion

The outbreak of Covid-19 started in Wuhan city, Hubei province, China, where the firstly announced cases in adults with pneumonia of unexplained etiology on December 31, 2019. A local seafood and animal market was defined to be as a potential source. Afterwards; main transmission route to cause outbreak was defined through respiratory droplets or direct contact from symptomatic and asymptomatic humans infected with Covid-19 [7]. Covid-19 has spread to other Chinese cities and internationally and caused a global pandemic.

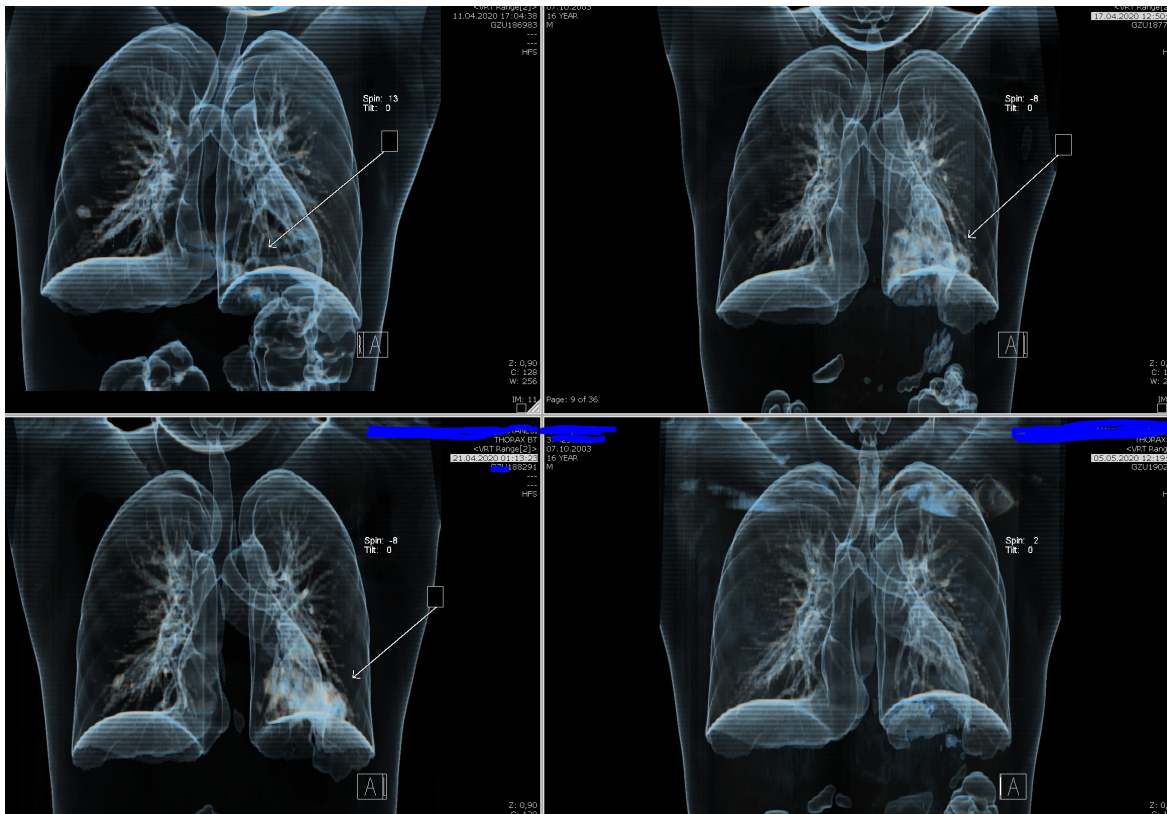
COVID-19 viral pneumonia is an acute infectious respiratory disease caused by a coronavirus subtype SARS-CoV-2. From december 2019 to this moment, 24.355.000 total comfirmed cases, 830.155 deaths and 16.889.000 recovered cases had been confirmed worldwide as WHO (World Health Organization) up to date records, while the actual number would be larger with noncofimed asymptomatic cases [8]. The virus is a highly contagious disease and can be transmitted by an infected person or an asymptomatic carrier through respiratory droplets. Respiratory droplets are the main route of transmission, but can also be transmitted by contact and digestive tract [9]. After contact to infected person; The incubation period is about 1 to 14 days, and is supposed could be up to 24 days. Even most of the cases are mild, especially people over 60 years old or those with underlying diseases are more likely to develop the severe disease of lower respiratory system involvement [10]. The clinical manifestations of children patients are similar to those of adults, such as fever and cough. A few children have diarrhea and runny nose, but the overall symptoms are relatively mild. Its think to be that the COvid-19 infection have a mild and weak clinical progress in children. Conversely to this data; in this study we presented 17 cases those all are under 17 years old with 3 of them under 2 years old cases of Covid-19 infection with severe diseases.

In previous literature Chest CT findings in children were similar to those in adults, and most of them were mild cases [11,12]. In our study; the typical manifestations were unilateral or bilateral subpleural ground-glass opacities, and consolidations with surrounding halo sign. As bilaterally consolidations of lungs sign account for up to 70% cases, they should be considered as typical signs in pediatric patients. Pleural effusion was seen in 4 cases. In Wei and et al study; the data for pleural effusion account zero [13]. Lesions could be still visible on chest CT when two consecutive nucleic acid tests were negative. The CT imaging of COVID-19 infection should be differentiated with other virus pneumonias, such as respiratory syncytial virus, influenza virus, parainfluenza virus, and adenovirus with its spesific radiological signs [14]. In addition, it should be differentiated from atypical bacterial pneumonia such as mycoplasma pneumonia and chlamydia pneumonia. However, multiple agents can overlap chest CT manifestations





**Figures 2a,2b,2c,2d:** (2a): 16-year-old male. The first imaging finding was observed with an increase in subpleural ground glass density in the left lower lobe posterior segment. (2b): When looked at once, that is, after 2 to 4 days, density began to decrease and contour clarity began to disappear. (2c): The lesion size and density increased significantly 6 days after this diagnosis. (2d): After 14 days (24 days after the first detection) taken for the 4th time, the lung parenchyma is observed normally.



**Figure 3a,3b,3c,3d:** VRT (volume rendering technique) images of the same patient in Figure 2.

of pneumonia caused by COVID-19 presenting more serious and complex imaging manifestations which could not be diagnostic, so epidemiological and etiological examination should be combined to make the final decision.

Recently; only a few studies have conducted on chest CT signs of COVID-19 in children age group [15-17]. Even normal findings on chest CT; some of pediatric patients manifest a severe clinical disease of COVID-19 pneumonia.

The CT manifestations of COVID-19 in pediatric patients are diverse and lack specificity. Some mild pediatric patients with COVID-19 show [18,19].

In pulmonary involvement cases; focal unilateral or bilateral diffuse, subpleural lesions, nonspecific consolidation, ground-glass opacification and nodules are the most presentations. Pediatric patients with COVID-19 tend to present less lobular involvement with an increase in subpleural ground glass density in the left lower lobe posterior segments (Figure 1a, 2a). Additionally; some other findings like nodular ground-glass opacification consolidation, consolidation with ground-glass opacification and interlobular septal thickening can also be observed in the pediatric patients [20]. All radiological findings have been summarized in Table 3.

**Table 3:** The CT imaging features of pediatric patients with COVID-19 infection.

Features	Number of patients (%)
Pulmonary involvement	
Focal	2 (11%)
Unilateral diffuse	3 (17%)
Bilateral diffuse	12 (70%)
Subpleural lesions	15 (88%)
Nonspecific consolidation	2(11%)
Ground-glass opacification	12 (70%)
Nodules	1 (5%)

Overall, rarely in pediatric cases, bilateral diffuse lung consolidation can occur and is called as “white lung” [16]. In resolving stage, lung lesions will be completely resolved or only remain minimal linear opacities (Fig.2d,3d). In some cases either can be a presentation of similar to those other viral agents with patchy opacity along the bronchial vascular structure manifesting as bronchopneumonia [16].

Case differential diagnosis should be more carefully done while pediatric patients have definite epidemiological history but atypical CT findings. Xia et al. reported, underlying coinfection is very common in pediatric patients (9 of 20, 45%), Pleural effusion was reported in several pediatric patients [21].

Even the gold standard is nucleic acid detection in diagnosis of COVID-19, in suspicious cases those initial whom Covid 19-PCR results are negative, chest VRT-CT imaging may be supportive for diagnosis and management especially in pediatric age group.

Additionally chest CT can suggest the healing and resolve findings of lung involvement regarding the disease severness and follow up options. In this study the chest CT and VRT-CT findings in 14th day of follow up have been completely recovered (Figure 2d, 3d). Sure the nucleic acid confirmation test negativity can be used in follow up; unfortunately it will not suggest any idea in those cases with pulmonary symptoms in childhood.

## Conclusion

In some children; COVID-19 virus pneumonia has a severe clinical and radiological course and in chest CT can present characteristic changes of subpleural ground-glass opacifications and uni-bilateral consolidations which is so effective for follow up and evaluating the changes of lung lesions. In patients with negative COVID-19 nucleic acid test from pharyngeal swab samples and especially in course of cough and respiratory other symptoms; the early detection of lesions by chest VRT-CT is very efficient to decide life-saving treatment for pediatric patients. This is the first report in the literature discussing VRT in this age group of COVID-19 pneumonia. Skilled imaging techniques will be useful especially symptom positive but covid-19 serology negative patients.

## References

1. Zhu N, Zhang D, Wang W, et al. A novel coronavirus from patients with pneumonia in China, 2019. *N Engl J Med.* 2020; 382: 727-733.
2. Gorbalenya AE, Baker SC, Baric RS, et al. Severe acute respiratory syndrome-related coronavirus the species and its viruses a statement of the Coronavirus Study Group. 2020.
3. <https://www.who.int/dg/speeches/detail/who-director-general-s-remarks-at-the-media-briefing-on-2019-ncov-on-11-february-2020>.
4. National Health Commission of the People’s Republic of China Update on COVID-19 as of 24:00 March 18. National Health Commission of the People’s Republic of China, China. 2020.
5. Li Q, Guan X, Wu P, et al. Early transmission dynamics in Wuhan China of novel coronavirus-infected pneumonia. *N Engl J Med.* 2020; 382: 1199-1207.
6. Guan W, Ni Z, Hu Y, et al. Clinical characteristics of 2019 novel coronavirus infection in China. *N Engl J Med.* 2020.
7. Chan JF, Yuan S, Kok KH, et al. A familial cluster of pneumonia associated with the 2019 novel coronavirus indicating person-to-person transmission a study of a family cluster. *Lancet.* 2020; 395: 514-523.
8. Parry J. Wuhan Britons to be evacuated as scientists estimate 44 000 cases of 2019-nCoV in the city. *Brit Med J.* 2020; 368: m351.
9. Riou J, Althaus CL. Pattern of early human-to-human transmission of Wuhan 2019 novel coronavirus 2019-nCoV. *Euro Surveill.* December 2019 to January 2020. 2020; 25: 7-11.
10. Hui DS, Azhar EI, Madani TA, et al. The continuing 2019-nCoV epidemic threat of novel coronaviruses to global health the latest 2019 novel coronavirus outbreak in Wuhan China. *Int J Infect Dis.* 2020; 91: 264-266.

- 
11. Kanne JP. Chest CT findings in 2019 novel coronavirus 2019-nCoV infections from Wuhan, China key points for the radiologist. *Radiology*. 2020.
  12. Song F, Shi N, Shan F, et al. Emerging coronavirus 2019-nCoV pneumonia. *Radiology*. 2020.
  13. Wei Xia, Jianbo Shao, Yu Guo, et al. Clinical and CT features in pediatric patients with COVID-19 infection Different points from adults. 26 February 2020, *Pediatric Pulmonology*. 2020; 1-6.
  14. Virkki R, Juven T, Rikalainen H, et al. Differentiation of bacterial and viral pneumonia in children. *Thorax*. 2002; 57: 438-441.
  15. Feng K, Yun YX, Wang X. Analysis of CT features of 15 children with 2019 novel coronavirus infection. *Fetal. Zhonghua Er Ke Za Zhi*. 2020; 58: E007.
  16. Ma H, Shao J, Wang Y, et al. High resolution CT features of novel coronavirus pneumonia in children. *Zhonghua Fang She Xue Za Zhi*. 2020; 54: E002.
  17. Sun D, Li H, Lu XX, et al. Clinical features of severe pediatric patients with coronavirus disease 2019 in Wuhan a single center's observational study. *World J Pediatr*. 2020.
  18. Xia W, Shao J, Guo Y, et al. Clinical and CT features in pediatric patients with COVID-19 infection different points from adults. *Pediatr Pulmonol*. 2020.
  19. Zhao R, Shen X, Xu K, et al. One case report of pediatric infection with COVID-19. *Zhejiang Med J*. 2020; 3: 337.
  20. Ma Y, Xia S, Wang M, et al. Clinical features of children with SARS-CoV-2 infection an analysis of 115 cases. *Chin J Contemp Pediatr*. 2020; 22: 1-4.
  21. Zhou Y, Yang GD, Feng K, et al. Clinical features and chest CT findings of coronavirus disease 2019 in infants and young children. *Zhongguo Dang Dai Er Ke Za Zhi*. 2020; 22: 215-220.