

Coagulopathy and Thromboembolism in COVID-19: A Review

Filipa Ribeiro Lucas^{1*}, Emília Araújo², João Gigante³, Soraia Silva⁴, Yasar Yousafzai⁵, Addisu Demeke Teklemariam⁶, Anwar M. Hashem⁷, Pedro Vieira⁸, Maria Eugénia André⁹, and Steve Harakeh, Ph.D.^{10*}

¹Centro de Responsabilidade Integrada de Medicina Interna, Castelo Branco, Portugal.

²Serviço de Imuno-Hemoterapia, Hospital de São José, Lisboa, Portugal.

³Serviço de Patologia Clínica, Hospital Prof. Doutor Fernando da Fonseca.

⁴Centro de Responsabilidade Integrada de Medicina Interna, Castelo Branco, Portugal.

⁵Associate Professor (Hematology), Institute of Basic Medical Sciences, Khyber Medical University

⁶Biology Department, Faculty of Science, King Abdulaziz University, Jeddah, Saudi Arabia.

⁷Vaccines and Immunotherapy Unit, King Fahd Medical Research Center (KFMRC); Department of Medical Microbiology and Parasitology, Faculty of Medicine, King Abdulaziz University, Saudi Arabia.

⁸Centro de Responsabilidade Integrada de Medicina Interna, Castelo Branco, Portugal.

⁹Diretora do Centro de Responsabilidade Integrada de Medicina Interna; Diretora Clínica Hospitalar, Castelo Branco, Portugal.

¹⁰Special Infectious Agents Unit, Head of Safety Committee, King Fahd Medical Research Center, King Abdulaziz University, Saudi Arabia.

Citation: Lucas FR, Araújo E, Gigante J, et al. Coagulopathy and Thromboembolism in COVID-19: A Review. Clin Rev Cases. 2022; 4(1): 1-9.

*Correspondence:

Filipa Lucas, Centro de Responsabilidade Integrada de Medicina Interna, Castelo Branco, Portugal.

Steve Harakeh, Special Infectious Agents Unit, Head of Safety Committee, King Fahd Medical Research Center, King Abdulaziz University, Saudi Arabia.

Received: 31 Dec 2021; **Accepted:** 01 Feb 2022; **Published:** 05 Feb 2022

ABSTRACT

The emergence of the novel coronavirus, SARS-CoV-2 (severe acute respiratory syndrome coronavirus 2) has resulted in a major global pandemic posing various challenges to the worldwide health care systems. Clinical course of the infection, known as coronavirus disease of 2019 (COVID-19), ranges from mild subclinical disease to a life-threatening systemic illness. Common symptoms include a flu-like illness with fever and inflammation, and in severe cases pneumonia and systemic inflammation that results in morbidity and mortality. One of the complications of COVID-19 is its disruption of normal hemostasis resulting coagulopathy and thromboembolism. In this following review, we discuss present knowledge; summarize existing published information on the underlying mechanisms of action for COVID-19-associated coagulopathy; and propose algorithms for screening, management, and prevention of COVID-19 patients.

Many at-risk COVID-19 patients develop coagulopathies that can broadly be labelled as venous thromboembolism (VTE). These coagulopathies may occur separately or in combination, and include pulmonary embolism (PE), deep vein thrombosis (DVT) and acute large vessel occlusion resulting in stroke, myocardial infarction, ischemic and systemic arterial events. Laboratory-based testing is mandatory in the case of severely infected COVID-19 patients for screening of their coagulation status. Based on recent data, a major elevation in the levels of the D-dimer is used as a predictor of the adverse outcomes of the disease.

An imbalance between inflammation and coagulation may lead to a hypercoagulable state resulting in endothelial injury associated with a loss of dysregulation of fibrinolysis, excess thrombin generation, thrombi protective mechanisms, and thrombosis. Other involved mechanisms that may lead to an increased VTE risk, include the following: microvascular thrombosis, endothelial damage, leukocyte recruitment, systemic inflammation – the presence of the virus in endothelial cells, higher vascular permeability, destruction of cell membranes, platelet activation, and occlusion with ACE dysfunction, or even autoimmune mechanism. In all hospitalized COVID-19 patients, prophylaxis against thromboembolism is extremely important, especially in patients with elevated D-dimer levels and other coagulation abnormalities.

Keywords

COVID-19, Venous thromboembolism, Hypercoagulable state, D-dimer, Prophylaxis.

Introduction

The emergence of the severe acute respiratory syndrome-coronavirus-2 (SARS-CoV-2) has resulted in a major global pandemic with life-threatening systemic disease, known as the coronavirus disease of 2019 (COVID-19) [1,2]. Across the globe, the virus disseminated at a high rate within communities, countries, and regions. This rapid spread coupled with lack of knowledge of the pathogenesis and effective treatment options resulted in huge challenges to healthcare systems [3]. Nearly two years later, significant strides have been made in understanding the disease causation, transmission, and treatment. While SARS-CoV-2 infection mainly affects the lower and upper respiratory tract, it could disseminate and afflict other organs in the body [4,5]. In severe cases, pulmonary inflammation results in pneumonia and consequently systemic tissue hypoxia. In a smaller proportion of cases, respiratory failure may result in death [3]. However, other causes of death such as coagulopathy and thrombosis could lead to progression to multiple-organ failure [5,6]. A condition known as cytokine storm syndrome ensues associated with excessive immune/inflammatory response resulting in widespread coagulation activation [7].

Several human viral infections such as Ebola, Congo-Crimean Hemorrhagic fever virus, and Dengue virus cause hemorrhagic manifestations, in which viral replication usually result in vascular damage and coagulopathy. Consequently, disseminated intravascular coagulation (DIC) with prominent bleeding results. In contrast, SARS-CoV-2 infection is associated with more thrombotic complications such as venous thromboembolism (VTE), deep venous thrombosis (DVT), and pulmonary embolism (PE) [8].

Early reports suggest that COVID-19 patients, including those receiving critical care, are at significant risk of thromboembolic complications [1]. Soon after its identification, COVID-19 was labelled as a multiorgan disease marked by a dysregulated immune system and a hypercoagulable state associated with raised levels of D-dimer, factor VIII, and fibrinogen, a shortened activated partial thromboplastin time (aPTT), and an elevated sepsis-induced coagulopathy score [1-3,9]. In patients with severe illness, regardless of whether they have other risk factors for thrombosis, thrombosis can occur as DVT, PE, VTE, acute large vessel occlusion associated with or without ischemic stroke, myocardial infarction and systemic arterial events [10], leading to high rates of morbidity and mortality. For this reason, it is recommended to measure the fibrinogen and D-dimer levels in patients [3]. Despite anticoagulant prophylaxis and treatment being used in COVID-19 patients' [4], thromboembolism risk stratification and the optimum intensity and period of anticoagulant thromboprophylaxis are not yet determined [9].

In this review, a literature search was conducted using PubMed search engine based on original systematic reviews, observational

cohort studies, randomized control trials, case series, and case control studies. The purpose of this review was to gather up-to-date evidence on the role of coagulopathy in predicting the severity and mortality of COVID-19 infection, and to assess the thromboembolism incidence and risk as well as thromboprophylaxis strategies. Because there are no clear guidelines for preventing and treating coagulopathy and thromboembolism in patients with COVID-19, the following clinical questions need further elucidation.

Are the hemostatic changes due to severe inflammation or virus-mediated effects in COVID-19 infected patients?

In severe cases of COVID-19, a spectrum of infection-related complications is seen along with coagulation abnormalities. Whether these coagulopathies are the direct result of virus induced activation of the coagulation pathway, or caused by severe inflammation, is not well understood. Infections lead to activation of inflammation and result in intricate and controlled activation of the coagulation system at the site of inflammation benefitting the host immune response [3]. Its unregulated, pathological counterpart, the Virchow's triad, involves venous hemostasis, activation of coagulation, and endothelial damage. This pathological paradigm provides basis for better understanding of thrombosis and its occurrence in veins, arteries, or the microvasculature [20].

The International Society of Thrombosis and Hemostasis (ISTH) defines the clinical criteria for the so-called COVID-19-associated coagulopathy (CAC) as activation in coagulation is initially localized in the lung microcirculation, however, when it expands systemically [3]. The laboratory and clinical features of CAC partially overlap with sepsis-induced coagulopathy (SIC), hemophagocytic syndrome (HPS), DIC, hemophagocytic lympho-histiocytosis (HLH), thrombotic microangiopathy (TMA), and antiphospholipid syndrome (APS). Nevertheless, the pathophysiology of CAC is significantly different from that of septic DIC in which both hemorrhagic and thrombotic pathologies are observed [20].

CAC is likely multifactorial, and a number of pre-existing conditions may aid the development of thromboembolism (TE). These extrinsic and intrinsic risk factors for thromboembolism include advanced age, immobility, obesity, history of thrombophilia or familial VTE, cancer, chronic heart disease, diabetes, respiratory failure, recent surgery, pregnancy, and trauma. Furthermore, treatment related and ICU-specific risk factors – such as vasopressors, sedation or large vascular-access catheters also contribute to TE [9,11].

The biological mechanisms that COVID-19 may contribute to increased TE risk include systemic inflammation, endothelial damage, leukocyte recruitment in the microvasculature, natural anticoagulant pathways changes (e.g., through changes in levels of thrombomodulin, proteins S and C, and tissue-factor) [8]. Also, it causes platelet activation, occlusion with ACE dysfunction, microvascular thrombosis or even autoimmune mechanisms [11] (Figure 1).

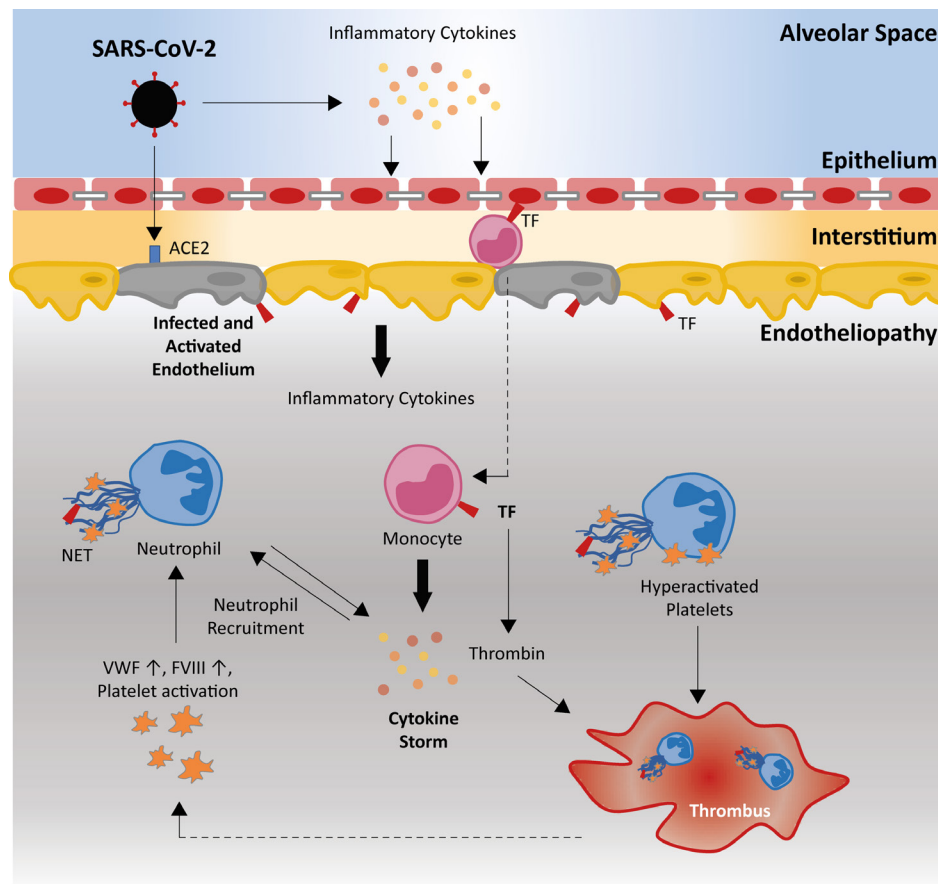


Figure 1: Pathophysiology of the hypercoagulable state. The Covid-19 pathophysiology includes severe inflammatory response and thrombosis. This highlights the importance of ACE2 receptors that promotes the endothelial disfunction, the increased levels of VWF and FVIII and NET formation.

a) Systemic Inflammation

An essential part of innate immunity includes the systemic inflammatory response [3]. Systemic inflammation in combination with hypoxia and acute lung injury could lead to “cytokine storm” which is associated with release of interleukins-1 (IL-1), 6, and 8, inflammatory cytokines and tumor necrosis factor that have pleiotropic effects [8,10]. Local sustained inflammation induces release of IL-6 and IL-1 β which in turn induce hyperfibrinogenemia. The expression of tissue factors on monocytes and macrophages is induced by the virus and its components upon binding to pattern recognition receptors on immune cells [3]. This process also promotes thrombosis and activation of coagulation through various mechanisms, including thrombin generation which is a critical communication factors among the cellular and humoral immune pathways, which is known as thromboinflammation [3].

b) Coagulopathy and fibrinolytic imbalance

The SARS-CoV-2 virus itself does not have intrinsic procoagulant properties. However, several procoagulant pathways are involved in inflammatory responses initiated in COVID-19 patients [3]. Laboratory tests reveal abnormal coagulation profiles in nearly 20–55% severely infected COVID-19 hospital admitted patients [4]. Laboratory findings include high levels of serum D-dimer (>1.5 μ g/mL), lactate dehydrogenase (LDH), total bilirubin

level and fibrinogen levels, in addition to slight prolongation of partial thromboplastin time (PT), mild thrombocytopenia and lymphocytopenia [3,12], and increased blood viscosity as shown by viscoelastic coagulation tests [4].

Activation of the endothelium in severe cases of COVID-19 infection is accompanied by very high blood levels of the von Willebrand factor (VWF) and FVIII [4]. The sharp rise in D-dimer levels is also observed and is due to the activation of fibrinolytic pathway in alveoli. This activation is mediated by urokinase-type plasminogen activator (u-PA) released from the alveolar macrophages. Elevated levels of ferritin, imbalance of serine proteases, and fibrinolytic dysregulation contribute to the fibrinolytic deficit that have been reported in COVID-19 infected patients [5]. Additionally, inhibitors of the serine protease enzyme including anti-thrombin, protein C, and C1 esterase inhibitor are reduced because of infection-related inflammatory response. Release of cytokines may also activate endothelial cells and may cause injury to those cells [3]. Preserved antifibrinolytic α 2-antiplasmin as well as endogenous anticoagulant activity in patients with COVID-19, (protein C & S activity defects, antithrombin activity, and increased Plasminogen Activator Inhibitor-1 (PAI-1) have also been indicated to be a major factor in severe acute respiratory distress syndrome (ARDS) [3,4].

c) Endothelial damage

Endothelial cells maintain a vascular barrier that modulates platelet and immune cell interactions, mediates capillary tone, and promotes endothelial cell adhesion [13]. A viral infection of the endothelium can affect microvascular perfusion which will lead to thrombocytopenia, capillary injury, and vascular leakage. SARS-CoV-2 infection causes endothelial dysfunction at multiple levels including vasoconstriction, inflammatory activation, leucocyte infiltration, cytokine storm, thrombosis, platelet aggregation, increased permeability, production of reactive oxygen species (ROS), and apoptosis [14]. When endothelial function is disrupted, the basement membrane is exposed and the clotting cascade is activated, causing clotting abnormalities and thrombosis [15].

One of the pathognomonic features of COVID-19 is the lung damage caused by entry of viral particles in alveolar and microvascular endothelial cells. This endothelial damage results in fibrin deposition mediated via the up-regulation of fibrinolysis by u-PA in the alveoli. Such an endotheliopathy activates the thrombo-inflammatory response seen in lungs [3]. This localized response can become exaggerated and progress to a wide-spread systemic response inflicting other organs and tissues. The extent of this progression is varied amongst different patients and explain the spectrum of end-organ damage seen within COVID-19 cases.

Generally, COVID-19 is likely to cause life-threatening complications due to endotheliosis, endothelial injury, endothelial cell dysfunction, and impaired blood flow in different vascular beds, which may ultimately result in venous thromboembolic disease and multiple organ failure including but not limited to acute renal failure, acute respiratory failure, myocarditis, and thrombosis [13].

d) Platelets

Inflammatory signaling as well as infectious responses are two of the functions of platelets. Platelets can combine thrombotic and immune recruitment functions to prevent microbial invasion [16] by concentrating hemostasis and immune responses. They can either promote or protect immune-based responses against pathogens. Platelets attach to several different microorganisms, either via direct contact, often by Fc receptors of platelet, or indirectly via plasma protein channels [5].

COVID-19 causes large immature platelets to be produced by megakaryocytes, which are triggered by the consumption of more platelets. COVID-19 increases the number of immature platelets even when platelet count is normal. It is known that immature platelets are more functional [17], so this may be another factor contributing to increased clotting activity in COVID-19.

Thrombocytopenia (reduction in platelet counts) is associated with increased risk of bleeding. The condition may lead to a worse outcome even without overt thrombocytopenia. Moreover, sequestration of platelet and splenic regulation associated with viral infection should be investigated for its involvement in these processes [5]. Wool and Miller reported that thrombocytopenia

was detected in 5–41.7% of COVID-19 patients (the frequency depends on the severity of the disease). According to Wool and Miller, a gradual decline in platelet counts in patients with COVID-19 could indicate worsening thrombotic status [18].

e) ACE2 receptor and NETs

The SARS-CoV-2 enters the host cell using the angiotensin-converting enzyme 2 (ACE2) surface receptor – dominantly expressed on human endothelial cells. Apart from the alveolar cells, the receptors can be found in the venous and arterial endothelial cells [3,18]. The high expression of these receptors in endothelial cells increases its susceptibility to SARS-CoV-2 [4,20]. This scenario is comparable to angiotensin-II, which is metabolized by ACE-2 to the vasodilatory and anti-inflammatory peptide angiotensin [4]. Similarly, unconstrained replication of the virus induces a defected host response accompanied by coagulation and dysregulation of inflammation [11]. In multiple conditions, the neutrophil extracellular traps (NETs) can also capture a pathogen and is associated with coagulation, inflammation, and thrombosis locally and systemically. Tissue NETs trigger platelet activation and thrombosis [4].

f) Antiphospholipid antibodies

Antiphospholipid antibodies such as anticardiolipin immunoglobulin A (IgA) are associated with viral infections [5,11,21]. However, the function and the existence of antiphospholipid antibodies need to be elucidated and evaluated for their role in COVID-19 infections [11,21].

g) Microvascular thrombosis and other thrombotic manifestations

As frequently seen in severe cases of respiratory viral infection, microvascular thrombosis generating in lungs and expanding to other organs result in multi-organ dysfunction. Somewhat similar microvascular thrombosis is seen in COVID-19 infection [3]. The diffusion of small vessels (arteriole, venule, and capillary) is a pathologic hallmark of COVID-19 infection, intravascular megakaryocytes, and platelet–fibrin thrombosis in all of the main organs, like the lungs, heart, liver, and kidneys. Upon autopsy review, diffuse microvascular thrombi with possible thrombotic microangiopathy (TMA) are revealed in many organs. Pathological investigations showed patchy inflammatory cellular infiltrate with areas of fibrin deposit as their focus [33].

A number of studies have reported post-mortem histological examination of respiratory system in cases of COVID-19 deaths. In different autopsies, macroscopic findings revealed the presence of thrombi in the lung peripheral blood vessels with an enlargement of the right ventricle of the heart. In contrast, microscopic examination displayed many thrombi containing both platelet components and fibrin in small arteries and veins of lungs. Focal degeneration of cardiomyocytes was also reported [6]. Pulmonary microvascular thrombosis is likely to be involved in respiratory failure and ARDS in COVID-19 patients. Others have reported hemorrhagic pulmonary infarcts, pulmonary interstitial fibrosis, luminal stenosis small vessel hyperplasia, and microthrombi [15].

The spread of alveolar damage with a mononuclear response comprising of aggregates around thrombosed small vessels has also been reported [21]. Taken together, it can be suggested that localized microvascular thrombosis is frequent in cases of COVID-19 deaths. Whether localized thrombosis alone is always accompanied by evidence of widespread systemic thrombosis in all cases of deaths remains to be seen.

D-Dimer and other markers

D-dimer is a breakdown product of cross-linked fibrin. D-dimers are produced in the blood because of degradation of stabilized fibrin polymer (fibrin cross-linked with factor XIII) by plasmin and elevated levels indicate that there is a hypercoagulable state and secondary fibrinolysis [22]. D-dimer levels are used for diagnosis, risk-stratification and monitoring of VTEs in a number of conditions. Elevated D-dimer is one of the most common abnormal laboratory coagulation markers in COVID-19 patients [23] and several studies have correlated a high level of D-dimer with disease severity, thrombosis risk prediction, the need for ventilatory support, and mortality [19,24,25]. According to the ISTH guidelines, the levels of D-dimer are sixfold higher than the upper limit of normal appears to be a predictor of thrombotic events and this level can be used as a cut-off for use of a higher dose of low-molecular-weight heparin (LMWH) [9,25]. Despite that, the ISTH does not recommend routine screening for VTE based only on elevated D-dimer levels, due to that an elevated level of D-dimers appears to be more associated with a poor prognosis marker rather than a predictor of VTE in COVID-19 patients [25,26,36]. Besides the levels of thrombin-antithrombin complex (TAT), D-dimer and plasmin- α 2 plasmin inhibitor complex (PIC) are relevant markers for the accurate evaluation of coagulation and fibrinolytic pathways in COVID-19. However, few reports have examined TAT and PIC, which are essential markers for coagulation and fibrinolysis [5,6]. Goshua *et al.* reported an elevation in the levels of PAI-1 in critically ill and non-critically ill COVID-19 patients suggesting the role of endothelial cells as they are the main source of PAI-1. Moreover, this study documented higher concentrations in soluble P-selectin (a marker of endothelial cell and platelet activation) and sCD40L (a marker of platelet and T-cell activation) when compared with the control cohort [4].

Fibrin degradation products (FDP), levels of fibrin, and D-dimer levels are important laboratory tests used in conjunction for prediction and monitoring of coagulopathy in COVID-19 patients. In reported literature, D-dimer levels of nearly 20 μ g/mL, FDPs \geq 100 μ g/mL, and fibrinogen approximately 100 mg/dL has been labelled as important cut-offs for coagulopathy. Since levels of FDP are extremely elevated, while d-dimers are mildly increased, a paradox is seen between d-dimer and FDP levels. PT is sustained, but aPTT prolongation is less noticeable. The reduction in antithrombin is also inconspicuous (maintained at \geq 80%). Large variations in fibrinolysis and coagulation are noticed between 7 and 10 days. In the case of a fatal condition, the level of fibrinogen have been reported as high as 400 mg/dL on day 7 but declined sharply to 100 mg/dL on day 10. D-dimer and FDP levels

raised sharply in just 3 days. Fibrinogen can also be measured recurrently. By knowing the level of these markers, the fibrinolytic and coagulation pathologies of COVID-19 will be significantly clarified in individual patients [6].

D-dimer levels are also used for prediction of thrombotic events. Levels above 1.5 μ g/ml (Normal: 0–0.5 μ g/ml) are associated with a significantly higher probability of thrombotic events [20]. Besides that, total bilirubin with slight prolongation, lactate dehydrogenase, or no changes in PT time or aPTT have been identified [6,22].

In addition to coagulation parameters, markers for inflammation such as C-reactive protein (CRP), ferritin, erythrocyte sedimentation rate (ESR), and procalcitonin at initial presentation, were predictive of critical illness during hospitalization and associated with mortality [25]. Moreover, reports also indicated that higher D-dimer levels, platelet count, CRP, and ESR on presentation were predictive of thrombotic complications during hospitalization. Thrombomodulin might also use as a marker to predict mortality in COVID-19 patients, the status of soluble thrombomodulin might identify patients who could benefit the most from these therapies. Nonetheless, the prognostic efficiency of this marker remained to be confirmed [4].

Thromboprophylaxis and treatment / Should we extend thromboprophylaxis for 4-6 weeks?

Heparin is an anti-inflammatory agent which affects both the vasculature and the airway. Use of heparin in COVID-19 has been recommended due to its action on multiple pathways and effect on COVID-19-associated inflammation [27]. Firstly, heparin is hypothesized to bind to the SARS-CoV-2 spike protein and as such acts as a competitive inhibitor for viral adsorption and entry to the cell, hence reducing viral infectivity. Based on our understanding of the SARS-CoV-2 biology, heparin has been proposed as an anti-COVID-19 agent. It was found that shorter-length heparins, in comparison to those used in therapeutic low-molecular-weight heparin, were not effective in binding to the viral spike protein [27]. Secondly, heparin has been shown to improve coagulation parameters. Patients treated with heparin showed an improvement in the coagulation parameters with lower risk of TE events. Thirdly, heparin is shown to be associated with an increase in lymphocyte counts and a reduction in IL-6 levels in comparison to the control group, therefore it appears to play a role in immune action against SARS-COV-2 as well [27].

The use of anticoagulant agent in critically ill COVID-19 infected patients results in lower mortality in the subpopulation meeting with markedly elevated D-dimer or sepsis-induced coagulopathy criteria [8]. In the case of hospitalized either suspected or confirmed COVID-19 patients, a panel of coagulation tests is done upon admission for initial risk assessment, and then repeated every 48 hours for monitoring. This panel includes, D-dimer, prothrombin time-international normalized ratio (PT/INR), fibrinogen, and aPTT [1,3,10]. Taking into consideration, the high risk of VTE among COVID-19 patients who are critically sick, proper VTE

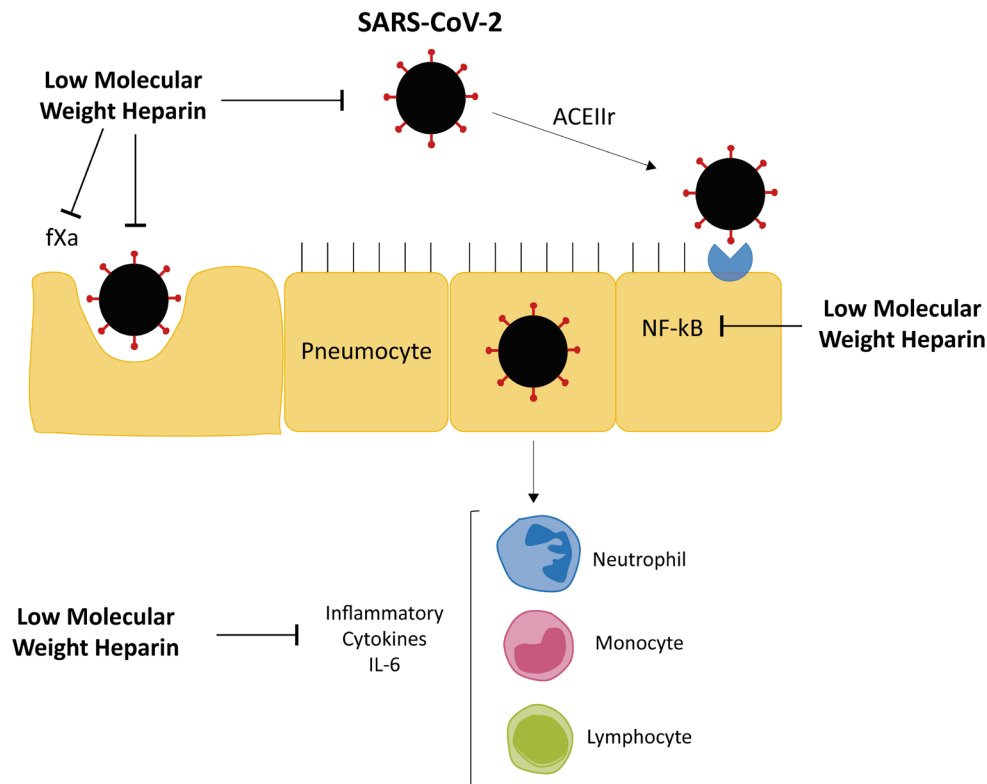


Figure 2: The treatment of patients with covid-19 and the effect of LMWH.

prophylaxis should be followed as a part of the management of those patients [4,8].

The treatment with prophylactic doses of anticoagulants has been shown to lower mortality, and such a treatment may be advised for 4–6 weeks. Even though the extended duration of the use of anticoagulants may be sensible [8], such an approach may lead to a higher risk of bleeding. However, thrombocytopenia and /or prolongation of aPTT or PT are not in themselves contraindications for prophylaxis. Coexisting risk factors should be evaluated before selecting the right antithrombotic agent. It is essential to consider comorbidities, like, thrombocytopenia, hepatic or renal, or gastrointestinal dysfunctions. Usually, parenteral anticoagulation (e.g., UFH) is the right treatment to be followed. However, because of the frequent withdrawal of blood for assessment of the aPTT, LMWHs are preferred (Figure 2).

The practice guidelines recommend thromboprophylaxis with the twice-daily administration of UHF, subcutaneously and once-daily of either fondaparinux or LMWH [1,9,28].

ISTH as well as the British Society of Hematology (BSH) recommends the use of LMWH at prophylactic doses unless active bleeding occurs or a platelet count of $<25 \times 10^9/L$ with periodic monitoring of platelet counts, D-dimer, prothrombin time, and fibrinogen levels are recommended. The treatment of thromboprophylaxis with either LMWH or fondaparinux has been recommended by the American Society of Hematology (ASH)

unless the risk bleeding greatly exceeds the risk of thrombosis. While some of the DOACs are approved for prophylaxis in-hospital settings, these drugs be should be carefully evaluated when used by COVID-19 patients who are on antiviral, immunosuppressant, and other experimental therapies because of interference [9,25]. The use of DOACs may be beneficial as it can be used in-patient, or outside hospital settings. Concerns regarding prompt availability of reversal agents has been raised. For in-patient and home care settings, arrangement should be made to ensure monitoring and reversal if needed [29].

Prolonged VTE prophylaxis is recommended and should be communicated to general practitioners (hematologist or vascular specialist) at early initially prescribed dosage and should be documented upon the discharge of patients. Patients with high inflammatory activity, persistent immobility, and/or additional risk factors are recommended to take prolonged pharmacological VTE for prophylaxis in the ambulatory setting. For venous thromboembolism or catheter-associated thrombosis, anticoagulants should be used for at least 6 weeks and up to 3 months. Several studies have shown that intermittent pneumatic compression devices are an effective way to prevent thrombosis in patients who are contraindicated for anticoagulant treatment. However, little data exist on the effectiveness of thromboprophylaxis in these patients [9]. In summary, anticoagulant therapy has pharmacologic anti-inflammatory, antiviral and cytoprotective efficacy [5].

Duration

The course of treatment should be at least 3 months. Clinically ill patients develop VTE in the post-treatment period in nearly 60% of all cases, with fatal PE rates five-fold higher in the first 3 weeks following treatment [9]. The risk of TE associated with hospital stay remains for up to 4-6 weeks after the patient discharge from the hospital and who received prophylactic dose LMWH (eg, tinzaparin, enoxaparin,) or a DOC (eg, rivaroxaban) [9]. In ICU hospitalized COVID-19 patients who develop VTE, LMWH may be considered as the standard care at proper therapeutic dosage, especially in patients with high inflammatory activity, persistent immobility, and/or additional risk factors. For patients with severe renal inefficiency, intact heparin should be administered [1]. A 3- to 6-month anticoagulation course is recommended for VTE. Most clinicians agree that prophylaxis should be administered until the patient finish his/her hospital stay, however, there is no tangible agreement for extended prophylaxis post-discharge [29,30,37].

Non-pharmacologic approaches

In case of contraindications for anticoagulation or as non-pharmacologic approaches should include thrombo-prophylactic stockings, calf compression pumps (as physical measures), mechanical compression devices, and electrical neuromuscular stimulation devices. Compression stockings prevent venous stasis by a mechanical operation in the non-anesthetized or non-paralyzed patient. Venous flow induced by habitual or involuntary muscle movement is amplified by the external compressive counterforce [5]. As a result of therapeutic enoxaparin treatment in some randomized trials, patients with severe COVID-19 respiratory failure had decreased D-dimer levels, improved gas exchange, and were liberated from mechanical ventilation with a higher rate of success. [32]. Recent experimental models indicated that LMWH could diminish acute lung injury (ALI) [32].

Should we use ASA?

The potent anti-inflammatory effects of Acetylsalicylic acid (ASA) have been exploited in clinical practice [33]. It has also antiviral activity against RNA and DNA viruses as well as antithrombotic effects [33]. The anti-inflammatory effects of ASA mainly as a non-selective inhibitor of cyclo-oxygenase (COX-1 and COX-2) pathways, which are important mediators of inflammation, including PGs and thromboxane A2 (TXA2), jointly called prostanoids [33]. ASA irreversibly prevents platelet cyclooxygenase, and its effect is persistent for 7–10 days in the circulating platelets making the drug controversial in COVID-19 patients [38]. Based on the aforementioned evidence as well as the other randomized clinical trials, small doses of ASA are presently used for preventing aggregation of platelet and avert the ischemic arterial occasions (e.g., stroke, myocardial infarction) in patients at higher thrombotic risk [33].

The use of ASA has been studied in patients with COVID-19 for the past year. Although still very controversial, we are beginning to see a trend in the studies carried out so far. In a recent systematic review of the literature with meta-analysis with 13993 patients, Martha et al suggest that the use of low dose ASA is independently

associated with reduced mortality in patient COVID-19 [34]. In another systematic review including a larger number of patients (56,696), it was concluded that there seems to be a lower probability of death from COVID-19 in patients in the ASA group, but when the outliers are excluded, this effect was not verified [23]. The most relevant study due to its design, the number of participants involved, and the homogeneity of the study groups is an investigator-initiated, individually randomized, controlled, open-label, platform trial, involving several hospitals in the United Kingdom [35]. In the group that analyzed the effects of ASA, more than 14,000 patients were included, and the authors conclude that the use of ASA was not associated with reduced mortality or less progression to invasive mechanical ventilation or death among non-ventilated patients at admission; the only potential effect of ASA use appears to be a marginally increased rate of discharge alive within 28 days. The authors report a lower rate of thrombotic events, but also a higher rate of bleeding events in the ASA group, as expected. As an explanation for the lack of significant benefit in the use of ASA, the authors put forward the fact that patients are already under LMWH in therapeutic doses and corticosteroids, and ASA may not add benefit to these treatments [35]. From the evidence presented by the studies, we can conclude that, despite the still great controversy about the issue, the use of ASA does not seem to have a significant effect in reducing mortality or the need for invasive mechanical ventilation among patients hospitalized with COVID-19 [35]. Regarding patients with mild COVID-19, there are still no studies about ASA in ambulatory use.

Conclusions

The COVID-19 pandemic has affected the normal therapeutic approach and disease management. Clinicians are confronted with a virus behavior abnormal and continue their struggle to tackle the agent [3]. COVID-19 infection is known by the variable phenotypic expressions that involve a systemic disease commonly linked with endothelial dysfunction and coagulopathy.

CAC looks like HPS/HLH, SIC/DIC, TTP/ HUS, and APS in some issues but has unique features that may be defined as a new group of coagulopathies. It has been recognized that several parameters are involved in the establishment of CAC; hence additional understanding of the mechanism and pathophysiology is required for efficient management of the disease. An increase in D-dimer reflects activation of both fibrinolysis and coagulation *in-vivo* [6]. Current reports indicated that raised D-dimer, which may reflect the cytokine storm and hyperinflammatory state that leads to thrombo- inflammation, is a strong predictor of thrombosis and mortality in patients with COVID-19 [39,40]. The status of D-dimer may help clinicians for early recognition of these high-risk patients and predict outcomes. Preliminary data indicated that anticoagulant therapy appears to be very crucial in lowering mortality in severe COVID-19 patients [11].

Although, signal associated with thrombotic risk with COVID-19 infections needs additional data to shed light on the risk factors and incidence of thrombotic occasions in these patients, as well as the best prophylaxis approach [24]. Complete registration of

patients and observational cohorts are needed for non-severely ill inpatients and a follow-up after hospital discharge [24].

Current studies indicated that TE occurs frequently during the post-discharge period. Key predictors include cardiovascular risk factors, advanced age, CKD, ICU stay. Although consumptive coagulopathy, sepsis physiology, and D-dimer are indicators of mortality, and present data do not recommend the use of full-intensity anticoagulation doses unless otherwise clinically designated [3]. LMWH, prophylactic doses of anticoagulants or DOAC reduce the risk of major thromboembolic events and death [21,37]. Overall, pharmacological VTE prophylaxis should be given to hospitalized COVID-19 patients unless contraindications exist.

Acknowledgments

The authors express their deep sense of gratitude to Prof. Dr. Eufêmia Calmeiro for encouraging them to do this clinical research review.

References

1. Langer F, Kluge S, Klamroth R, et al. Coagulopathy in COVID-19 and Its Implication for Safe and Efficacious Thromboprophylaxis. *Hamostaseologie*. 2020; 40: 264-269.
2. Jayarangaiah A, Kariyanna PT, Chen X, et al. Review COVID-19-Associated Coagulopathy: An Exacerbated Immunothrombosis Response. *Clin Appl Thromb Hemost*. 2020; 26.
3. Connors JM, Levy JH. COVID-19 and its implications for thrombosis and coagulation. *Blood*. 2020. 135: 2033-2038.
4. Goshua G, Pine AB, Meizlish ML, et al. Endotheliopathy in COVID-19-associated coagulopathy: evidence from a single-centre, cross-sectional study. *Lancet Haematol*. 2020; 7: e575-e-582.
5. Kipshidze N, Dangas G, White GJ, et al. Viral Coagulopathy in Patients With COVID-19: Treatment and Care. *Clin Appl Thromb Hemost*. 2020; 26.
6. Bhaskar S, Sinha A, Banach M, et al. Cytokine Storm in COVID-19-Immunopathological Mechanisms, Clinical Considerations, and Therapeutic Approaches: The REPROGRAM Consortium Position Paper. *Front. Immunol*. 2020; 11: 1648.
7. Kollias A, Kyriakoulis KG, Dimakakos E, et al. Thromboembolic risk and anticoagulant therapy in COVID-19 patients: emerging evidence and call for action. *Br J Haematolog*. 2020; 189: 846-847.
8. Asakura H, Ogawa H. COVID-19-associated coagulopathy and disseminated intravascular coagulation. *Int J Hematol*. 2021; 113: 45-47.
9. Spyropoulos A, Levy J, Ageno W, et al. Scientific and Standardization Committee communication: Clinical guidance on the diagnosis, prevention, and treatment of venous thromboembolism in hospitalized patients with COVID-19. *J Thromb Haemost*. 2020; 18: 1859-1865.
10. Abou-Ismaïl M, Diamond A, Kapoor S, et al. The hypercoagulable state in COVID-19: Incidence, pathophysiology, and management. *Thrombosis Research*. 2020. 194; 101-115.
11. Aryal M, Gosain R, Donato A, et al. Venous Thromboembolism in COVID-19: Towards an Ideal Approach to Thromboprophylaxis, Screening, and Treatment. *Curr Cardiol Resp*. 2020; 22: 52.
12. Bonaventura A, Vecchié A, Dagna L, et al. Endothelial dysfunction and immunothrombosis as key pathogenic mechanisms in COVID-19. *Nat Rev Immunol*. 2021; 21: 319-329.
13. Evans P, Rainger G, Mason J, et al. Endothelial dysfunction in COVID-19: a position paper of the ESC Working Group for Atherosclerosis and Vascular Biology, and the ESC Council of Basic Cardiovascular Science. *Cardiovascular Research*. 2020; 116: 2177-2184.
14. Jin Y, Ji W, Yang H, et al. Endothelial activation and dysfunction in COVID-19: from basic mechanisms to potential therapeutic approaches. *Sig Transduct Target Ther*. 2020; 5: 293.
15. Herter JM, Rossaint J, Zarbock A. Platelets in inflammation and immunity. *J Thromb Haemost*. 2014; 12: 1764-1775.
16. Hille L, Lenz M, Vlachos A, et al. Ultrastructural, transcriptional, and functional differences between human reticulated and non-reticulated platelets. *J Thromb Haemost*. 2020; 18: 2034-2046
17. Wool GD, Miller J. The Impact of COVID-19 Disease on Platelets and Coagulation. *Pathobiology*. 2021; 88: 15-27.
18. Thachil J, Tang N, Gando S, et al. ISTH interim guidance on recognition and management of coagulopathy in COVID-19. *J Thromb Haemost*. 2020; 18: 1023-1026.
19. Mucha S, Bartholomew J, Dugar S, et al. Coagulopathy in COVID-19: manifestations and management. *Cleve Clin J Med*. 2020; 87: 461-468.
20. Chan N, Jeffrey I. COVID-19 coagulopathy, thrombosis, and bleeding. *Blood*. 2020; 136: 381-383.
21. Al-Ani F, Chehade S, Lazo-Langer A. Thrombosis risk associated with COVID-19 infection. A scoping review. *Thrombosis research*. 2020; 192: 153-160.
22. Martha JW, Pranata R, Lim MA, et al. Active prescription of low-dose aspirin during or prior to hospitalization and mortality in COVID-19: A systematic review and meta-analysis of adjusted effect estimates. *Int J Infect Dis*. 2021; 108: 6-12.
23. Tal S, Spectre G, Kornowski R, et al. Venous Thromboembolism Complicated with COVID-19: What Do We Know So Far? *Acta Haematol*. 2020; 143: 417-424.
24. Guan W, Ni Z, Hu Y, et al. China medical treatment expert group for Covid-19. Clinical characteristics of coronavirus disease. *N Engl J Med*. 2019; 382: 1708-1720.
25. Zhou F, Yu T, Du R, et al. Clinical course, and risk factors for mortality of adult inpatients with COVID-19 in Wuhan, China: a retrospective cohort study. *Lancet*. 2020; 395: 1054-1062.

-
26. Cui S, Chen S, Li X, et al. Prevalence of venous thromboembolism in patients with severe novel coronavirus pneumonia. *Journal of Thromb and Haemost*. 2020. 18: 1421-1424.
 27. Hippensteel JA, LaRiviere WB, Colbert JF, et al. Heparin as a therapy for COVID-19: current evidence and future possibilities. *Am J Physiol Lung Cell Mol Physiol*. 2020; 319: L211-L217.
 28. Marchandot B, Trimaille A, Curtiaud A, et al. Thromboprophylaxis: balancing evidence and experience during the COVID 19 pandemic. *J Thromb Thrombolysis*. 2020; 50: 99-808.
 29. Manolis AS, Manolis T, Manolis AA, et al. COVID-19 Infection: Viral Macro and Micro-Vascular Coagulopathy and Thromboembolism/Prophylactic and Therapeutic Management. *J Cardiovasc Pharmacol Ther*. 2021. 26: 12-24.
 30. Giannis D, Allen S, Tsang J, et al. Post discharge thromboembolic outcomes and mortality of hospitalized patients with COVID-19: the CORE-19 registry. *Thrombosis and Hemostasis*. Blood. 2021; 137: 2838-2847.
 31. Warkentin T, Kaatz S. COVID-19 versus HIT hypercoagulability. *Thromb Res*. 2020; 196: 38-56.
 32. Lemos TA, Espírito Santo D, Salvetti MC, et al. Therapeutic versus prophylactic anticoagulation for severe COVID-19: A randomized phase II clinical trial (HESACOVID). *Thromb Res*. 2020; 196: 359-366.
 33. Mohamed-Hussein A, Aly K, Ibrahim ME. Should aspirin be used for prophylaxis of COVID-19-induced coagulopathy? *Med Hypotheses*. 2020; 144: 109975.
 34. Srivastava, R, Kumar, A. Use of aspirin in reduction of mortality of COVID-19 patients: A metanalysis. *Int J Clin Pract*. 2021; 75: e14515.
 35. Ponti G, Maccaferri M, Ruini C, et al. Biomarkers associated with COVID-19 disease progression. *Cri Rev Clin Lab Sci*. 2020; 57: 383-399.
 36. Giannis D, Allen S, Tsang J, et al. Post discharge thromboembolic outcomes and mortality of hospitalized patients with COVID-19: the CORE-19 registry. *Thrombosis and Hemostasis*. Blood. 2021; 137: 2838-2847.
 37. Bianconi V, Francesco Violi F, et al. Is Acetylsalicylic Acid a Safe and Potentially Useful Choice for Adult Patients with COVID-19? *Drugs*. 2020; 80: 1383-1396.
 38. Horby P, Pessoa-Amorim G, Staplin N, et al. Aspirin in patients admitted to hospital with COVID-19 (RECOVERY): a randomised, controlled, open-label, platform trial. *medRxiv*. 2021.
 39. Cuker A, Tseng E, Nieuwlaat R, et al. American Society of Hematology 2021 guidelines on the use of anticoagulation for thromboprophylaxis in patients with COVID-19. *Blood advances*. 2021. 5: 275-693.