

Decrease in Side Effects Rate after Adopting Bloodless Atraumatic Technique (BAT) - A Single Cosmetic Surgery Center Experience of 360 Lip Injections Over One Year

Sergio Noviello MD, FAACS*, Andrea De Santis MD, Andrea Maroni MD, Massimiliano Tocchio MD, Gualtiero Cogliandro MD and Nicola Di Benedetto MD

Academy and Milano Estetica - Cosmetic Surgery Centre, Via Borgospesso 18 20121 Milano, Italy.

*Correspondence:

Sergio Noviello, MD, Academy and Milano Estetica - Cosmetic Surgery Centre, Via Borgospesso 18 20121 Milano, Italy. E-mail sergio.noviello@simoe.it.

Received: 02 August 2018; Accepted: 25 August 2018

Citation: Sergio Noviello, Andrea De Santis, Andrea Maroni, et al. Decrease in Side Effects Rate after Adopting Bloodless Atraumatic Technique (BAT) - A Single Cosmetic Surgery Center Experience of 360 Lip Injections Over One Year. J Med - Clin Res & Rev. 2018; 2(4): 1-9.

ABSTRACT

Introduction: The most popular non-surgical procedures continue to be injectables with hyaluronic acid ranking at number two, including lip augmentation which is gaining in interest and represents a large portion of cosmetic medicine practice in recent years. Although it is considered a simple technique, we often observe poor quality results. Many Authors in the literature have published the rate of side effects like pain, post treatment discomfort, bruising, swelling and asymmetries in lip injection with hyaluronic acid considered common or very common in their experience. A cosmetic improvement of the lips involves many precautionary considerations. In this study we examine our single accredited outpatient cosmetic medicine and surgery center experience transitioning from the use of traditional injection technique to the use of Bloodless Atraumatic Technique (BAT).

Methods: We performed a retrospective analysis of all lip injection cases performed over a 1-year period from January 2017 to December 2017 by multiple physicians and surgeons in the practice. During the 1-year period, there were 360 lip enhancement with filler performed by three attending doctors. Post-treatment follow-up length and complications including swelling, bruising, long lasting edema (more than 14 days), infection, seroma, granuloma, skin necrosis and need for revision were noted.

Results: Three of the most interesting findings were a significantly decreased pain level and discomfort, bruising and swelling in the BAT group (258 patients) where no pain occurred in 43.02%, light pain in 42.24%, moderate pain in 14.72%, intense or serious pain in 0%. Whereas serious pain occurred in the Traditional Infiltration Technique (TIT) group (102 patients) in 25.49%, intense pain in 68.62%, moderate pain in 5.88%, light or no pain in 0%. We found in the BAT group that bruising occurred in 3.87% vs 25.49% in the TIT group and swelling in 4.65% vs 29.41%. Other sensitive element was the decrease rate of long lasting edema (more than 14 days) with 0.77% in the BAT patients and 5.88% in the TIT group.

Discussion: Pain level and discomfort in the Bloodless Atraumatic Technique Lip Injection Group were much lighter than that in the Traditional Infiltration Technique Group, which demonstrated that BAT significantly reduced post treatment pain and discomfort. Improvement of facial harmony requires a strong knowledge of the anatomy. Most lip injections are performed without a clear understanding of the underlying oral and perioral anatomy.

Conclusions: The Bloodless Atraumatic Technique allows to enhance the lip with control and precision without violating important and sensitive anatomical structure like mucosa, labial arteries and orbicularis oris muscle which reduces pain, postoperative discomfort, swelling, bruising, long lasting edema and the possibility of infection. Bloodless Atraumatic Technique Lip Injection offers objective improvements in side effects and complications, recovery and the overall patient experience, but do not happen in a predictable manner without substantial commitment of the medical staff and effort primarily of the aesthetic physician.

Keywords

Lip injection, Hyaluronic Acid, Bloodless Atraumatic Technique.

Introduction

The International Society of Aesthetic Plastic Surgery (ISAPS) in August 2017 released the results of their annual Global Aesthetic Survey [1] for procedures completed in 2016, which showed an overall increase of 9% in surgical and non-surgical cosmetic procedures within the past twelve months. The top five countries – USA, Brazil, Japan, Italy and Mexico – account for 41.4% of the world's cosmetic procedures, followed by Russia, India, Turkey, Germany and France. The most popular non-surgical procedures continue to be injectables with hyaluronic acid ranking at number two (a total 7% increase over the past 12 months), including lip augmentation which is gaining in interest and represents a large portion of cosmetic medicine practice in recent years. Although it is considered a simple technique, we often observe poor quality results. An aesthetic improvement of the lips involves many precautionary considerations. Contour and shape are frequently effective more than lip augmentation alone. We should focus on enhancement and not inevitably on increase in size, establishing a procedure based strictly on anatomy and harmony in order to determine the cosmetic necessity and the suitable solution. Patient examination is mandatory and should involve assessing superior and inferior labial units, shape, contour, projection, volume, support, asymmetries, patient's smile and facial ageing (Figure 1).




Figure 1: The ideal female lips.

Many Authors [2-6] in the literature have published the rate of side effects like pain, post treatment discomfort, bruising, swelling and asymmetries in lip injection with hyaluronic acid considered common or very common in their experience. Despite mounting evidence that classical technique in lip injection may actually have higher side effects rates, many physicians and many surgeons are reluctant to change their practice to adopting a procedure that can lower or totally eliminate this risk.

In June 2016 and March 2018, after more than a decade of work refining all of the processes, materials and techniques of lip injections, the senior Author presented two lectures, in two

respected professional congress in cosmetic medicine and surgery, the International Congress of the World Academy of Cosmetic Surgery (WAOCS) in Velden (Austria), and the European Congress of Aesthetic and LASER Medicine in Moscow (Russia). These lectures represented one scientifically confirmed methodology that enabled 96% of 258 consecutive patients to enhance the contour and the shape of their lips without any short and long term side effect. The Authors first reported in the literature the use of the Bloodless Atraumatic Technique (BAT) [7] in surgery since then many have been interested in comparisons and outcomes with this technique. In their paper in 2016 with 186 facelift cases, S. Noviello et al. reported a hematoma rate of 0% and overall local complications of 2,6% in facelift surgery. Surek CC et al., have noted decreased side effects rate after converting from classical injection technique to a traumatic technique [8].

Given the mounting evidence that the use of BAT is predictable, safe and could reduce our complications rate, we decided to implement the procedure in all injections in our private practice in Milan, Italy. In this study we examine our single accredited outpatient cosmetic medicine and surgery center experience transitioning from the use of traditional injection technique to the use of BAT.

Material and Methods

We performed a retrospective analysis of all lip injection cases performed over a 1-year period from January 2017 to December 2017 by multiple physicians and surgeons in the practice. It should be noted that during the study physicians and surgeons adopted the BAT technique; however, one continued the use of classical technique.

During the 1-year period, there were 360 lip enhancement with filler performed by three attending doctors. There was a gradual transition from the two techniques beginning in January when one of the surgeons began utilizing the BAT technique. Over the course of the next months, the overwhelming majority of the lip infiltration being performed in the practice were utilizing the BAT technique. In the final study a total of 360 patients were included. Overall, there were 258 patients with BAT and 102 with traditional injection technique (TIT).

Patient demographic information was obtained from the chart, including age, gender, and body mass index (BMI). Post-treatment follow-up length and complications including swelling, bruising, long lasting edema (more than 14 days), infection, seroma, granuloma, skin necrosis and need for revision were noted.

The study was conducted in accordance with the guidelines of the Declaration of Helsinki and prior written consent was obtained from all of the patients who participated in this study.

How to achieve a BAT lip injection?

In a predictable manner delivering BAT lip injection results need that physicians and surgeons read carefully, practice cautiously, and implement closely all of the procedures that have been described

and identified [9-12]. Many doctors implement and adopt some of the methods, but prefer not to follow the entire process described. Evidence clearly shows that not implementing all of the identified processes results in a failure to deliver this level of enhancement.

Patient examination and markings

Traditional injection techniques are often linked to long lasting swelling, bruising and asymmetry. Bloodless Atraumatic Technique consists of a schematic lip analysis combined with an infiltration technique that do not traumatize the relevant anatomical structures of the lips.

The nasolabial folds, the philtral columns, Cupid's bow, outer edge of the vermillion, vermillion segments, inner edge of the vermillion (everting the lip simplifies the identification) are identified and marked with a white make-up pencil.

Anatomy

The upper lip extends from the base of the nose superiorly to the nasolabial folds laterally and to the free edge of the vermillion border inferiorly. The lower lip extends from the superior free vermillion edge superiorly, to the commissures laterally, and to the mandible inferiorly. Along the upper vermillion-skin border, two small areas of elevation of the vermillion form the Cupid's bow. Two raised vertical columns of tissue form a midline groove called the philtrum. The philtrum is located between the Cupid's Bow and the columella above. The labiomental crease passes horizontally in an inverted U-shape across the lower lip, which intraorally corresponds to the depth of the gingivolabial sulcus (Figure 2).

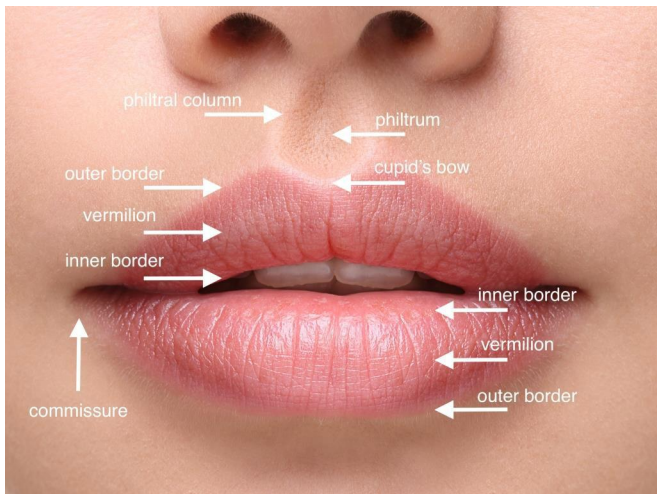


Figure 2: Superficial anatomy of the lips and landmarks.

From superficial to deep, the layers of the upper and lower lips include the epidermis, subcutaneous tissue, orbicularis oris muscle fibers, and intraorally the mucosa, submucosal and muscle [13] (Figure 3).

Understanding the precise position and course of the superior and inferior labial arteries within the upper lip and the lower lip is crucial for safe and complication-free applications of volumizing materials [9]. In the manuscript of Cotofana S. et al. three different

positions of the superior and inferior labial arteries were identified: submucosal (i.e., between the oral mucosa and the orbicularis oris muscle in 78.1 percent of the cases), intramuscular (i.e., between the superficial and deep layers of the orbicularis oris muscle in 17.5 percent of the cases), and subcutaneous (i.e., between the skin and the orbicularis oris muscle in 2.1 percent of the cases) (Figure 4).

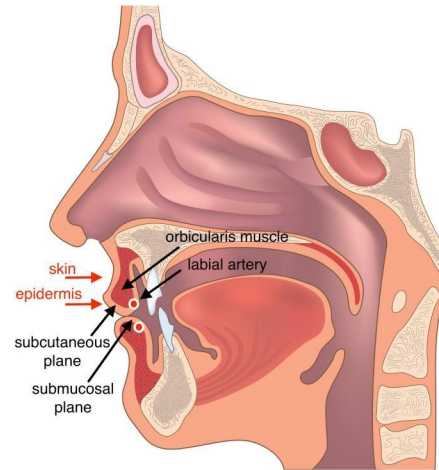


Figure 3: Anatomy of the lips sagittal view.

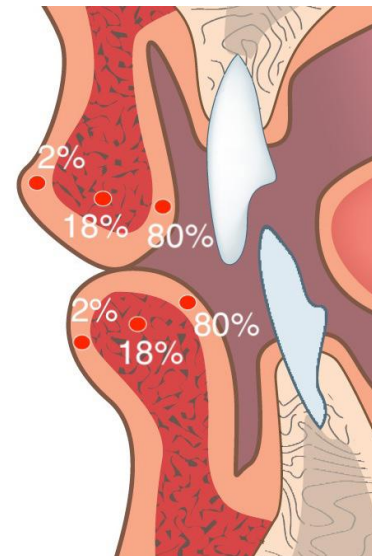


Figure 4: Position and course of the superior and inferior labial arteries.

A safer location for the application of volumizing material is the superficial subcutaneous plane in the paramedian location of both the upper lip and the lower lip. Care has to be taken when aiming to inject in the midline, as the artery can be identified more frequently in superficial positions.

The superior and inferior labial arteries course between the orbicularis muscle fibers and the mucosa.

Blood supply to both lips starts from the external carotid system. The facial artery ascends from the neck over the midbody of the mandible just anterior to the insertion of the masseter muscle. The facial artery branches into the submental artery that passes under

the mandibular body in an anteromedial direction. The facial artery ascends in a plane deep to the platysma, risorius, and zygomaticus major and minor muscles and superficial to the buccinator and levator anguli oris. This artery branches into an inferior and a superior labial artery, which course beneath the orbicularis oris and anastomose with the contralateral vessel (Figure 5).

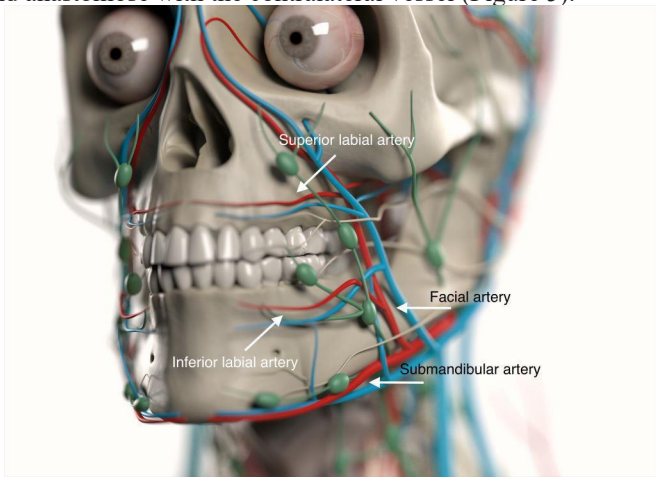


Figure 5: Vascular anatomy of the lips.

Technique of injecting is really important, and requires basic knowledge of anatomy of the lips, surrounding structures, and adequate medical devices. The final goal must be lip enhancement and not only pure augmentation.

There are harmony rules [14-16], which can support us to get the ideal lips position and projection. In general, the distance between the oral commissures should be equal to the medial border of the iris lines. The width of the lips equals 1.5 times the width of the nose at the alar base (Figure 6).




Figure 6: Width of the lips. The distance between the oral commissures should be equal to the medial border of the iris lines. The width of the lips equals 1.5 times the width of the nose at the alar base.

There are other mathematical aspects that dictate the appearance of beauty in the perioral region. Dental show on repose should be

1 to 2 mm only. The ideal width of beautiful lips should be 57 to 62 mm. The Steiner line is particularly useful and should touch the upper lip, lower lip, chin projection, and base of the columella. The Ricketts line offers important information on lip projection. On lateral view, the upper lip should project 1 to 2 mm forward from the lower lip (Figure 7) and the upper lip should fall 4 mm posterior to the nasomental line while the lower lip should fall 2 mm posterior to the nasomental line (Figure 8).

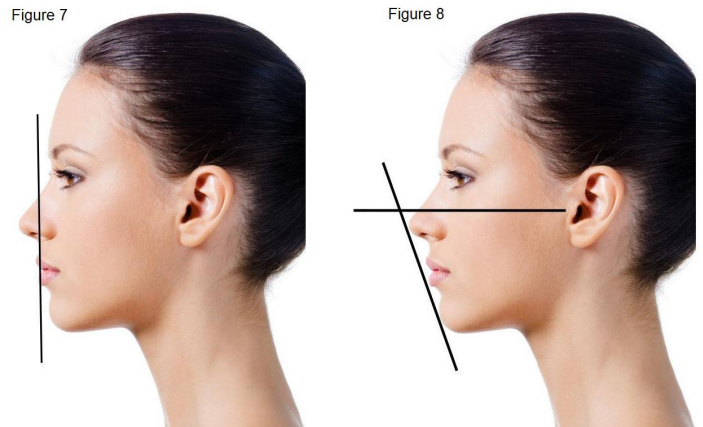


Figure 7: The upper lip should project 1 to 2 mm forward from the lower lip.

Figure 8: The upper lip should fall 4 mm posterior to the nasomental line while the lower lip should fall 2 mm posterior to the nasomental line. Ideal projection described by Ricketts.

Lip assessment

The static aspects of the lips and perioral area should be assessed first. In that checking we observe: lips, corners of the mouth, definition of the vermilion border, Cupid's bow, and philtrum columns. On lateral view, there also are several lines that may be used to estimate lip alignment. Steiner and Ricketts lines indicate the ideal relationship between the nose, upper and lower lips, and chin.



Figure 9: Smile assessment and lip volume evaluation - ideal lines.

Smile assessment is crucial for smile aesthetics and lip volume evaluation, including whether a gummy smile is present; whether the smile subtype is mainly lateral, central, or mixed; whether the

smile is asymmetrical or if there is loss of lip show on smiling. To determine volume patient's aesthetic need crucial attention is given to the patient's incisors show and gingival line when the patient smile without straining the muscle: the superior ideal line should run along the gingiva while the inferior ideal line should run along the inferior border of the incisors as suggested by Surek CC et al. in their paper [8] (Figure 9). In case of excessive gingival show in the upper half of the smile or excessive dental show in the lower half, increasing the volume could be an enhancing option towards harmony.

Technical process and materials

Medical injection technique and materials have been refined and selected to reduce all kind of trauma to lip tissues, and to virtually eliminate bleeding and blood soaking into tissues, causing pain, swelling and inflammation and increasing risks of complications. Implementing detailed medical methods and products allow to reach an atraumatic enhancement. The doctor has the possibility to inject the lips for adequate contour, projection, volume, shape and support while preventing over 99% of bleeding that would normally occur with traditional strategies [17,18]. where less importance is given to technique in term of anatomy, planes of injection, modality of infiltration, materials and instrumentations.

Implementing detailed medical infiltration techniques based on anatomy and materials allow dramatic reduction of trauma to tissues, bruising, pain and swelling [19-21]. The favorable reduction in tissue trauma and bleeding using the processes, the techniques and the materials described results in decrease in pain, edema and ecchymosis, and return to normal activities within 1 to 2 hours.

Anesthesia protocols

Only rigid adherence to fixed and defined technique of local anesthesia, employing products and materials elected appositely and developed to reduce trauma (i.e. topical gel instead of needle as in traditional technique) allow BAT lip injection. Topical gel made of Lidocaine 20%, Prilocaine 5%, Tetracaine 5% is placed over the vermilion segments and vestibular mucosa.

The time of effect is very rapid, between five and seven minutes. Cold compresses are placed on the upper and lower lip in order to reach local vasoconstriction.



Figure 10: Topical anesthetic gel.

Infiltration technique

Injections of hyaluronic acid are placed beginning at the oral commissures, from lateral to medial on the vermilion or directly in the perioral area. These infiltrations could be performed at the cutaneous junction between the outer border of the vermilion and the perioral skin in case of lip profile enhancement, directly on the vermilion along its length at three locations in the upper lip and two locations in the lower lip in case of lip projection enhancement or injecting on the vermilion but directing the point of the needle toward the wet mucosa surpassing the inner border of the vermilion in case of lip augmentation.

In the traditional infiltration technique (TIT) the lips are considered an entire body to be injected unconcerning of infiltration levels, anatomical structures as muscles or vessels, precise landmarks, precise patient's aesthetic needs and volume of injection. In this serie the product used has been cross-linked sodium hyaluronate gel (25.5 mg/ml and 22.5 mg/ml) with lidocaine hydrochloride (3.0 mg/ml), sterile, non-pyrogenic, viscoelastic, colourless, transparent of non-animal origin in a physiological phosphate buffer.

We suggest to identify five essential key elements (5K) for lip enhancement based on the patient's aesthetic need.

The first key element is the definition of the outer border of the vermilion, the connection between the skin and dry mucosa, which determines lip profile.

The second key element is the vermilion delimited by the outer and the inner border, which determines lip projection.

The third essential key element is the inner border of the vermilion, the connection between the dry and wet mucosa, which determines lip augmentation.

The fourth key element is the shape of the lips in terms of harmony of the corners of the mouth.

The fifth key element is the structural support of the perioral area (Figure 8).

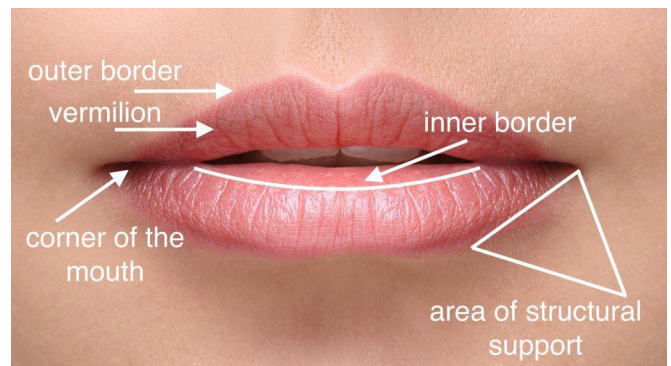


Figure 11: Five essential key elements (5K) for lip enhancement.

Lip Profile

A well-defined lip contour is an important feature to be achieved when injecting the mouth. Ageing lips more often present flat

borders, but young lips also could be characterized by poor-defined profile.

Retrograde infiltration is performed just beneath the outer border of the upper and lower lip, infiltrating progressively toward the midline in three segments in the upper lip (0.05 - 0.1 ml each) and in two segments in the lower lip (0.05 - 0.1 ml each), starting 5 mm medially from the commissures (Figure. 12).



Figure 12: Lip profile enhancement. Retrograde infiltration is performed just beneath the outer border of the upper and lower lip, infiltrating progressively toward the midline in three segments in the upper lip and in two segments in the lower lip.

Lip Projection

To enhance projection of the upper and lower lip, the needle is passed very superficial into the vermilion directly between the outer and the inner border, paying attention at the minimal contraction of the orbicularis muscle. If the muscle contracts it means that we are too deep, we are in the muscle that we do not want to violate. Boluses are infiltrated progressively toward the midline throughout the three segments of the upper lip (0.05 - 0.1 ml each) and the two segments of the lower lip (0.05 - 0.1 ml each), between the outer and the inner border of the vermilion, starting 5 mm medially from the commissures.

The expansion of the vermilion is controlled and each hemilip is compared for symmetry (Figure 13).

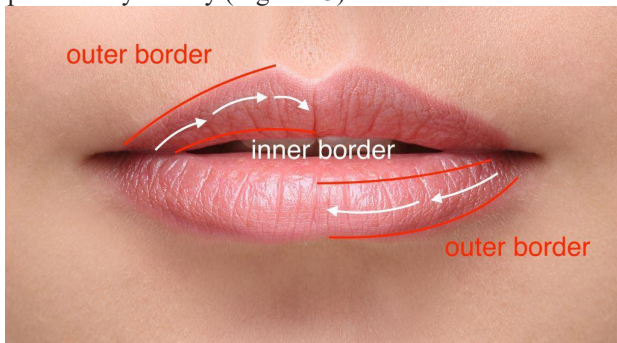


Figure 13: Lip Projection enhancement. Boluses are infiltrated progressively toward the midline throughout the three segments of the upper lip and the two segments of the lower lip, between the outer and the inner border of the vermilion.

Lip Augmentation

To enhance volume of the upper and lower lip the needle is passed very superficial into the vermilion directly passing beyond the

inner border of the vermilion, paying attention at the minimal contraction of the orbicularis muscle again. As highlighted before understanding the precise position and course of the superior and inferior labial arteries within the upper lip and the lower lip is crucial for safe and complication-free applications of volumizing materials [9]. Boluses are infiltrated beneath the wet vermilion progressively toward the midline throughout the three segments of the upper lip (0.05 - 0.1 ml each) and the two segments of the lower lip (0.05 - 0.1 ml each), injecting very superficial into the vermilion directly passing beyond the inner border of the vermilion, starting 5 mm medially from the commissures.

The expansion of the wet mucosa is controlled and each hemilip is compared for symmetry (Figure 14).

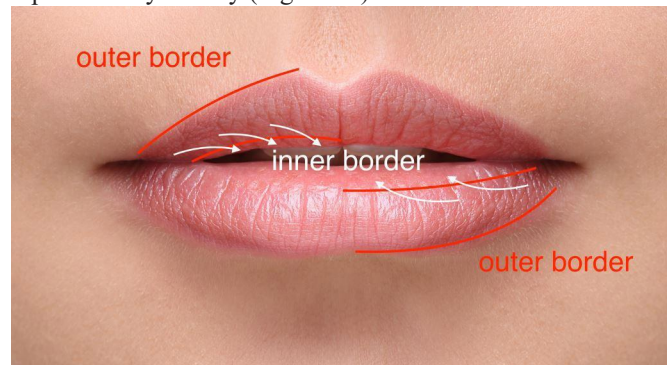


Figure 14: Lip volume enhancement. Boluses are infiltrated beneath the wet vermilion progressively toward the midline throughout the three segments of the upper lip and the two segments of the lower lip, injecting very superficial into the vermilion directly passing beyond the inner border of the vermilion.

Lip Shape

Ageing lips more often present corners of the mouth looking downward, but young lips also could be characterized by this condition. To enhance the shape of the lips, in terms of harmony of the corners of the mouth, retrograde infiltration is performed just beneath the outer border of the upper and lower lip (0.05 - 0.1 ml each), infiltrating progressively toward the midline starting directly from the commissures. If the area need more traction, injecting vertically at the commissure's level can improve lip shape. Sometimes lips need lateral volume too, at the corners. The expansion of the corners is controlled and each hemilip is compared for symmetry (Figure 15).

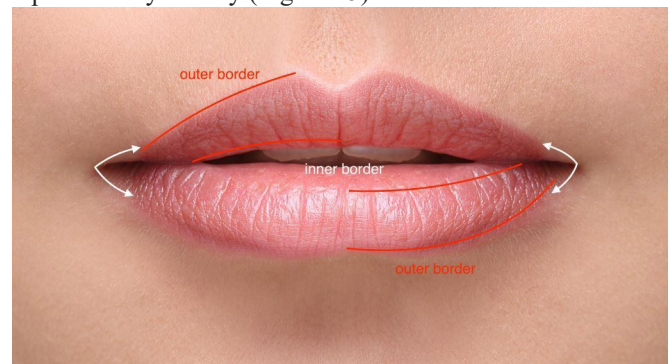


Figure 15: Lip shape enhancement (corners of the mouth). Retrograde

infiltration is performed just beneath the outer border of the upper and lower lip, infiltrating progressively toward the midline starting directly from the commissures.

Lip Support

Ideal lips present optimal support in the perioral area, above all in the lower lateral regions (triangular shape). To enhance lip support the needle is passed superficial starting 1 cm lateral to each commissure in a fanning pattern outside the vermilion. Two - four boluses are infiltrated throughout the triangle in a superficial subcutaneous plane (0.05 - 0.1 ml each). The expansion of the area is controlled and each hemitriangle is compared for symmetry (Figure 16).

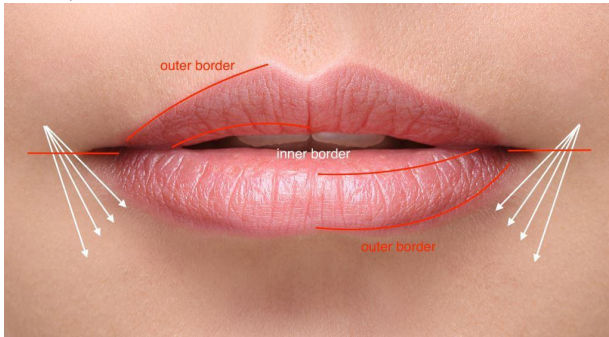


Figure 16: Enhancement lip structural support. Two - four boluses are infiltrated throughout the triangle in a superficial subcutaneous plane.



Figure 17: Pre treatment and post treatment of lip injection enhancement.

Results

The demographics (Table 1) of the groups showed similar age with a mean BAT patient age of 43.5 years (range 23-64 years) and a mean TIT patient of 39.5 years (range 20-59 years). These first datas show that although it is considered a rejuvenating technique, we often observe interest in lip enhancement in younger women. There were also similarities in mean BMI BAT 20.75 (range 19-22.5) and in mean BMI TIT 21.5 (range 20-23). Average follow-up time BAT was 9 months (range 3 to 15 months) and TIT was 10.5 months (range 6 to 15 months).

	BAT	TIT
Number of Patients	258	102
Mean Age (years)	43.5 years (range 23-64 years)	39.5 years (range 20-59 years)
Mean BMI (Kg/m ²)	20.75 (range 19-22.5)	21.5 (range 20-23)
Average follow-up time	9 months (range 3-15)	10.5 months (range 6-15)

Table 1: Patient Demographics.

Nine main end points were examined in the BAT vs TIT groups. These included pain level and discomfort, bruising, swelling, seroma, long lasting edema, infection, granuloma, need for revision surgery, and skin necrosis (Table 2).

The patient's assessment of lip injection pain was graded on a five-point scale as follows: serious pain, intense pain, moderate pain, light pain and no pain. Three of the most interesting findings were a significantly decreased pain level and discomfort, bruising and swelling in the BAT group (258 patients) where no pain occurred in 43.02%, light pain in 42.24%, moderate pain in 14.72%, intense or serious pain in 0%. Whereas serious pain occurred in the TIT group (102 patients) in 25.49%, intense pain in 68.62%, moderate pain in 5.88%, light or no pain in 0%.

	BAT	TIT
Number of Patients	258	102
No Pain	111 (43.02%)	0 (0%)
Light Pain	109 (42.24%)	0 (0%)
Moderate Pain	38 (14.72%)	6 (5.88%)
Intense Pain	0 (0%)	70 (68.62%)
Serious Pain	0 (0%)	26 (25.49%)

Table 2: Pain Level Rates.

We found in the BAT group that bruising occurred in 3.87% vs 25.49% in the TIT group and swelling in 4.65% vs 29.41%. Other sensitive element was the decrease rate of long lasting edema (more than 14 days) with 0.77% in the BAT patients and 5.88% in the TIT group.

Seroma, infection, granuloma, need for revision and skin necrosis were similar between groups and were not significant.

	BAT	TIT
Number of Patients	258	102
Bruising	10 (3.87%)	26 (25.49%)
Swelling	12 (4.65%)	30 (29.41%)
Seroma	0 (0%)	0 (0%)
Long Lasting Edema	2 (0.77%)	6 (5.88%)
Infection	0 (0%)	0 (0%)
Granuloma	0 (0%)	0 (0%)
Need for Revision	1 (0.38%)	5 (4.90%)
Skin Necrosis	0 (0%)	0 (0%)

Table 3: Complication Rates for the Different Groups.

Discussion

Pain level and discomfort in the Bloodless Atraumatic Technique Lip Injection Group were much lighter than that in the Traditional Infiltration Technique Group, which demonstrated that BAT significantly reduced post treatment pain and discomfort.

Several key articles have presented support for the Bloodless Atraumatic Technique, including the Tebbetts and Gryskiewiz papers. We have also reported a dramatic decrease in the rate of hematoma from 7.24% to 0% with the use of BAT in our study of 2016.

Pain and discomfort may be linked to several factors in lip injection [18-21]. Operative trauma, bleeding and blood diffusion into tissues, injury and spasm of the orbicularis oris muscle, causing swelling, bruising and inflammation, have been alluded to as important causes of pain and discomfort in patients who have received hyaluronic acid infiltrations into the lips. Improvement of facial harmony requires a strong knowledge of the anatomy. Most lip injections are performed without a clear understanding of the underlying oral and perioral anatomy. As stressed before the level for hyaluronic acid placement have to be within the submucosa in a very superficial plane, above the orbicularis oris muscle and not intramuscular. This useless trauma may lead to distortion during the infiltration, swelling, bruising and long lasting edema (more than 14 days) and although common potential complications are minimal and resolve spontaneously they are quite always related to injection technique. 0.6 to 1.2 ml has been the average volume injected depending on patient's features. We remark that lip assessment is crucial from a static and dynamic point of view. Identification of the vermilion, philtrum, outer and inner border and patient's smile allow the creation of a reliable, easy and precise method of lip injections strictly related to patient's aesthetic need.

Conclusion

The Bloodless Atraumatic Technique allows to enhance the lip with control and precision without violating important and sensitive anatomical structure like mucosa, labial arteries and orbicularis oris muscle which reduces pain, postoperative discomfort, swelling, bruising, long lasting edema and the possibility of infection. The BAT is a sequential method based on patient's aesthetic need that can reduce infiltration errors and can yield predictable and reliable results. The superficial submucosal plane of injection suggested reduces the amount of hyaluronic acid needed to achieve lip enhancement, at the same time increasing the length of outcomes.

Bloodless Atraumatic Technique Lip Injection offers objective improvements in side effects and complications, recovery and the overall patient experience, but do not happen in a predictable manner without substantial commitment of the medical staff and effort primarily of the aesthetic physician. Obvious limitations in our study include the retrospective nature as well as having multiple doctors involved. Since it is retrospective there could have been bias in the one physician who transitioned from TIT to BAT in choosing easy patients at the beginning of his experience and thus skewing the results in favor of the BAT. However, having

multiple doctors adds variables which we did not examine but it did also add some constants as 2 surgeons treated every patient with BAT and one surgeon treated every patient with TIT.

The use of Bloodless Atraumatic Technique significantly decreased the pain level and discomfort in our practice. Unfortunately, there is no level one evidence that proves that the use of BAT has a lower pain and side effects rate than using Traditional Infiltration Technique procedure. A well powered, thus likely a multicenter, randomized controlled study is needed in order to definitively lay this question to rest. However, our experience adds to the mounting evidence that physicians and surgeons should consider using the BAT and reduce classical technique.

Offering this redelineated level of patient journey needs that injectors study all the entire method and strictly follow the processes and techniques.

References

1. <https://www.isaps.org/wpcontent/uploads/2017/10/GlobalStatistics.PressRelease2016-1.pdf>
2. Chiu A, Fabi S, Dayan S, et al. Lip Injection Techniques Using Small-Particle Hyaluronic Acid Dermal Filler. *J Drugs Dermatol.* 2016; 15: 1076-1082.
3. Dayan S, Bruce S, Kilmer S, et al. Safety and Effectiveness of the Hyaluronic Acid Filler, HYC-24L, for Lip and Perioral Augmentation. *Dermatol Surg.* 2015; 1: S293-301.
4. Rivkin A, Weinkle SH, Hardas B, et al. Safety and Effectiveness of Repeat Treatment With VYC-15L for Lip and Perioral Enhancement: Results From a Prospective Multicenter Study. *Aesthet Surg J.* 2018.
5. Raspaldo H, Chantrey J, Belhaouari L, et al. Lip and Perioral Enhancement: A 12-Month Prospective, Randomized, Controlled Study. *J Drugs Dermatol.* 2015; 14: 1444-1452.
6. Beer K, Glogau RG, Dover JS, et al. A randomized, evaluator-blinded, controlled study of effectiveness and safety of small particle hyaluronic acid plus lidocaine for lip augmentation and perioral rhytides. *Dermatol Surg.* 2015; 1: S127-136.
7. Noviello S, De Santis A, Tocchio M. Face-lift with Bloodless Atraumatic Technique (BAT). Reducing downtime, side-effects and complications. *Plast Surg Mod Tech.* 2016; 1:1.
8. "No-Touch" Technique for Lip Enhancement. Surek CC, Guisantes E, Schnarr K, Jelks G, Beut J. *Plast Reconstr Surg.* 2016; 138: 603e-613e.
9. Cotofana S, Pretterklieber B, Lucius R, et al. Distribution Pattern of the Superior and Inferior Labial Arteries: Impact for Safe Upper and Lower Lip Augmentation Procedures. *Plast Reconstr Surg.* 2017; 139: 1075-1082.
10. Rivkin A, Weinkle SH, Hardas B, et al. Safety and Effectiveness of Repeat Treatment With VYC-15L for Lip and Perioral Enhancement: Results From a Prospective Multicenter Study. *Aesthet Surg J.* 2018 Jan 30.
11. Philipp-Dormston WG, Hilton S, Nathan M. A prospective, open-label, multicenter, observational, postmarket study of the use of a 15 mg/mL hyaluronic acid dermal filler in the lips. *J Cosmet Dermatol.* 2014; 13: 125-134.

12. Sarnoff DS, Gotkin RH. Six steps to the "perfect" lip. *J Drugs Dermatol*. 2012; 11: 1081-1088.
13. Perkins SW, Sandel HD 4th. Anatomic considerations, analysis, and the aging process of the perioral region. *Facial Plast Surg Clin North Am*. 2007; 15: 403-407.
14. Wong WW, Davis DG, Camp MC, et al. Contribution of lip proportions to facial aesthetics in different ethnicities: a three-dimensional analysis. *J Plast Reconstr Aesthet Surg*. 2010; 63: 2032-2039.
15. Klein AW. In search of the perfect lip. *Dermatol Surg*. 2005; 31: 1599-1603.
16. Hoefflin SM. Defining the beautiful face. In: Hoefflin SM. *The Beautiful Face: The First Mathematical Definition, Classification, and Creation of True Facial Beauty*. California. 2002; 2: 33-48.
17. Cartier H, Trevidic P, Rzany B, et al. Perioral rejuvenation with a range of customized hyaluronic acid fillers: efficacy and safety over six months with a specific focus on the lips. *J Drugs Dermatol*. 2012; 11: s17-26.
18. Chopra R, Graivier M, Fabi S, et al. A Multi-Center, Open-Label, Prospective Study of Cannula Injection of Small-Particle Hyaluronic Acid Plus Lidocaine (SPHAL) for Lip Augmentation. *J Drugs Dermatol*. 2018; 17: 10-16.
19. Kechichian E, El Khoury R, Helou J. Less Pain, More Gain: Lip Augmentation With Insulin Syringes. *Dermatol Surg*. 2017; 43: 979-981.
20. Fischer TC, Sattler G, Gauglitz GG. Hyaluron Filler Containing Lidocaine on a CPM Basis for Lip Augmentation: Reports from Practical Experience. *Facial Plast Surg*. 2016; 32: 283-288.
21. Lanigan S. An observational study of a 24 mg/mL hyaluronic acid with pre-incorporated lidocaine for lip definition and enhancement. *J Cosmet Dermatol*. 2011; 10:11-14.