

## Effect of Paracetamol in Closing of PDA in Preterm Babies

Najia Alhojaili<sup>1\*</sup>, Arwa Alhawdar<sup>2</sup>, Attia Al Zahrani<sup>3</sup>, Hatim Al Omari<sup>4</sup>, Helal Almalki<sup>5</sup>, Ibrahim Kutbi<sup>1</sup>, Laila Alabasi<sup>6</sup>, Samira Yamani<sup>7</sup>, Liza Sallam<sup>8</sup>, Amal Zubani<sup>9</sup>, Mutaz Saud MAGHRABI<sup>9</sup> and Mohammed Ibrahim ALFaqeeh<sup>9</sup>

<sup>1</sup>NICU Consultant, Maternity Children Hospital, Abu Dhabi, Makkah.

<sup>2</sup>Medical Student, Maternity Children Hospital, Makkah.

<sup>3</sup>Head of Department of NICU, Medical Director, Maternity Children Hospital, Abu Dhabi, Makkah.

<sup>4</sup>Head of Cluster, NICU Consultant, Maternity Children Hospital, Abu Dhabi, Makkah.

<sup>5</sup>Head of Maternity Children Hospital, NICU Consultant, Abu Dhabi, Makkah.

<sup>6</sup>Senior Consultant of General Pediatric, Maternity Children Hospital, Abu Dhabi, Makkah.

<sup>7</sup>Cardiology Consultant, Maternity Children Hospital, Abu Dhabi, Makkah.

<sup>8</sup>General Pediatric Consultant, Maternity Children Hospital, Abu Dhabi, Makkah.

<sup>9</sup>NICU Consultant, King Faisal Specialist Hospital and Research Center Jeddah.

**Citation:** Najia Alhojaili, Arwa Alhawdar, Attia Al Zahrani, et al. Effect of Paracetamol in Closing of PDA in Preterm Babies. J Med - Clin Res & Rev. 2022; 6(12): 1-3.

### Keywords

Paracetamol, Preterm babies, PDA.

### Objective

We tried to collect no of preterm babies less than 32 weeks less than 1500gram admitted in NICU from 1-1-2020 till the end of 31-12-2021 And we want to see the effects of paracetamol in form of closing of ducts arteriosus in preterm babies, we used gestation age between 24 weeks till 32 weeks delivery at this period

### Methods

We used paracetamol in a dose of 15mg/kg/dose for three days in all preterm babies less than 1500 grams and we did Echocardiogram if PDA is present and affected the hemodynamic and stability of the babies, for example, the babies on a mechanical ventilator, received two doses of servants had hypotension and had large to

### \*Correspondence:

Dr. Najia Alhojaili NICU Consultant, Maternity Children Hospital, Abu Dhabi. POBOX 8981, Makkah.

**Received:** 04 Dec 2022; **Accepted:** 23 Dec 2022; **Published:** 27 Dec 2022

moderate PDA we gave them paracetamol 15mg/kg every 6 hours then we repeated Echocardiogram if still, PDA is present we gave them second course 15mg/kg/dose for 2 days.

We rolled in 400 babies preterm delivered from 1-1-2020 till the end of 31-12-2021 we did a retrospective study to collect the data from files we saw the response of the drug in form of closing PDA and only one baby had surgery in form of PDA ligation.

### Inclusion Criteria

Preterm less than 32 weeks or less than 1500gram.

Preterm had hypotension and need a high setting of the ventilator. Any preterm less than 32 weeks and echocardiogram show PDA. Any preterm babies whose mothers have not received antenatal steroids.

Any congenital anomalies have not affected the life.

## Excluding Criteria

Multiple congenital anomalies.  
Preterm babies who died before roll in the study.  
Preterm babies who died within 48 hours.  
Any preterm had coagulopathy.  
Any preterm had renal failure.

## Result

We see from the study the effect of paracetamol in preterm babies from the 1st course how many babies were respond, how many babies need 2nd course, and how many babies went to PDA ligation. And we saw the babies whose mothers received steroids antenatal either had small PDA and did not need a high setting of the ventilator and this was the effect of antenatal steroids not only in the closing of PDA but also the need for the high setting of the ventilator and decreasing respiratory distress syndrome

Patent ducts arteriosus is very common in preterm babies and is associated with serious complications like necrotizing enterocolitis and bronchopulmonary dysplasia. This condition, which occurs when the vessel connecting the aorta and the pulmonary artery does not close normally, is associated with increased neonatal mortality and morbidity, including bronchopulmonary dysplasia [1], Necrotizing enterocolitis, [2] and intraventricular hemorrhage [3].

We performed the Early Treatment Versus Expectative Management of PDA in Preterm Infants by using paracetamol in a dose of 15 mg/kg dose once a day for 5 days and before using this protocol we did an echocardiogram to confirm the ducts were patent and affect the condition of for preterm babies in form of increased oxygen requirement and hypotension in preterm babies, usually, we did an echocardiogram on the third day of life, started paracetamol, and repeat an echocardiogram at the fifth day of life if the preterm babies need an extension of the duration of paracetamol we for gave three days extra and repeat echocardiogram if the ducts were not close we did ligation of this duct to save the baby life.

## Method

The study connected at Maternity children's hospital in the Makkah area, Saudi Arabia. It was only a single center, not a randomized study, we tried to collect all preterm babies delivered between 1st January 2020 till the end of December 2021 400 babies enroll in the study the weight ranging from 500gram to 1500gram, and gestational age between 23weeks till 32 weeks. We exclude the multiple congenital anomalies and the babies died before the third day of life Most of the babies were connected to mechanical and received two doses of servants, and some of them were supported by inotrope, all the babies were delivered in a hospital, some mothers took steroids before delivery at least one dose, some were taken two doses and a few came as an emergency as they had bleeding and were immediately taken to theatre to save mother life.

We follow the protocol management in treating ducts arteriosus by doing an echocardiogram on 3rd day of life in all preterm less than 1500gram the ducts were patent and effect hemodynamic starting paracetamol 1st protocol 15mg/kg day once a day for 5th days and repeat an echocardiogram if still patent we extend the course to three days more and repeat echocardiogram if still patent we did ligation.

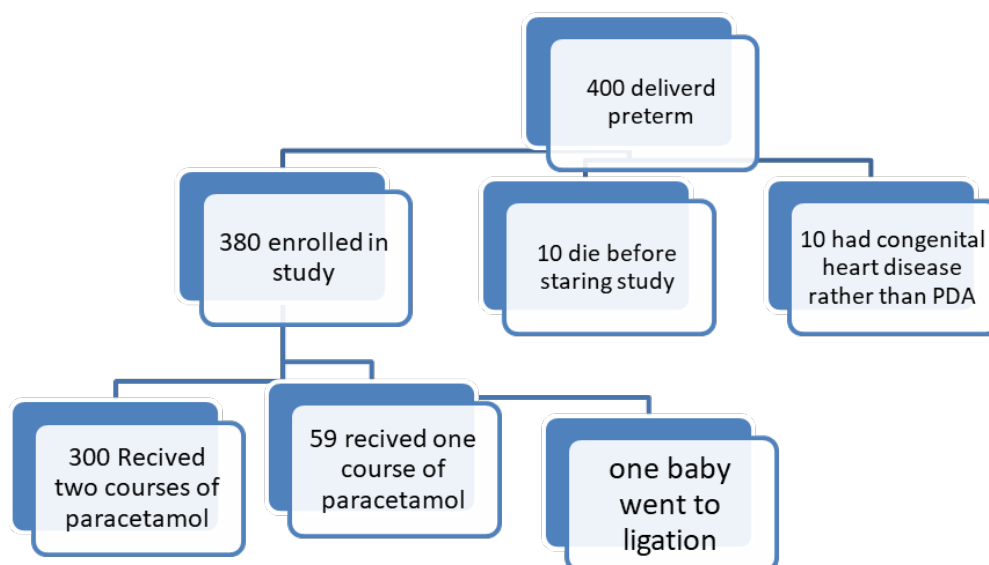
All babies consoling was done and of 400 babies only one baby went to surgery in form of ligation. The primary outcome was long mechanical ventilation, necrotizing enterocolitis, pulmonary hemorrhage. The secondary outcome was bronchopulmonary and failure to thrive and prolong total parenteral fluid.

## Randomization

Only one center at a Maternity children's hospital in Makkah.

## Result

This only single study done between 2020 till the end of 2021 in preterm babies delivered in Maternity children hospital Makkah, SAUDI Arabia. We did this study in 400 babies delivered between 1st January 2020 till the end December 2021. All of them received



---

Paracetamol after an echocardiogram showed there were large patent ducts arteriosus affect the ventilation and affect the hemodynamic. There were 400 babies preterm delivered in this time 380 enrolled in our study by given paracetamol and 10 babies died before enter in the study percentage 2.5% and 10 babies had congenital heart disease other than PDA 2.5%. 79% our babies had closure of PDA After 2nd course of paracetamol and 15% had closure after one course and one baby went to surgery ligation 0.26%.

From this result it was appeared the effect of paracetamol in closure of ducts arteriosus the 300 babies who were used two courses of paracetamol the were sick from beginning and the mother s were not complete the courses of antenatal steroid, and the babies who were received one course of paracetamol from beginning they not need high setting of ventilation and their mother were prepared well by taking two courses of antenatal steroids.

### Conclusions

Moderate-quality evidence according to GRADE suggests that paracetamol is as effective as ibuprofen; low-quality evidence suggests paracetamol to be more effective than placebo or no intervention; and low-quality evidence suggests paracetamol as effective as indomethacin in closing a PDA.

These findings tentatively conclude that paracetamol can induce early PDA closure without noticeable side effects but do not demonstrate that paracetamol is superior to indomethacin. Therefore, more well-designed studies are needed to enrich the evidence of this treatment. Finally, because of the controversy in the diagnosis and treatment of PDA in premature infants, this updated systematic review and meta-analysis only summarizes the existing evidence and does not make any recommendations.

### Reference

1. Brown ER. Increased risk of bronchopulmonary dysplasia in infants with patent ductus. *J Pediatr.* 1979; 95: 865-866.
2. Dollberg S, Lusky A, Reichman B. Patent ductus arteriosus, indomethacin and necrotizing enterocolitis in very low birth weight infants a population-based study. *J Pediatr Gastroenterol Nutr.* 2005; 40: 184-188.
3. Lipman B, Serwer GA, Brazy JE. Abnormal cerebral hemodynamics in preterm infants with patent ductus arteriosus. *Pediatrics.* 1982; 69: 778-781.