

Evaluation of Surgical Treatment for Malunited Diaphyseal Fractures of the Femur in Adults

Abdoulaye CAMARA^{1*}, Abdoul Karim BALDÉ¹, Mohamed MANSARÉ², Nouhou Mangué CAMARA², Léopold LAMAH³, Mamadou Moustapha DIALLO⁴, Alhassane BARRY⁴, Alpha Mamadou Felah DIALLO², and Sory SIDIMÉ²

¹Orthopedic Surgeon-traumatologist, Hospital Practitioner, Donka University Hospital, Conakry, Republic of Guinea.

²Orthopedic Surgeon-traumatologist, Assistant at the Faculty of Health Sciences and Technology, Gamal Abdel Nasser University, Conakry, Republic of Guinea.

³Full Professor, Head of the Orthopedics-Traumatology Department, Donka University Hospital, Conakry, Republic of Guinea.

⁴Senior Lecturer at the Faculty of Health Sciences and Technology, Gamal Abdel Nasser University, Conakry, Republic of Guinea.

*Correspondence:

Abdoulaye CAMARA, Orthopedic Surgeon-traumatologist, Hospital Practitioner, Donka University Hospital, Conakry, Republic of Guinea, Tel: +224628873535.

Received: 05 Feb 2026; Accepted: 08 Mar 2026; Published: 20 Mar 2026

Citation: Abdoulaye CAMARA, Abdoul Karim BALDÉ, Mohamed MANSARÉ, et al. Evaluation of Surgical Treatment for Malunited Diaphyseal Fractures of the Femur in Adults. J Med - Clin Res & Rev. 2026; 10(3): 1-5.

ABSTRACT

Introduction: A malunion can be defined as the consolidation of a fracture site with structural alteration of the bone, affecting its configuration, length, and alignment.

The objective of our study was to evaluate the results of surgical treatment of diaphyseal malunions of the femur in our department.

Patients and Methods: This was a retrospective, single-center, descriptive study covering an 8-year period from January 1, 2017, to December 31, 2024, involving 23 patients admitted to Donka University Hospital for malunions of the femoral shaft, with or without other complications.

Results: The average time to treatment was 6 months (ranging from 3 to 16 months). We performed osteotomy with screw fixation in 56.5% of cases and static locked intramedullary nailing in 43.5%. Cortico-cancellous bone grafting was performed in 26.1% of cases. The average length of hospital stay was 7 days (ranging from 3 to 30 days). Our functional results were good in 8 cases (34.8%), average in 11 cases (47.8%), and poor in 4 cases (17.4%). The average postoperative knee flexion was 120° (ranging from 60° to 130°). The average limb length gain was 2 cm (ranging from 1.5 cm to 4.5 cm). At the 6-month follow-up, we noted 2 cases of aseptic pseudoarthrosis.

Conclusion: Diaphyseal femoral fractures should be treated surgically, preferably with locked intramedullary nailing, to avoid the development of malunions, whose functional prognosis is dominated by stiffness, axial defects, and lameness.

Keywords

Malunion, Surgical, Diaphyseal, Evaluation, Fracture, Treatment.

Introduction

A nonunion can be defined as the consolidation of a fracture site with structural alteration of the bone, affecting its configuration, length, and alignment [1]. Their frequency has decreased

considerably in developed countries due to the preference for surgical treatment, which promotes rapid recovery. However, in developing countries, malunions of the diaphysis are often due to traditional treatments or inadequate surgical equipment, which do not allow for appropriate hospital care [2-4].

The difficulties in treating malunions are related to restoring the axis, limb length, and mobility of the knee and hip joints [5].

The objective of our study was to evaluate the results of surgical treatment of diaphyseal malunions of the femur in our department.

Patients and Methods

This was a retrospective, single-center, descriptive study spanning eight years, from January 1, 2017, to December 31, 2024, involving 23 patients admitted to Donka University Hospital for malunions of the femoral shaft, with or without other complications.

Inclusion criteria

All patients admitted for malunion of the femoral shaft, treated surgically, followed up, and evaluated in the department were included in our study.

Exclusion criteria

Patients admitted for malunions of segments other than the femoral diaphysis, patients who refused the treatment proposed by the department, and those who were lost to follow-up during the evaluation of results were excluded from our study.

Study population

We collected data on 23 patients, including 18 men (78.3%) and 5 women (21.7%), with a sex ratio (M/F) of 3.6. The average age was 34.6 years, ranging from 19 to 78 years. Manual workers were the most represented socio-professional group in our study, with 12 cases (52.2%). The circumstances surrounding the initial injury were dominated by road traffic accidents, with 19 cases (82.6%). The left femur was the most commonly affected, with 13 cases (56.5%). Lower limb length discrepancy (LLLD) averaged 3 cm, ranging from 1.5 to 4.5 cm. Knee flexion limitation averaged 65°, ranging from 15° to 120°. The location of the lesions was predominantly in the middle third in 15 cases (65.2%), followed by the lower third in 5 cases (21.7%) and the upper third in 3 cases (13.1%). The predominant anatomical pathology was overlapping in 17 cases (73.9%) and angulation in 6 cases (26.1%). The initial treatment was predominantly traditional medicine administered by a bone setter in 21 cases (91.3%); two cases involved orthopedic treatment with a cast, performed in a peripheral health facility (health center).

Parameters studied

We studied the therapeutic and evolutionary aspects of surgical treatment for malunion of diaphyseal fractures of the femur.

From a therapeutic perspective, we studied: medical treatment (analgesics, antibiotics, anticoagulants) and surgical treatment (time to treatment, patient positioning, type of anesthesia, approach,

surgical technique, postoperative care, rehabilitation, length of hospital stay, and immediate postoperative complications). Osteosynthesis was performed by osteotomy plus static locked intramedullary nailing and screw fixation.

In terms of progression, our assessment was anatomical (clinical and paraclinical) and functional (complications and evaluation of results according to Thorensen's criteria [6]).

At a mean follow-up of 12 months (range 6 months to 24 months), we assessed our patients using the Thorensen functional score [6].

Study materials

Our data were collected from information provided in medical records, hospitalization records, surgical report records, and a pre-established survey form.

Data entry and analysis

Our data were entered using Word and Excel 2016 software and analyzed using Epi Info version 7.2.2.

Results

Therapeutic aspects

All our patients received immediate post-operative antibiotic prophylaxis through the administration of 1g/125mg of amoxicillin + clavulanic acid intravenously, twice a day; anticoagulant (low molecular weight heparin) by subcutaneous injection once a day and analgesics (1 g of paracetamol for infusion + 100 mg of tramadol for injection) every 6 hours.

The average time between the fracture occurring and treatment was 6 months (ranging from 3 to 16 months). The average time to treatment after consultation of the surgical program was 30 days (ranging from 7 to 90 days). All our patients were placed in the supine position on a standard operating table, with a block under the ipsilateral buttock.

The ipsilateral iliac crest was prepared in advance and placed in the surgical field for a possible cortico-cancellous bone graft. All our patients received local-regional anesthesia. A lateral approach was used in all our patients to perform the osteotomy.

We performed osteotomy in all our patients. After reduction of the lesion, plate fixation was performed in 13 patients (56.5%), and static locked intramedullary nailing was performed in 10 patients (43.5%) (Table 1). Cortico-cancellous bone grafting was performed in 6 patients (26.1%). The surgical wound was closed layer by layer over a suction Redon drain.

Table 1: Distribution of patients according to type of surgical treatment.

Type of surgical treatment	Workforce	Percentage (%)
Screw plate	13	56.5
Static locked intramedullary nailing	10	43.5
Total	23	100

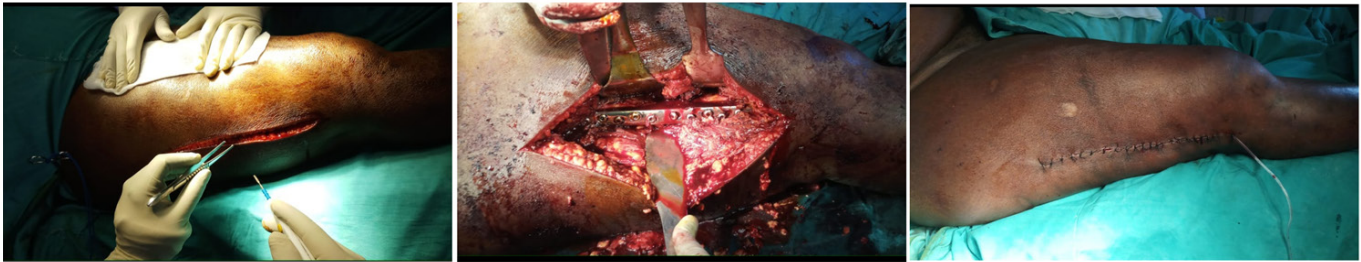
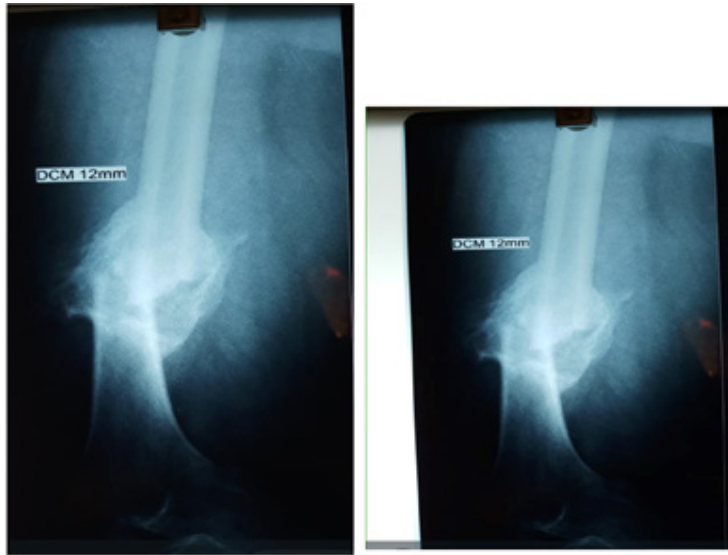

Figure 1: Standard X-rays showing the malunion of the femoral diaphysis and follow-up after osteotomy + osteosynthesis with screw plate fixation.

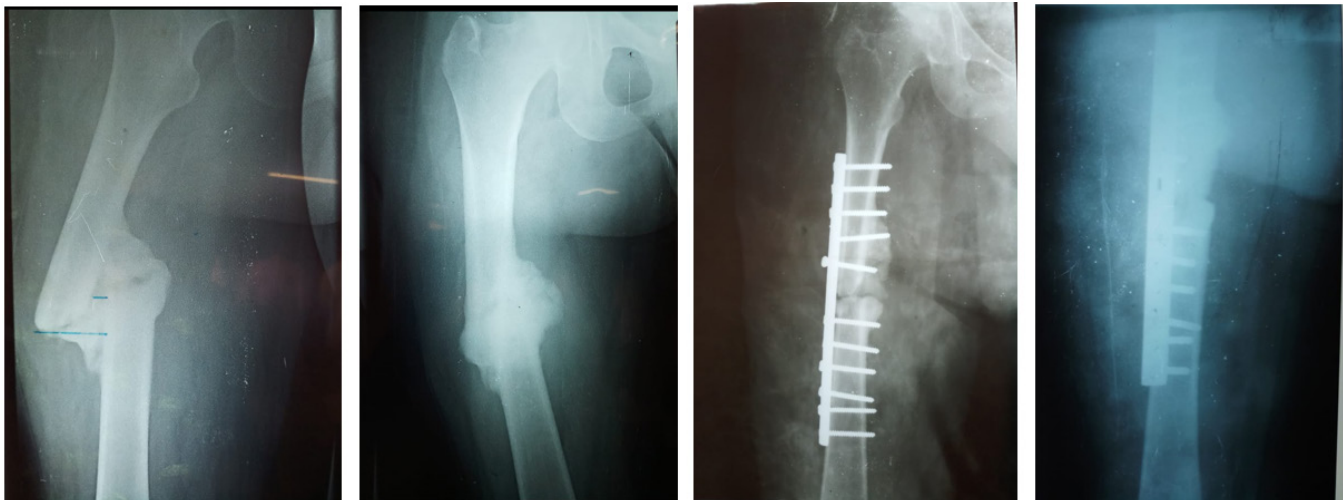


Figure 2: Standard X-rays showing malunion of the femoral diaphysis, treatment with osteotomy + screw plate.

Postoperatively, all patients received medical treatment with painkillers, antibiotics, and anticoagulants. Local care was provided until the sutures were removed.

After a follow-up X-ray, the knee was mobilized the day after surgery, and patients were then helped to stand upright with the aid of a pair of crutches without support.

Rehabilitation began the day after surgery with knee mobilization and isometric quadriceps contraction, and continued with physical

therapy until the fracture had healed in all of our patients.

We recorded two cases of superficial infection, which we treated with targeted antibiotic therapy based on the results of the antibiogram. The average length of hospital stay was seven days (ranging from three to 30 days).

Progressive aspects

After an average follow-up period of 12 months, we evaluated our patients according to Thorensen's criteria [6].

The average bone healing time was 4 months (ranging from 3 to 8 months).

Our patients were evaluated according to Thorensen's functional criteria [6]. Our results were good in 8 cases (34.8%), average in 11 cases (47.8%), and poor in 4 cases (17.4%) (Table 2). The average postoperative knee flexion was 120° (ranging from 60° to 130°). The average limb length gain was 2 cm (ranging from 1.5 to 4.5 cm).

Table 2: Distribution of patients according to Thorensen's functional criteria [6].

Functional criteria	Workforce	Percentage (%)
Good	08	34.8
Average	11	47.8
Poor	05	17.4
Total	23	100

At the 6-month follow-up, we noted two cases of aseptic pseudarthrosis, including one case involving a fracture of the osteosynthesis hardware (screwed plate), which were treated surgically with pseudarthrosis cure and static locked intramedullary nailing, resulting in consolidation.

Discussion

Therapeutic aspects

The average time between fracture occurrence and treatment was 6 months (ranging from 3 to 16 months). The average time between consultation and surgery was 30 days (ranging from 7 to 90 days). In the series by Souna BS [7] and Sidibé S [8], the average time to surgical treatment was 8.15 months (ranging from 1 to 26 months) and 8 months (ranging from 3 to 48 months), respectively. These results can be explained by the fact that almost all of our patients initially sought treatment from traditional healers.

Surgical treatment consisted of osteotomy, followed by stable osteosynthesis using screw plates (56.5%) and static locked intramedullary nailing (43.5%). This allowed the correction of lower limb length inequality in the majority of cases, as well as angular deformities. This result is comparable to those found by Sidibé S [8], who found a predominance of treatment by Intramedullary nailing in 59.37%. Furthermore, Tekpa BJD [1] and Souna BS [7] reported intramedullary nailing treatment in 85.3% and 56.2% of their series, respectively.

As immediate postoperative complications, we recorded two cases of superficial infection, which we controlled with targeted antibiotic therapy based on the results of the antibiogram. At the six-month follow-up, we noted two cases of aseptic pseudarthrosis. These aseptic pseudarthroses were treated surgically with pseudarthrosis cure and static locked intramedullary nailing, and consolidation was achieved. The literature reports a low rate of pseudarthrosis [3,7-9].

Evolutionary aspects

In our series, bone consolidation was achieved in all our patients, with an average consolidation time of 4 months (ranging from 3 to 9 months). In Monka M's series [2], the average consolidation time was 4 months (ranging from 3 to 7 months).

The average postoperative knee flexion was 120° (ranging from 60° to 130°). The average limb length gain was 2 cm (ranging from 1.5 to 3.5 cm).

In the series by Qi-Fang He et al. [10], the average limb length gain was 2.6 cm (from 2.4 to 2.8 cm). The average joint range of motion in the affected knees was 3.4° to 112.55°.

We obtained 82.6% satisfactory results, which are comparable to those found by Souna [7], who obtained 86.95% to 96.3% satisfactory results.

Conclusion

The initial management of diaphyseal femoral fractures should be surgical, preferably with locked intramedullary nailing. Malunions are the preserve of traditional treatment, where the functional prognosis remains dominated by stiffness, lower limb axis defects, and lameness.

References

1. Tekpa BJD, Doui-Doumouba A, Issa Mapouka PA, et al. Les cals vicieux diaphysaires du fémur de l'adulte traités par ostéotomie et ostéosynthèse à ciel ouvert à Bangui. *J Afr Chir Orthop Traumatol*. 2017; 2: 56-63.
2. Monka M, Etsaka T, Ngatsé-Okoko A, et al. Results of Surgical Treatment of Leg Shaft Mal-Union in Adults at CHU-Brazzaville. A Five Case Retrospective Observation. *Open Journal of Orthopedics*. 2019; 9: 191-196.
3. Gogoua RD, Anoumou M, Koné, A, et al. Aspects épidémiologiques et thérapeutiques des cals vicieux des fractures diaphysaires des membres au CHU de Treichville à Abidjan. *Rév Int Sc Med*. 2007; 9: 55-60.
4. Moyikoua A, Ngatsé-Okoko A, Bouity-Buang Ondzoto JM, et al. Résultats du traitement initial des fractures ouvertes récentes des membres. A propos de 150 cas traités au CHU de Brazzaville. *Médecine d'Afrique Noire*. 1992; 39: 755-762.
5. Tall M, Ouédraogo I, Kasse ANd, et al. Femur malunion treated with open osteotomy and intramedullary nailing in developing countries. *Orthop Traumatol Surg Res*. 2012; 98: 784-787.
6. Thoresen BO, Salut A, Ekeland A, et al. Enclouage centro-médullaire verrouillé dans les fractures de la diaphyse fémorale. *The Journal of Bone and Joint Surgery*. 1985; 67: 1313-1320.
7. Souna BS, Mamoudou A, Guida S. Les cals vicieux diaphysaires du fémur. À propos de 32 cas colligés à Niamey MALI MEDICAL. 2010; XXV: 7-10.

-
8. Sidibé S, Coulibaly T, Thiam SM, et al. Résultats fonctionnels de la prise en charge en milieu traumatologique des cals vicieux de la diaphyse fémorale au mali. *Pan arab j ortho trauma*. 2002; 6: 6.
 9. Magerl F, wyss A, Brunner C, et al. Plate osteosynthesis of femoral shaft fractures in adults. A follow-up study. *Clin ortho*. 1979; 138: 63-73.
 10. Qi-fang He, Han-xu Wang, Hui Sun, et al. Medial Open-wedge Osteotomy with Double plate Fixation for Varus Malunion of the Distal Femur. *Orthop Surg*. 2019; 11: 82-90.