Review Article ISSN 3070-3972

International Journal of Orthopedic Surgery & Research

Foot Drop Secondary to an Intraneural Cyst of the Common Fibular Nerve: Case Report and Literature Review

Mohammed Boussaidane[1,4*], Ouijdane Zamani[2], Houda Alloussi[3], Reda Badaoui[1], Youssef Benyass[1], Abdelatif Benbouha[4], Hicham Salahi[4], Jalal Boukhriss[1] and Omar Margad[4]

[1]*Department of Orthopedic Surgery and Traumatology II, HMIMV, FMPR, Rabat, Morocco.*

[2]*Department of Radiology, HMIMV, FMPR, Rabat, Morocco.*

[3]*Department of Neurophysiology, HMIMV, FMPR, Rabat, Morocco.*

[4]*Department of Orthopedic Surgery and Traumatology, Avicenna Military Hospital, LRMS Lab, FMPM, Cadi Ayyad University, Marrakech, Morocco.*

[*]Correspondence:
Mohammed Boussaidane, Department of Orthopedic Surgery and Traumatology, Avicenna Military Hospital, LRMS Lab, FMPM, Cadi Ayyad University, Marrakech, Morocco.

Received: 21 Sep 2026; **Accepted:** 29 Oct 2026; **Published:** 07 Nov 2026

Citation: Mohammed Boussaidane, Ouijdane Zamani, Houda Alloussi, et al. Foot Drop Secondary to an Intraneural Cyst of the Common Fibular Nerve: Case Report and Literature Review. Int J Orthop Surg Res 2026; 2(1): 1-5.

ABSTRACT

Introduction: *An intraneural ganglion cyst of the common peroneal nerve (CPN) is a rare but well-defined cause of progressive compressive neuropathy in the lower extremity, which can lead to foot drop if diagnosis is delayed.*

Case Report: *We report the case of a 49-year-old female patient with no remarkable medical history who presented with pain and paresthesia in the left forefoot and leg, gradually progressing to motor paralysis in the CPN distribution. Electromyography (EMG) and magnetic resonance imaging (MRI) confirmed the diagnosis of an intraneural CPN cyst extending from the sciatic nerve bifurcation down to behind the fibular head.*

Intervention: *The patient underwent neurolysis via a posterolateral popliteal approach extended posteriorly to the fibular head, combined with an epineurotomy and evacuation of the cystic contents. A systematic search for a joint communication with the superior tibiofibular joint was performed but yielded negative results.*

Results: *Postoperative progress showed gradual functional recovery of foot dorsiflexion and resolution of sensory impairment in the CPN distribution at 5 months of follow-up.*

Conclusion: *CPN intraneural ganglion cyst should systematically be considered in any unexplained progressive fibular neuropathy. Early surgical intervention combining neurolysis, epineurotomy, and identification of the articular branch yields satisfactory functional recovery, even when no joint communication is formally identified.*

Keywords

Intraneural ganglion cyst, Common peroneal nerve, CPN palsy, Epineurotomy, Neurolyse, Articular theory.

Introduction

Intraneural ganglion cysts are benign cystic lesions developing within the subepineural connective tissue of a peripheral nerve. They must be distinguished from extraneural ganglion cysts, which develop outside the nerve sheath and cause extrinsic compression. Due to its superficial anatomical course and proximity to the superior tibiofibular joint, the common peroneal nerve (CPN) represents by far the most frequent site of intraneural ganglion cysts in the peripheral nervous system [1-3].

The most widely accepted pathophysiological mechanism is the unified articular theory described by Spinner et al. [1]. According to this theory, synovial fluid from the superior tibiofibular joint dissects along the recurrent articular branch of the CPN into the

subepineural space, spreading proximally and sometimes reaching as far as the sciatic nerve bifurcation [1,4,5]. This concept has fundamentally changed the surgical strategy, highlighting the necessity of identifying and addressing the articular stalk to minimize the risk of recurrence [6,7].

Clinically, patients typically present with progressive fibular neuropathy characterized by pain and paresthesia, followed by a motor deficit that can progress to complete foot drop [2,8]. Diagnosis relies primarily on magnetic resonance imaging (MRI), which delineates the extent of the cyst along the nerve and reveals indirect signs of muscle denervation [3,8]. Electromyography (EMG) complements MRI by confirming the location and severity of the nerve injury [3,8].

We report the case of a patient presenting with CPN palsy secondary to an extensive intraneural ganglion cyst extending from the sciatic bifurcation down behind the fibular head, successfully managed surgically, and discuss the findings in light of the recent literature.

Case Presentation

A 49-year-old female patient with no relevant medical or surgical history, no prior trauma to the left lower extremity, and no history of high-level sports involvement presented with pain and paresthesia affecting her left forefoot and leg.

The symptoms initially presented as burning pain and electric shock sensations accompanied by paresthesia in the CPN distribution, without any clear triggering factor. The clinical condition progressively deteriorated into a motor deficit affecting the ankle dorsiflexors, resulting in a full CPN palsy picture that prompted specialist evaluation.

Physical examination revealed a steppage gait, weak ankle dorsiflexion, and impaired toe extension on the left side, along with hypoesthesia in the CPN cutaneous distribution. Tinel's sign was positive over the fibular neck. Palpation along the course of the nerve, assessment of foot eversion, vascular examination, and evaluation of the contralateral lower limb showed no other abnormalities.

Standard plain radiographs of the left knee and leg showed no bone abnormalities, ruling out an underlying osseous lesion (such as an intraosseous cyst or bone tumor) that could induce nerve compression.

Electromyography (EMG) revealed neurogenic suffering in the CPN territory, confirming electrophysiological injury and helping grade the severity and location of the lesion, consistent with clinico-electrophysiological patterns reported in the literature [8]. Specifically, there was a >50% reduction in the motor amplitude of the left CPN compared to the right side, with a conduction block at the fibular neck, indicating motor axonal injury.

MRI of the left knee and leg confirmed the diagnosis by demonstrating a lobulated intraneural cystic lesion of the CPN following a tubular course along the nerve, extending from the sciatic nerve bifurcation down to behind the fibular head (Figures 1 and 2).

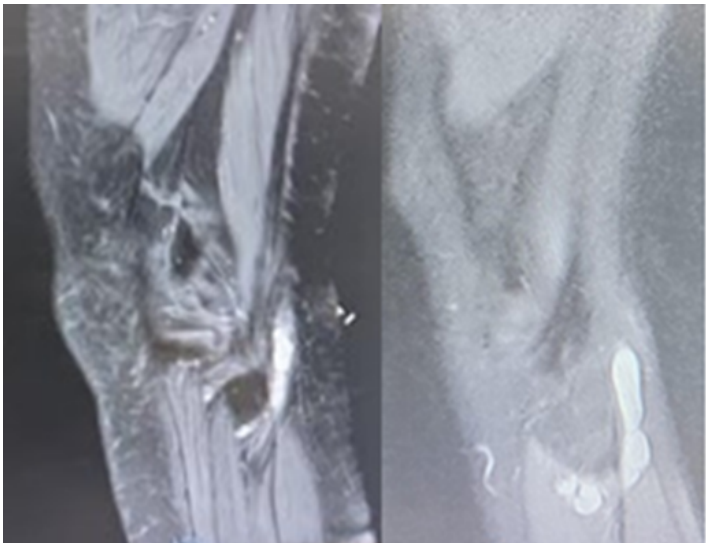

Figure 1: Sagittal MRI view of the knee showing an extensive intraneural cystic lesion along the CPN.

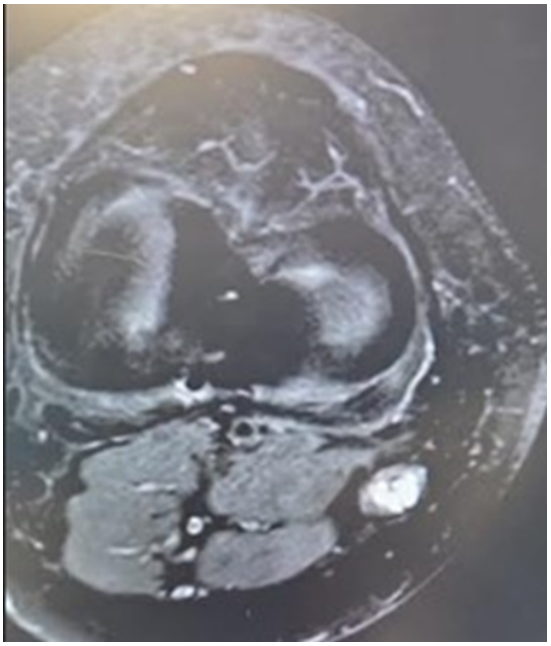

Figure 2: Axial MRI view of the knee showing the hyperintense intraneural CPN ganglion cyst.

Given the mechanical nerve compression confirmed by imaging, surgical decompression was indicated.

The surgery was performed via a posterolateral popliteal approach extended distally behind the fibular head to expose the full extent of the lesion. External neurolysis was performed to circumferentially free the nerve and its branches from surrounding tissues (Figures 3 and 4).

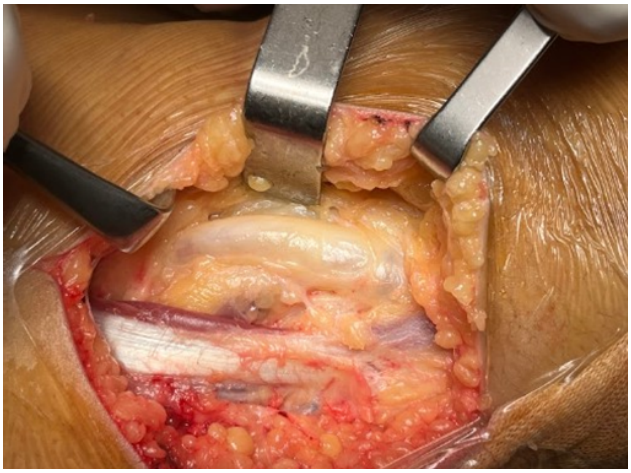

Figure 3: Intraoperative view showing the deformed CPN at the onset of neurolysis.



Figure 4: Intraoperative view after CPN neurolysis: deformed nerve with an elongated, translucent intraneural cystic lesion.

A longitudinal epineurotomy was then performed, opening the epineural sheath and evacuating the mucoid fluid content of the cyst, leading to progressive decompression of the compressed nerve fascicles (Figures 5 and 6).

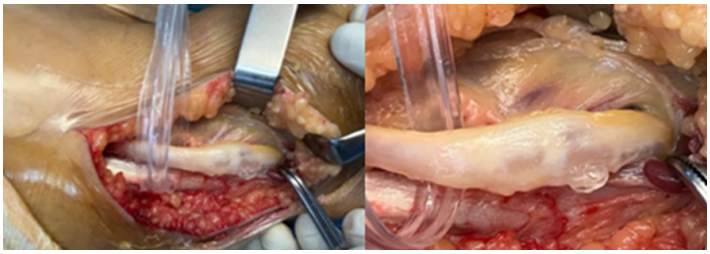

Figure 5: Intraoperative view showing the fluid evacuated from the cyst following epineurotomy.

In accordance with current management principles based on Spinner's articular theory and targeted operative techniques [1,7], a systematic search was performed for a joint communication connecting the cyst to the superior tibiofibular joint via the recurrent articular branch. However, no clear communication could be identified intraoperatively.

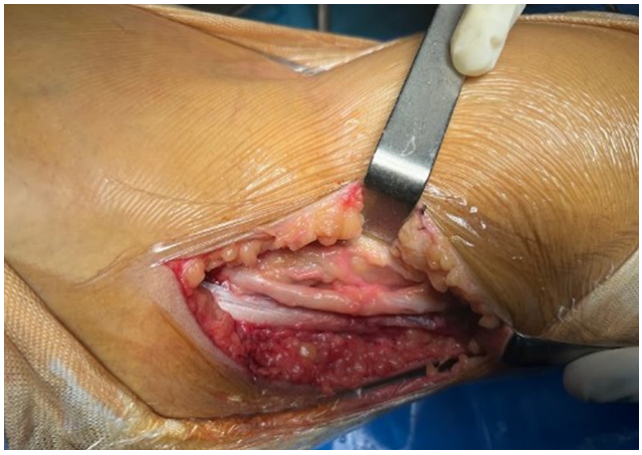

Figure 6: Final intraoperative appearance of the nerve following neurolysis, epineurotomy, and cyst evacuation.

The immediate postoperative course was uneventful, with no hematoma or wound infection. At the 5-month follow-up, the patient demonstrated progressive recovery of foot dorsiflexion and complete resolution of sensory loss, with no clinical signs of recurrence. Follow-up electrodiagnostic testing at 5 months demonstrated resolution of the conduction block at the fibular neck.

Discussion

Although overall uncommon, intraneural ganglion cysts of the CPN represent the most frequent location among all peripheral nerve intraneural ganglia, owing to the nerve's superficial anatomical path around the fibular neck and its close proximity to the superior tibiofibular joint [1-3]. Spinner's unified articular theory remains the gold standard pathophysiological model: synovial fluid escapes through a capsular breach and dissects along the recurrent articular branch into the subepineural space [1,6]. Fluid progression in an ascending and sometimes descending direction explains extensive lesions distant from the joint, including extension up to the sciatic bifurcation, as seen in our patient and similar reports [4,5,9].

The classical clinical presentation features an initial phase of pain and paresthesia preceding motor deficit by several weeks to months [2,8]. This timeframe between sensory symptoms and motor deficit represents a critical diagnostic and therapeutic window before irreversible axonal injury occurs. Steppage gait and dorsiflexion weakness are the hallmark features of established palsy, even in rare cases involving combined injury to both tibial and CPN branches within the popliteal fossa [10].

MRI remains the modality of choice for diagnosis and anatomical mapping. Cysts typically present as tubular or lobulated lesions, hypointense/isointense on T1-weighted images and hyperintense

on T2-weighted images along the CPN course. Secondary signs of muscle denervation (T2/STIR hyperintensity within CPN-innervated compartments) help assess chronicity. High-resolution ultrasound can also reliably detect intraneural ganglia as an accessible screening tool [11], although MRI remains superior for defining the full extent of the lesion and its relationship with the proximal tibiofibular joint. Standard radiography is used to rule out underlying osseous pathology.

Electrodiagnostic studies (EMG/NCS), while non-specific regarding the exact underlying lesion type, remain essential for confirming neurogenic injury, identifying the precise anatomical site, and providing prognostic guidance regarding recovery potential [8].

Surgical decompression via neurolysis, epineurotomy, and cyst evacuation is the standard treatment. A key contribution of the articular theory was emphasizing the mandatory search for and ligation/resection of the articular branch, considered the entry portal for synovial fluid into the nerve trunk [1,6,7]. Recurrence remains the primary limitation of isolated cyst decompression: a recent systematic review reported an overall recurrence rate of 28.9% following primary surgery, with marked variation depending on the technique — 81.8% after simple aspiration, 27.4% after isolated cyst excision, compared to 8.3% following partial resection of the proximal tibiofibular joint, and 0% following superior tibiofibular joint arthrodesis [12]. Similarly, a landmark series reported a 13% recurrence rate after initial excision, climbing to 100% after repeat isolated excision, whereas no recurrences occurred following joint arthrodesis [13].

A systematic review on prognostic factors identified intraneural extension, cyst recurrence, and participation in contact sports as independent risk factors for functional failure, whereas articular branch ligation was protective; pre-existing knee osteoarthritis was found to be the main risk factor for recurrence, while superior tibiofibular joint arthrodesis was highly protective [14].

In our case, despite meticulous surgical exploration, no direct joint communication could be demonstrated. This occurrence is well-documented in the literature: several series report a notable subset of cases where the articular branch cannot be formally identified intraoperatively, even in recurrent cases requiring reoperation [12,15]. The absence of an identifiable joint communication does not invalidate the diagnosis nor preclude satisfactory motor recovery, although the long-term risk of recurrence necessitates extended clinical and imaging follow-up.

Functional motor and sensory recovery after surgical decompression is generally favorable but depends on several variables, including preoperative symptom duration, baseline deficit severity, and the degree of axonal injury on EMG [8,14]. Recovery timeframes reported in the literature range from several weeks to many months [16,17], consistent with the recovery timeline observed in our patient at 5 months. Early diagnosis prior to dense, prolonged motor paralysis remains the single most important favorable prognostic factor.

Intraneural CPN ganglia can also occur in pediatric patients [18] or, exceptionally, in temporal association with vaccination, such as following COVID-19 vaccination [9], though a formal causal link has not been established. Other recent reports highlight atypical presentations, including unusually large cysts or combined involvement of adjacent nerve branches [10,16,17]. These presentations reinforce the importance of considering intraneural ganglion cysts in any patient with progressive fibular neuropathy and differentiating them from extraneural cysts, nerve sheath tumors, or positional compression.

Conclusion

Intraneural ganglion cyst of the common peroneal nerve is a rare but well-established cause of progressive compressive neuropathy that should be considered in patients presenting with isolated pain or paresthesia in the forefoot and leg, even before motor deficits develop. MRI is the key imaging modality for definitive diagnosis and mapping. Surgical management combining neurolysis, epineurotomy, and systematic identification of any joint connection provides excellent functional outcomes.

References

1. Spinner RJ, Atkinson JLD, Tiel RL. Peroneal intraneural ganglia: the importance of the articular branch. A unifying theory. J Neurosurg. 2003; 99: 330-343.
2. Kokkalis ZT, Kalavrytinos D, Kokkineli S, et al. Intraneural ganglion cysts of the peroneal nerve. Eur J Orthop Surg Traumatol. 2021; 31: 1639-1645.
3. Desy NM, Wang H, Elshiekh MAI, et al. Intraneural ganglion cysts: a systematic review and reinterpretation of the world's literature. J Neurosurg. 2016; 125: 615-630.
4. Spinner RJ, Mokhtarzadeh A, Schiefer TK, et al. The clinico-anatomic explanation for tibial intraneural ganglion cysts arising from the superior tibiofibular joint. Skeletal Radiol. 2007; 36: 281-292.
5. Smith BW, Jack MM, Powell GM, et al. High-resolution MRI of a peroneal intraneural ganglion cyst arising from the knee joint: illustrative case. J Neurosurg Case Lessons. 2021; 1: 21130.
6. Spinner RJ, Scheithauer BW, Amrami KK. The unifying articular (synovial) origin of intraneural ganglia: evolution-revelation-revolution. Neurosurgery. 2009; 65: 115-124.
7. Spinner RJ, Hébert-Blouin MN, Amrami KK, et al. Peroneal and tibial intraneural ganglion cysts in the knee region: a technical note. Neurosurgery. 2010; 67: 71-78.
8. Young NP, Sorenson EJ, Spinner RJ, et al. Clinical and electrodiagnostic correlates of peroneal intraneural ganglia. Neurology. 2009; 72: 447-452.
9. Nackhwan Kim. Intraneural ganglion cyst of the peroneal nerve occurring after coronavirus disease-19 vaccination: a case report. Hum Vaccin Immunother. 2023; 19: 2265657.

10. Lee SH, Kim SH, Kim HS, et al. Palsy of both the tibial nerve and common peroneal nerve caused by a ganglion cyst in the popliteal area. Medicina. 2024; 60: 876.
11. Visser LH. High-resolution sonography of the common peroneal nerve: detection of intraneural ganglia. Neurology. 2006; 67: 1473-1475.
12. Huntington LS, Talia A, Devitt BM, et al. Management and outcomes of proximal tibiofibular joint ganglion cysts: a systematic review. Knee. 2022; 37: 60-70.
13. Miskovsky S, Kaeding C, Weis L. Proximal tibiofibular joint ganglion cysts: excision, recurrence, and joint arthrodesis. Am J Sports Med. 2004; 32: 1022-1028.
14. Gonzalez MR, Castillo-Flores S, Portmann-Baracco A, et al. Ganglion cysts arising from the proximal tibiofibular joint: treatment approach and associated outcomes - a systematic review. HSS J. 2024; 20: 556-566.
15. Yunga Tigre J, Maddy K, Errante EL, et al. Recurrent peroneal intraneural ganglion cyst: management and review of the literature. Cureus. 2023; 15: 38449.
16. Pemmari A, Mäkelä K, Niemi J, et al. Large intraneural ganglion cyst in the peroneal nerve. Case Rep Neurol. 2022; 14: 44-50.
17. Morena J, Yang B, Lee S, et al. Intraneural ganglion cyst of the peroneal nerve at the lateral knee: a case report and literature review. RRNMF Neuromuscular Journal. 2023.
18. Broekx S, Van Der Straeten R, D'Haen B, et al. Intraneural ganglion cyst of the common peroneal nerve causing foot drop in a 12-year-old child: a review of the literature. Eur J Paediatr Neurol. 2021.

© 2026 Mohammed Boussaidane, et al. This article is distributed under the terms of the Creative Commons Attribution 4.0 International License