Case Report ISSN 2768-6647

Medical and Clinical Case Reports

Gliosarcoma with Complete Osteosarcomatous Differentiation and Extensive Calcification: Case Report

Martha L. Tena-Suck*, Citlaltepetl Salinas-Lara, Carlos Sánchez-Garibay, Luis A. Tirado-García, Sergio Moreno-Jiménez, Jesús Cienfuegos-Meza and Steven Ballantyne-Piña

Instituto Nacional de Neurología y Neurocirugía Manuel Velasco Suárez. México.

***Correspondence:**
Martha L. Tena-Suck, Laboratorio de Neuropatología Experimental Instituto Nacional de Neurología y Neurocirugía Manuel Velasco Suárez, México, Tel/fax: (5255) 56062030. or 56063822. ext 2008.

Received: 13 May 2023; **Accepted:** 20 Jun 2023; **Published:** 26 Jun 2023

Citation: Tena-Suck ML, Salinas-Lara C, Sánchez-Garibay C et al. Gliosarcoma with Complete Osteosarcomatous Differentiation and Extensive Calcification: Case Report. Med Clin Case Rep. 2023; 3(2): 1-5.

ABSTRACT

Gliosarcoma is a rare malignant tumor, grade IV according to WHO. It presents malignant biphasic glial and sarcomatous components. Calcifications and ossification are uncommon findings in these tumors. We reported a rare case of gliosarcoma with extense osseous differentiation and dystrophic calcification. A 51- year-old man that presented intense headache, visual alterations, and with an observed temporal right lobe tumor. He was surgically operated and the histopathological diagnosis was a gliosarcoma with osseous and cartilaginous component. He received radiotherapy with a total dose of 66 grays (GY) in 30 fractions. He then was hospitalized again due to intense headache and pyramidal syndrome. He was surgically intervened and an enormous indurated tumor that showed only dystrophic calcifications, osseous spikes, extensive necrosis and ghost glial cells was observed. Few viable neoplastic cells were determined. This tumor showed loss of Glial acidic fibrillary protein (GFAP), and Vimentin, Ostecondrin, Osteoponin, Ki-67, and blood vessel immunoexpression. Now, it is known that the effect of radiotherapy has influence in the development of tumors (specially in gliomas), but regression with extensive osseous dystrophic calcification after therapy can rarely be observed. Some authors refer to these as "tumoral stones". Extensive calcification could be a sign of a good prognosis as it facilitates extirpation during surgery, although a broaden study in this topic is necessary to affirm this sentence. This is a rare case of gliosarcoma with rapid involution of tumor and stone formation secondary to radiotherapy.

Keywords
Dystrophic calcifications, Osseous and chondroid metaplasia, Radiotherapy, Glioblastoma, Gliosarcoma.

Introduction
Gliosarcoma (GS) is a variant of glioblastoma that is characterized by biphasic neoplastic tissue composed of glial and mesenchymal components. It is a relatively rare and highly malignant brain tumor. It is classified as a variant of glioblastoma (GB) in the 2021 World Health Organization (WHO) Classification of Tumors of the Central Nervous System [1].

It accounts for 1.8 -8% of all glial tumors [2]. GS carry a poorer prognosis than that of GB. Various lines of differentiation are described in the mesenchymal component, but most commonly fibrosarcomatous and pleomorphic sarcoma are present [2,3]. Osteosarcomatous features are exceedingly rare. Immuno-histochemical glial fibrillary acid protein (GFAP) expression was seen only in the malignant glial portion [4]. Mesenchymal chondroblastic and osteosarcomatous differentiation have been reported [3-6]. Possible differential diagnoses and potential histogenesis have been well discussed [5]. GSs are known to arise de-novo, whereas others appear after radiation therapy of malignant gliomas and recurrence and metastasis have been found to be higher than that of GB [4-6].

GB is the most aggressive and most common primary adult brain cancer, accounting for over 80% of primary malignant brain and

other CNS tumors [7]. These patients have a poor prognosis, with a median survival of 6.6 months and a one-year survival rate of only 46% with radiotherapy alone and 77% with radiotherapy and chemotherapy combined [7]. Therapies that improve survival in GB are scarce, with the current standard of care consisting of surgery, radiotherapy, and chemotherapy with temozolomide (TMZ).

The treatment of GS is almost identical to GB, involving surgery, radiotherapy and chemotherapy [5]. This case reveals that ongoing changes in phenotype can occur, especially when the tumor has been treated with chemotherapy and radiotherapy [3,4].

We present a case of a gliosarcoma that initially had osseous differentiation and was irradiated, it was then surgically re-intervened for its complete extraction and in the second biopsy, the tumor showed extense dystrophic calcifications and mature bone formation. Thus, it can be identified as a stone gliosarcoma.

Case Presentation

A 51-year-old man that presented in December 2021 with headache, in February 2022 with reduced visual acuity, and a month later with decreased muscle strength in the left hemibody that progressed until paralysis. On April, he attended with altered alertness, dysphagia to solids and liquids, and required orthopedic support for the extension of his neck. Computed Tomography (CT) and Magnetic Resonance Imaging (MRI) reports showed a mass localized in the right frontal-parietal region of mixed components, with vasogenic edema that displaced the interhemispheric fissure (Figure 1).

Resection of the right parietal tumor was made, histologically the features of the tumor showed a gliosarcoma (Figure 2).

The first biopsy was reported as a gliosarcoma with osseous and cartilaginous components (Figures 2a and 2b). Neoplastic cells showed atypia and pleomorphism (Figure 2c) with extensive necrosis. Masson stain was intensively blue (figure 2d). Immunohistochemistry was positive for GFAP (+++) (Figure 2e), IDH1 (++) (Figure 2f), IDH2 (-), ATRX (+), KI67 30% (Figure 2g) and P53 (+) (Figure 2h), osteoponin, osteoconectin, S-100, and CD31 and CD34 showed abnormal blood vessel proliferation. it was diagnosed as a gliosarcoma grade IV according to WHO.

Radiotherapy included a total dose of 66 grays (GY) in 30 fractions and chemotherapy (temozolomide) was applied. 5 months later he continued with headache and reattends due to right oto-liquorrhea, a metallic taste sensation, tinnitus and ear fullness. MRI showed evident post-surgical changes and right occipito-temporal intraxial neoplastic recurrence with a heterogeneous solid component and focal calcification, the lesion was well delimited that did not compromise midline displacement and perilesional vasogenic edema (Figure 3).

A new surgery was programed and a resection of the recidivating tumor with craniectomy was performed. 20 days later he died and an autopsy was not performed.

In the second biopsy, the gross aspect corresponds to a lesion that measured 8x6x6 cm, it was of a red-brown color, of firm consistency and petrified with white fibrous areas (Figure 4a).

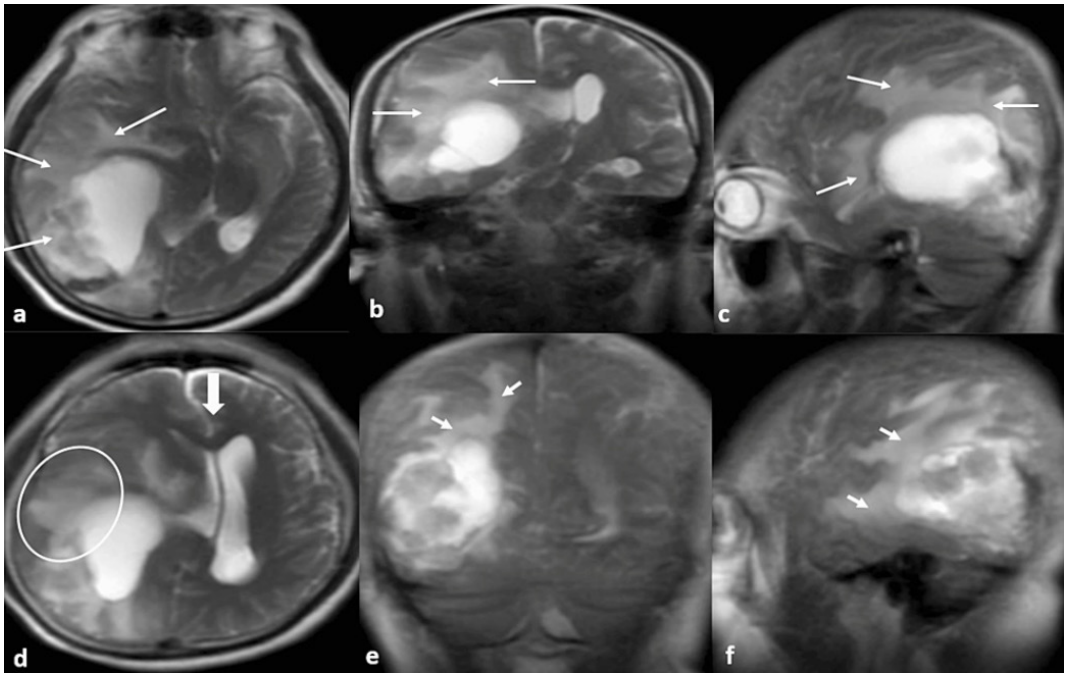

Figure 1: Presurgical findings in imaging.

The simple MRI of the skull in T2 sequence axial (a), sagittal (b) and coronal slices (c). Cystic lesion with moderate solid component, with heterogenous component and extensive right temporoparietal (d) (light arrows), evidencing invasion of premotor portions (d) (circle). Volume effect that displaces the midline (big arrow) associated with significant perilesional edema in (e) and (f) (small arrows).

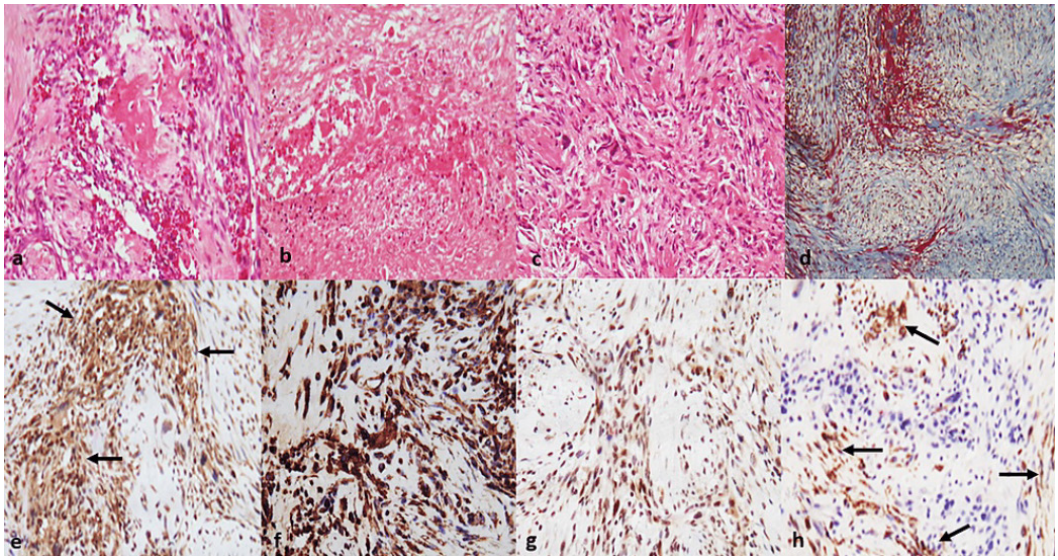

Figure 2: Presurgical histopathological features.

Histologically the first biopsy was reported as a Gliosarcoma with osseous components (a) and (b). Neoplastic cells showed atypia and pleomorphism (c) (H&Ex400). Masson stain was intensively blue in (d) (x400). Immunohistochemistry was positive for GFAP (+++) (arrows in e), IDH1 positive in (f), Ki-67 of 30% in (g) and P53 immunoexpresion (arrows in h) (IHQ stain x200).

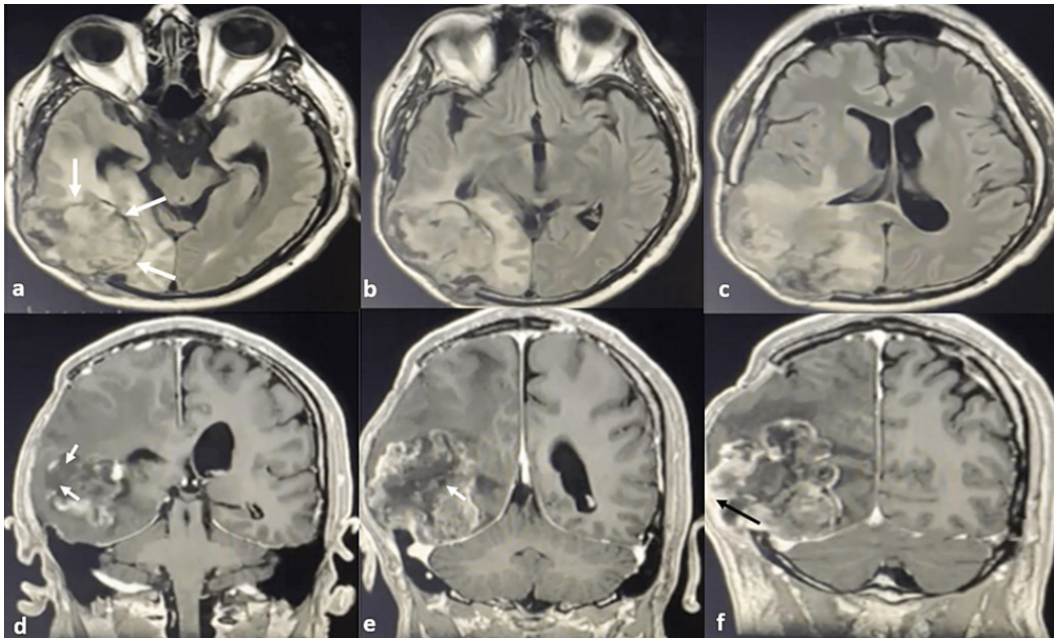

Figure 3: Postsurgical findings in imaging.

The second simple and contrasted MRI of the skull shows a FLAIR sequence in axial (a) to (c) and T1 coronal slices (d) to (f). Evidencing post-surgical changes and right occipitotemporal intraxial neoplastic recurrence with a heterogeneous solid component (white arrows in a) with central hypo intensities (small arrows in d and e) identified that did not compromise midline displacement with perilesional vasogenic edema (black arrow in f).

It was decalcified and multiple osseous spikes were noted (Figure 4b), with osteoid tissue (Figure 4c) in a loose fibrous matrix with occasional neoplastic ghost cells of glial type and blood vessels with extensive necrosis (Figure 4d). Masson stain noted an intense desmoplasia (completely blue) (Figure 4e) and immunohistochemistry was vimentin (+) (Figure 4f), GFAP (+) (Figure 4g), osteocondrin (+) (Figure 4h), osteoponin (+) and CD31(Figure 4i) and CD34 (Figure 4j) showed abnormaly weak immunodepression. The Ki-67li was absent. It was reported as a gliosarcoma with extensive osteoid component. Based on the histological findings and immunohistochemistry stain a diagnosis of Gliosarcoma with complete osteosarcomatous differentiation and extensive calcification; cerebral Stone (calcified necrotic gliosarcoma) was made.

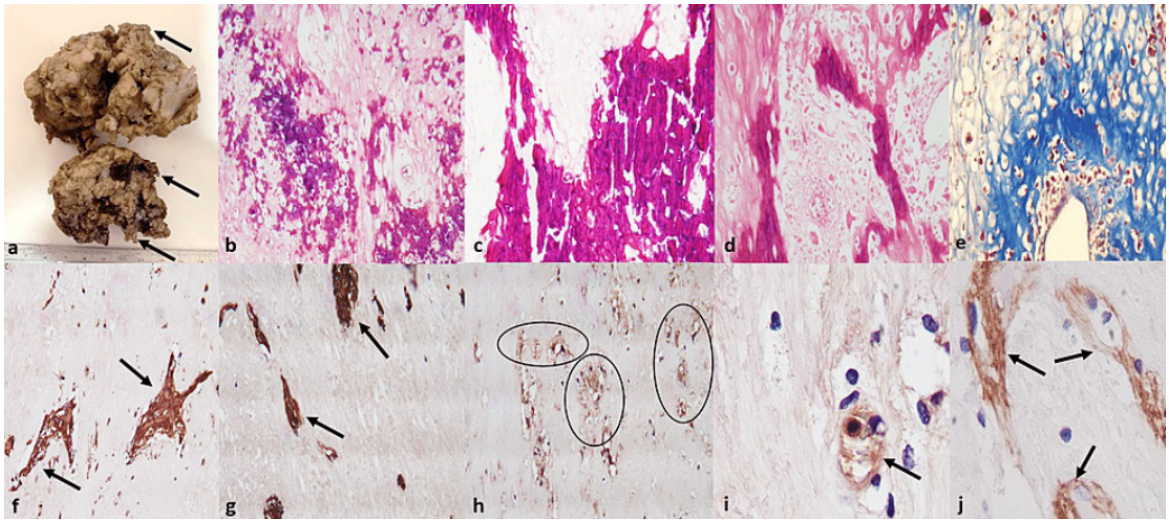

Figure 4: Postsurgical histopathological features.

The second biopsy corresponded to a lesion that measured 8x6x6 cm, it was of a reddish-brown color, of firm consistency and petrified with white fibrous areas (a). Histologically a dense dystrophic calcification with osseous spikes were noted (arrows in a) with osteoid tissue (b) and (c) in a loose fibrous matrix with occasional neoplastic phantom cells of glial type and blood vessels with extensive necrosis in (d)(H&Ex400). Masson stain noted an intense desmoplasia (completely blue) in (e) and immunohistochemistry was only vimentin (arrows in f), GFAP in (arrows in g) and osteoponin positive immunoexpression in (circles in h), and a few walls of blood vessels positive for CD31(arrow in i) and CD34 (arrows in j) (IHQ stain, original magnification x200).

Discussion

The histogenesis of the sarcomatous component of gliosarcoma has been a matter of discussion since its initial description. This neoplasm is supposed to arise secondarily from the neoplastic transformation of stromal cells, which increase as a response of the host against the infiltration of malignant neoplastic cells, The epithelial-mesenchymal transition (EMT) is the conversion of cells with an epithelial phenotype into cells with a highly motile fibroblastic or mesenchymal phenotype. EMT is a serious mechanism in embryonic development, chronic inflammation and fibrosis, and is measured to play a key role in tumor progression and metastasis.

Endothelial cells, histiocytes, fibroblasts, and vascular smooth muscle cells have all been considered potential cells of origin of the sarcomatous component. While morphological studies suggested an evolution of sarcomatous component from microvascular proliferations within a highly malignant glial tumor, recent genetic studies revealed the presence of identical p53, PTEN and IDH1 mutations and similar chromosomal imbalances and cytogenetic alterations in both components of GS, suggesting a monoclonal origin [7].

Brain calcification can be either physiological or pathological. Pathological calcification occurs due to a wide spectrum of causes, including congenital disorders, infections, endocrine/metabolic diseases, cerebrovascular diseases, and neoplasms. Cancer metastasis should be considered as a differential diagnosis when calcified or hemorrhagic masses are detected in middle-aged and elderly patients [8], and typically occur in deteriorated or necrotic tissue. It is related with multiple clinical circumstances, such as collagen vascular diseases. It involves the deposition of calcium in soft tissues despite no generalized disorder in the calcium or phosphorus metabolism, and this is often seen at sites of previous inflammation or damage or hypoxic changes.

Calcification may be seen in gliomas, especially in oligodendrogliomas and in mixed gliomas that have a benign histological appearance. It is unusual in medulloblastomas [9], low grade astrocytomas (pilocytic astrocytoma) [10], oligodendrogliomas and glioblastomas [11]. Histological markers suggesting a better prognosis in glioblastomas include the presence of giant cells and differentiation, as well as calcified brain metastases from osteosarcoma [12], and other carcinomas [13,14]. Among the differential diagnosis of brain intraparenchymal calcifications, metastases are considered uncommon and found predominantly in patients treated with radiotherapy (RT) [5,6,13,14].

We report a case of dystrophic calcification and stone formation in a patient with gliosarcoma, a topic that has been scarcely reported. There has only been one report of a gliosarcoma with osteosarcomatous differentiation [3], compared to the others that have described osseous metaplasia [8,15-17]. The extracellular fluids are supersaturated with calcium phosphate, but inhibitors such as matrix gla protein, osteoconectin and osteoponin prevent crystal deposition under normal physiological conditions [18]. Injured cell membranes escape calcium ions into cells, and these ions are subsequently concerted by mitochondria to levels that form crystals [2,4]. It has also been proposed that necrosis creates an acidic environment that lacks calcification inhibitors [19]. Hydroxyapatite crystals are formed first within the protective

microenvironment of the membrane micro space [19]. In our case we observed the loss of IHD1, IDH2, p53, GFAP, Vimentin, osteoponin, osteoconectin, ATRX and Ki-67. CD31 and CD34 showed abnormal blood vessels.

Tuettenberg J. et al. [20], Described the application of Temozolomide to cultivated glioma endotelial cells; they demonstrated that this drug inhibits endothelial proliferation to an extent of 50%, as well as these cells have a particularly high sensitivity to this drug (tenfold compared to others). Furthermore, side effects we could identify were the loss of vessels and endothelial proliferation as well as, mesenchymal proliferation and finally fibrosis.

Conclusions

We present a rare case of gliosarcoma with osseous and cartilaginous metaplasia that was radiated and afterwards presents clinic worsening, he was surgically reintervened and the biopsy corresponded to extensively calcified with mature bone formation in tumor with ghost cells and few viable neoplastic cells. The tumor disappeared post-radiotherapy. Unfortunately, patient's conditions weren't favorable. This is a rare case of gliosarcoma with rapid involution of tumor and stone formation. It could be a beneficial condition in the surgical management as it can be more easily extirpated, although a broaden study on this specific topic is needed in order to establish a prognostic relation.

Disclosures

Human subjects: Consent was obtained or waived by all participants in this study. National Institute of Neurology and Neurosurgery Ethics Committee issued approval Not required. In this institution case reports need an autorization for the approval of surgical procedures, laboratory studies and other procedures; not particularly in investigation protocols. We use paraffine blocks that do not involve the patients directly. For any surgical procedure, the patient has to sign a specific form, otherwise these procedures cannot be made. Only in the case of multiple patients, a specific protocol is submited to the hospital´s comittee.

References

1. Louis D, Perry A, Wesseling P, et al. The 2021 WHO Classification of Tumors of the Central Nervous System: a summary. 2021; 23: 1231-1251.
2. Lieberman KA, Fuller CE, Caruso RD, et al. Postradiation gliosarcoma with osteosarcomatous components. Neuroradiology. 2001; 43: 555-558.
3. Chen Y, Zhou S, Zhou X, et al. Gliosarcoma with osteosarcomatous component: A case report and short review illustration. Pathol Res Pract. 2022; 232: 153837.
4. Alatakis S, Stuckey S, Siu K, et al. Gliosarcoma with osteosarcomatous differentiation: review of radiological and pathological features. J Clin Neurosci. 2004; 1: 650-656.
5. Charfi S, Ayadi L, Khabir A, et al. Gliosarcoma with osteosarcomatous features: a short-illustrated review. Acta Neurochir Wien. 2009; 151: 809-813.
6. Barut F, Kandemir NO, Ozdamar SO, et al. Turk Gliosarcoma with chondroblastic osteosarcomatous differentation: report of two case with clinicopathologic and immunohistochemical features. Neurosurg. 2009; 19: 417-422.
7. Ruichong MA, Alexe DM, Pereira EA. Primary gliosarcoma: epidemiology, clinical presentation, management, and survival. Journal of Neurosurgical Sciences. 2020; 64: 341-346.
8. Schittenhelm J, Erdmann T, Maennlin S, et al. Gliosarcoma with chondroid and osseous differentiation. Neuropathology. 2007; 27: 90-94.
9. Tashiro Y, Kondo A, Aoyama I, et al. Calcified metastatic brain tumor. Neurosurgery. 1990; 26: 1065-1070.
10. Futane S, Salunke P, Kapoor A, et al. Calcified rock-like medulloblastoma. Pediatr Neurosurg. 2013; 49: 60-61.
11. Dash C, Moorthy S, Garg K, et al. Intraventricular Pilocytic Astrocytoma: A Single Centre Experience. Neurol India. 2022; 70: 1468-1474.
12. Bhatoe HS, Kumar H. Calcified occipital glioblastoma. Neurol India. 2004; 52: 130-150.
13. De Pablo-Fernández E, Gómez-Herrera JJ, Sierra-Hidalgo F, et al. Calcified brain metastases from osteosarcoma. Can J Neurol Sci. 2013; 40: 247-248.
14. Romano RG, Silvestri G, Ravetti JL, et al. Calcified brain metastases may be more frequent tan normally considered. Eur Radiol. 2021; 31: 650-657.
15. Cambruzzi E, Pêgas KL. Osseous metaplasia in gliosarcoma: an unusual histologic finding. Case report. Jornal Brasileiro de Patologia e Medicina Laboratorial. 2014; 50: 159-164.
16. Yao K, Qi X, Mei X, et al. Gliosarcoma with primitive neuroectodermal, osseous, cartilage and adipocyte differentiation: a case report. International Journal of Clinical and Experimental Pathology. 2015; 8: 2079-2084.
17. Tyagi I, Majumdar K, Mehta S, et al. Gliosarcoma with osseous tissue: an occasional metaplastic component. Brain Tumor Pathology. 2012; 30: 40-44.
18. Giachelli CM. Ectopic calcification: gathering hard facts about soft tissue mineralization. Am J Pathol. 1999; 154: 671-675.
19. Verfaillie S, De Smet L, Leemans A, et al. Acute carpal tunnel syndrome caused by hydroxyapatite crystals: a case report. J hand Surg Am. 1996; 21: 360-362.
20. Tuettenberg J, Grobholz R, Korn T, et al. Continuous low-dose chemotherapy plus inhibition of cyclooxygenase-2 as an antiangiogenic therapy of glioblastoma multiforme. J Cancer Res Clin Oncol. 2005; 131: 31-40.