Case Report ISSN 2689-1093

Surgical Research

Intestinal Perforation Secondary to Ingested Toothpick in a 25-Year-Old Male with Pica Disorder: A Case Report

Elham El Darazi, PhD[1,2]* and Elias El-Khoury, MD, FACS, FEBS[3]

[1]*Faculty of Public Health, Department of Nutrition and Food Sciences, Université Sainte Famille, Batroun, Lebanon.*

[2]*Faculty of Public Health, Department of Nutrition, Lebanese University, Lebanon.*

[3]*Dr. Sulaiman Al Habib Hospital, Riyadh, Saudi Arabia.*

***Correspondence:**

Elham El Darazi PhD, Faculty of Public Health, Department of Nutrition and Food Sciences, Université Sainte Famille, Batroun and Lebanese University, Lebanon.

Received: 02 Oct 2026; **Accepted:** 03 Nov 2026; **Published:** 14 Nov 2026

Citation: Elham El Darazi, Elias El-Khoury. Intestinal Perforation Secondary to Ingested Toothpick in a 25-Year-Old Male with Pica Disorder: A Case Report. Surg Res. 2026; 8(6): 1-2.

ABSTRACT

Perforation of the gastrointestinal tract due to foreign body ingestion is an uncommon cause of acute abdomen in young adults, occurring in less than 1% of foreign body ingestion cases [1]. We report the case of a 25-year-old male who presented to the emergency department with severe right lower quadrant abdominal pain. Preoperative CT scanning demonstrated a radiodense foreign body in the distal ileum. Diagnostic laparoscopy revealed small bowel perforation caused by an ingested wooden toothpick, which was successfully removed. Detailed clinical history and a targeted Pica Syndrome questionnaire revealed a history of habitual ingestion of non-nutritive, sharp foreign objects, including toothpicks and fish bones. This case highlights the clinical presentation of bowel perforation secondary to Pica syndrome and emphasizes the necessity of targeted behavioral questionnaires in postoperative evaluation.

Keywords

Pica syndrome, Gastrointestinal perforation, Foreign body ingestion, Small bowel perforation, Toothpick ingestion
Acute abdomen, Diagnostic laparoscopy.

Case Presentation

A 25-year-old male presented to the Emergency Department with sudden-onset, severe abdominal pain localized to the right lower quadrant. Physical examination demonstrated localized tenderness, guarding, and rebound tenderness, suggestive of localized peritonitis. A contrast-enhanced CT scan of the abdomen and pelvis identified a linear radiodense foreign body in the distal ileum. Due to acute symptoms and clinical suspicion of bowel perforation, the patient underwent diagnostic laparoscopy. Fibrinous exudate was visualized over the distal ileum, surrounding a perforated small bowel loop where a wooden toothpick was found traversing the ileal wall (Image 1). The toothpick was safely extracted, the perforation site repaired (Image 2), and abdominal lavage performed.

Following surgical recovery, detailed history-taking and a structured Pica Syndrome Questionnaire were administered to the patient as following:

Ingested Substances & Behavior Profile

1. **Types of Items Ingested:** Which non-nutritive or non-food items do you regularly chew on or swallow?
2. **Frequency & Duration:** How frequently do you ingest these objects (e.g., daily, weekly), and how long has this behavior been ongoing?
3. **Intentionality:** Do you swallow these objects deliberately due to a direct urge/craving, or do you chew on them habitually until they are swallowed accidentally?

Psychological & Sensory Triggers

1. **Cravings & Sensory Drive:** Do you experience specific cravings or sensory satisfaction (e.g., texture, biting sensation, resistance) when placing items like toothpicks or fish bones in your mouth?
2. **Stress & Emotional Associations:** Does your tendency to

ingest these items increase during times of stress, anxiety, restlessness, or boredom?

3. **Risk Awareness:** Prior to this episode, were you aware that swallowing items like toothpicks or fish bones could cause severe internal injuries or surgical emergencies?

Medical & Psychiatric Screening

- **Previous Ingestion History:** Have you ever experienced abdominal pain, bowel blockages, or bleeding in the past after swallowing toothpicks, fish bones, or other objects?
- **Nutritional & Psychological Evaluation:** Do you have any known history of severe anemia, iron deficiency, obsessive-compulsive behaviors, or other psychiatric conditions?

The patient disclosed a prolonged history of Pica syndrome for more than one year on weekly basis, specifically reporting periodic cravings for and deliberate/habitual ingestion of sharp non-food items, including toothpicks and fish bones. Each time he experiences satisfaction and this tendency increases during stress, He is totally aware of the consequences. No known history of psychiatric illness or metabolic disorder were identified.

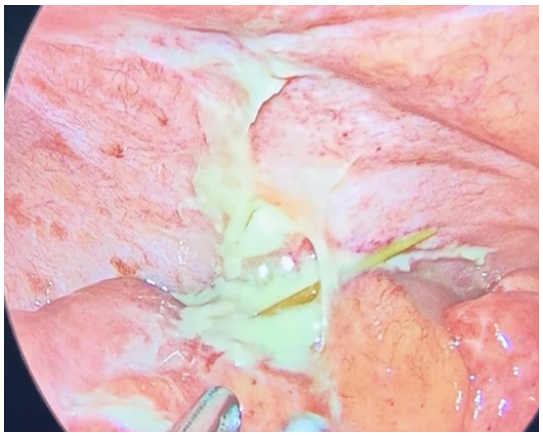

Image 1

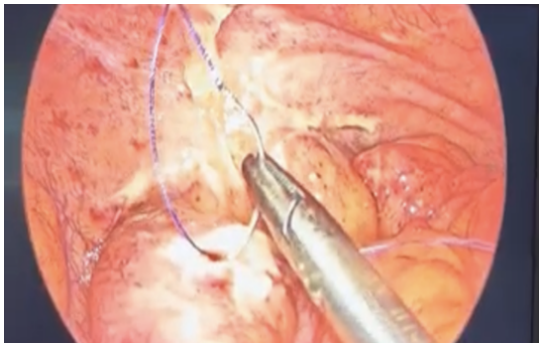

Image 2

Discussion

Ingested foreign bodies pass through the gastrointestinal tract uneventfully in over 90% of cases and perforation occurs in less than 1% of patients [1], most commonly at sites of natural luminal narrowing or acute angulation, such as the distal ileum and ileocecal region [2]. As seen in this case, wooden toothpicks can mimic linear radiodense structures (such as fish bones) on CT imaging due to fluid absorption, surrounding hyperdense inflammatory reactions, local edema, or misinterpretation of radiodensity [2,3]. Diagnostic laparoscopy provides both immediate visualization and minimal-access therapeutic intervention for extraction and repair [4]. Pica is defined by the DSM-5 as the persistent eating of non-nutritive, non-food substances for at least one month. While often identified in pediatric populations [5], adult pica is frequently associated with psychiatric conditions, obsessive-compulsive spectrum disorders, or severe nutritional deficiencies [6]. In this patient, repetitive ingestion of sharp items—specifically toothpicks and fish bones—created a high risk for gastrointestinal injury, leading to mechanical wall erosion and transmural ileal perforation. Recognizing Pica syndrome in acute surgical patients is crucial to initiate multidisciplinary care (psychiatry, clinical psychology, and nutrition) to prevent recurrent life-threatening ingestions [6].

References

1. Vo NQ, Nguyen LD, Chau THT, Tran VK, et al. Toothpick—a rare cause of bowel perforation: case report and literature review. Radiol Case Rep. 2020; 15: 1799-1802.
2. Kumar D, Venugopalan Nair A, Nepal P, et al. Abdominal CT manifestations in fish bone foreign body injuries: What the radiologist needs to know. Acta Radiol Open. 2021; 10: 1-12.
3. Kuzmich S, Burke CJ, Harvey CJ, et al. Perforation of gastrointestinal tract by poorly conspicuous ingested foreign bodies: radiological diagnosis. Br J Radiol. 2015; 88: 20150086.
4. Majjad I, Shubietah ARM, Alaqra Y, et al. Perforation of ileum by unnoticed toothpick ingestion presenting as acute appendicitis: A case report. Int J Surg Case Rep. 2023; 102: 107841.
5. Aydin E, Bent S, Ayan B. Atypical Presentation of Multiple Foreign Body Ingestion. APSP J Case Rep. 2017; 8: 7.
6. Guinan D, Drvar T, Brubaker D, et al. Intentional Foreign Body Ingestion: A Complex Case of Pica. Case Rep Gastrointest Med. 2019; 2019: 7026815.

© 2026 Elham El Darazi, et al. This article is distributed under the terms of the Creative Commons Attribution 4.0 International License