

Management of Adnexal Masses During Pregnancy: A Literature Review

Carbonaro A, Distefano R, Stracquadanio M*, Genovese F, Ciotta L and Palumbo M

Institute of Obstetric and Gynecological Pathology, Santo Bambino Hospital, University of Catania, Italy.

*Correspondence:

Mariagrazia Stracquadanio, Istituto di Patologia Ostetrica e Ginecologica, Ospedale Santo Bambino, Catania. Tel: 3337979357
Email: mariagrazia.stracquadanio@gmail.com.

Received: 20 August 2018; **Accepted:** 17 September 2018

Citation: Carbonaro A, Distefano R, Stracquadanio M, et al. Management of Adnexal Masses During Pregnancy: A Literature Review. *Gynecol Reprod Health.* 2018; 2(5): 1-10.

ABSTRACT

Although the exact incidence of adnexal masses in pregnancy is not clear, its occurrence is considered very common. The majority of them are functional cysts (follicular, corpus luteum and theca lutein cysts), dermoid cysts and cystadenomas, and they resolve spontaneously, but a considerable percentage can be malignant.

The use of ultrasounds in conjunction with IOTA's guidelines is crucial in order to stratify the risk and help the physician to determine the management. The very recent ADNEX model, developed by IOTA's group, opens up some interesting possibilities in this scenario.

Management can be conservative, surgical and chemotherapeutic depending on the size, malignancy risk and gestational age.^[1,2] In this study we reviewed the epidemiology of adnexal masses during pregnancy and their potential complications, the available diagnostic procedures and the possible management options.

Keywords

Adnexal mass, Pregnancy, Ultrasound

Introduction

Epidemiology

The detection rate of adnexal masses in pregnant women has increased over the time [1,2] according to a recent study the incidence is increased by 1.5 percentage points from 2003 to 2011 [3] due to the frequent use of ultrasonography in the first trimester. The reported incidence of adnexal masses in pregnancy widely varies and it is dependent on the criteria defining the mass, including size and longevity of the lesion [1]. Some Authors state that the incidence of adnexal masses during pregnancy ranges from 1 in 81 pregnancies to 1 in 8,000 pregnancies [4]. Regarding adnexal masses complicating pregnancy some other Authors report an incidence ranging from 1 in 81 to 1 in 2,500 childbirth, with an average of 1 in 600 [5,6]. These large variations are due to different definitions of a clinically significant mass, different methods of detection, and different type of population studied [5]. The prevalence of adnexal masses in pregnancy ranges from 1/76 to 1/2328 deliveries [7].

Adnexal masses

The term “adnexal mass” refers to any new formation derived from the adnexa: fallopian tubes and ovaries. The majority of the adnexal masses develops from the ovary and they can be defined as benign, not requiring an invasive treatment: functional cysts and organic cysts. Organic cysts might have malignant aspects and require a specific treatment with the use of surgery and/or chemotherapy [8,9]. Adnexal cysts represent a very common benign condition that affects many women during both premenopausal and post-menopausal period, and they are the most common heteroplasia found in pregnant women. Functional cysts derive from an anomaly in the ovarian functioning, without any pathological organic processes undergoing them.

Follicular cysts, the most common ones, appear when ovulation doesn't occur and a follicle doesn't rupture which leads to increased fluid inside, causing the distension of the Graaf follicle. They appear as rounded, unilocular formations, with sizes ranging from 3 and 10 cm, usually containing a yellowish fluid.

Luteinic cysts are frequent and they are due to accumulation of yellowish liquid or blood inside a corpus luteum after ovulation.

They usually are 3 cm in diameter and their walls are thicker than follicular cysts.

Cystic corpus luteum forms normally after ovulation and persists for 5-9 weeks during pregnancy. This cyst produces progesterone before the placenta and it is essential to the maintenance of the pregnancy. Usually it degenerates from the eighth week. The ultrasounds images of the cystic corpus luteum can be various because of the hemorrhagic content: they can appear as simple or complex masses, and they are characterized by a peripheral ring of color at Doppler scan, called “ring of fire”. The size of these cysts ranges from 2.5 up to 6 cm. The walls of corpus luteum cysts are thicker than follicular cysts [10,11].

Theca lutein cysts form when a follicle doesn't rupture and they are characterized by hyperplasia of the theca and granulosa cells. They are more frequently bilaterals and of variable size.

Organic cysts (or cystic neoplasia) derives from histological changes of the ovarian tissues, and they can originate from the epithelial, stromal or germinal tissue.

Serous cystadenomas are the most frequent ovarian neoplasias, originating from coelomic mesothelium, mostly unilaterals (bilaterals in 30% of the cases) variable in size till 15 cm. They can be distinguished in a simple form with smooth walls and in papillary form, containing vegetations inside or calcifications called “psammoma body”. In 20% of cases they are malignant [12,13].

Among benign ovarian tumors the biggest is the mucinous cystadenoma, reaching even 40-50 cm, it can cause circulatory and respiratory disorders. Its external surface is opaque or translucent, blue or grayish, mostly unilateral with a malignant transformation rate of 5% [9].

Endometriotic cysts, also known as “endometriomas” or “chocolate cysts”, are the result of the implantation of ectopic endometrial mucosa into the ovaries; they are filled up with blood which gives them the typical brown color. In 50% of cases they are bilateral, and their dimensions range from a few millimeters to 15 cm [9]. On ultrasound, there is a specific sign: the presence of weak intracystic echoes. Solely during pregnancy it is possible to see the decidualization of the endometrioma's wall, which shows vascular solid nodules at the ultrasounds. These findings are also suggestive of a malignant cyst and, thus, MRI is often required [10,11,14,15].

Dermoids cysts are the most common germ cell tumors, bilaterals in 15% of cases, usually unilocular and with a diameter ranging from a few millimeters up to 10 cm. Due to their increased mobility, they are the most of frequent cause of ovarian torsion. At ultrasounds they are very heterogeneous, and sometimes hyperechoic nodules with distal acoustic shadowing can be seen [8,10].

Malignant ovarian masses can originate from all ovarian tissues.

The most frequent one is cystadenocarcinoma and derives from the celomatic epithelium: serous and mucinous cystadenomas are their benign counterpart. Other malignant ovarian masses derive from germ cells such as dysgerminomas, immature teratomas, and yolk sac tumor. Sex-cord stromal tumors are made of different combinations of cells, such as granulosa's and theca's cells, Sertoli's and Leydig's cell and fibroblast; they have a slow development and those frankly malignant are rare.

In very rare cases it's possible to find metastatic tumors from breast, intestinal and gastric cancer [10].

Literature shows that the majority of adnexal masses in pregnancy is benign and is mostly represented by functional cysts (follicular, corpus luteum and theca lutein cysts), dermoid cysts and cystadenomas. Nevertheless malignant tumors should be taken in consideration, since the risk of malignancy varies from 0.1% and 10% (Table 1) [4,7,16-20].

Clinical Presentation

Adnexal masses are usually asymptomatic during pregnancy, and they are incidentally diagnosed at the US or during the caesarean section. Only a small percentage of women have symptoms such as pelvic pain. The masses that persist throughout the entire pregnancy are associated with a higher risk of complications with a mostly characteristic clinical presentation [15,19].

Ultrasound


Ultrasound is particularly important when the mass is not well defined or when pelvic examination is limited by discomfort. In order to increase the accuracy of the method and the detection rate for malignancies, both transabdominal and transvaginal scan should be performed together as complimentary techniques [6,10,20-22]. The ultimate goal of the ultrasound evaluation is to stratify the risk and to help the physician in determining those adnexal masses which require only observational conservative management and the other tumefactions requiring surgical intervention [23].

The use of the rules described by the IOTA group (International Ovarian Tumor Analysis) in the ultrasound evaluation of pre- and post-menopausal women has shown high sensitivity and specificity in stratifying the risk of malignancy, and even though there are not official studies on the performance of these models during pregnancy, IOTA's guidelines have proven to be solid even in pregnant women according to some studies [2,18,19,22].

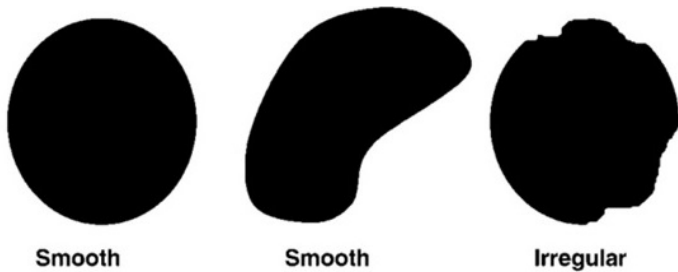
First, to describe the ovarian mass with a standardized method the following terminology should be used:

- Cystic content: it could be described as anechoic (black), low-level echogenic, ‘ground glass’ appearance (homogeneously dispersed echogenic cystic content), hemorrhagic (with internal thread-like structures, that can sometimes appear as star-shaped), or mixed echogenic (Figure 1).
- Presence of solid papillary projections: defined as any solid projections into the cyst cavity from the cyst wall with a

height greater than or equal to 3 mm.



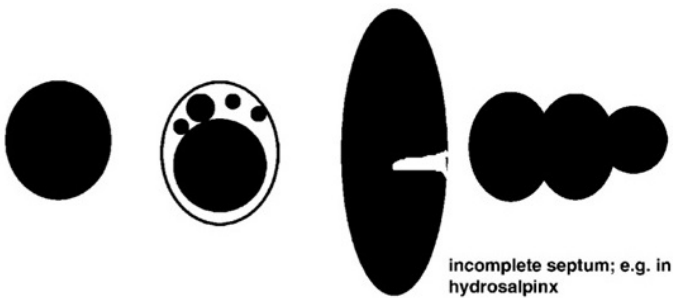
The regularity of the internal wall: it could be regular or irregular (Figure 2).



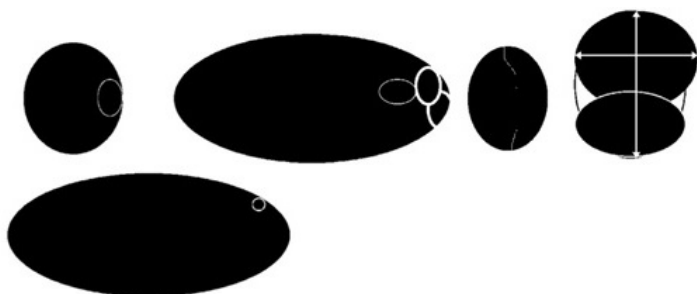
- The regularity of the internal wall: it could be regular or irregular.
- Presence of septa: defined as a thin strand of tissue running across the cyst cavity from one internal surface to the contralateral surface side. They should be described in their thickness and number.

Morphologic classification: All the lesions are classified morphologically in six categories:

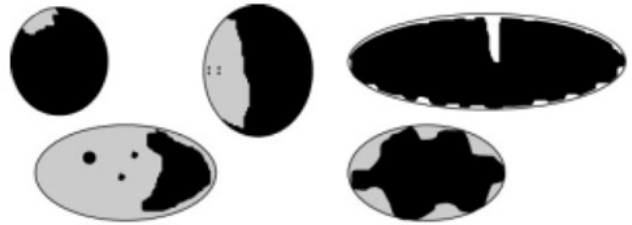
- Unilocular cyst: a cyst without septa, without solid parts or papillary projections (Figure 3).



- Multilocular cyst: a cyst with at least one septum but no measurable solid components or papillary projections (Figure 4).




- Unilocular-solid cyst: a unilocular cyst with a measurable solid component or at least one papillary structure (Figure 5).



- Multilocular-solid cyst: a multilocular cyst with a measurable solid component or at least one papillary structure (Figure 6).



- Solid tumor: a tumor where the solid components comprise 80% or more of the tumor when assessed in a two-dimensional section (Figure 7).



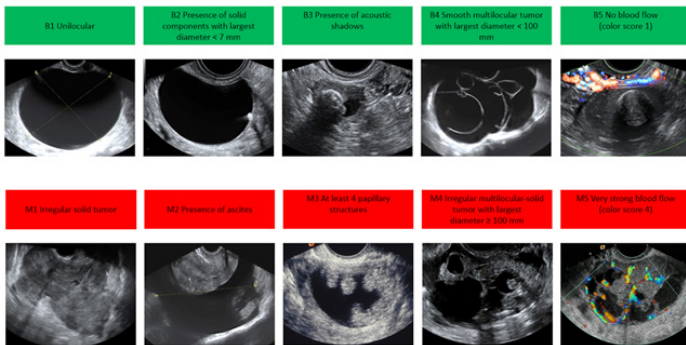
- Vascularization: assigning a score from 1 to 4 based on the amount of blood flow within the septa, cyst walls, or solid tumor areas.
- Other any ultrasound features (acoustic shadows, ascites, etc.) [24].

Based on the features acquired through ultrasound scan is possible to distinguish between potentially benign masses and potentially malignant masses by applying the algorithm designed by the IOTA group in 2008, called “10 Simple Rules” (Figure. 8), with a sensibility of 95% and a specificity of 91% [26,27]. According to this algorithm the features of malignancy (M-rules) are: (1) irregular solid tumor; (2) ascites; (3) at least four papillary structures; (4) irregular multilocular solid tumor with a largest diameter of at least 100 mm; and (5) very high color content on colour Doppler examination.

To predict benign tumors the following five features (B-rules) should be present: (1) unilocular cyst; (2) presence of solid components in which the largest solid part is >7mm in its largest diameter; (3) acoustic shadows; (4) smooth multilocular tumor; and (5) no detectable blood flow on Doppler examination (color score 1).

Malignancy should be suspected if one or more M-rules are present in the absence of a B-rule, vice versa, if one or more B-rules are present in the absence of an M-rule the mass is classified as benign. In 24% of cases the algorithm cannot be applied, because

both M features and B features are present, or none of them are present. Where the 10 Simple Rules yield an inconclusive result, it is possible to rely on a subjective assessment of the ultrasonic findings by an experienced ultrasound examiner [23].



According to a study of Timmerman D. et al, in case the 10 Simple Rules are inconclusive, the evaluation made by an experienced ultrasonographer has a sensibility of 91% (ranging from 88% to 94%) and a specificity of 96% (ranging from 94% to 97%) [26].

According to the same study, the 10 Simple Rules have shown to be very accurate in many scenarios, with a sensitivity of 95% and a specificity of 96%, which makes it the best tool that can be used nowadays for the first level imaging diagnose [26].

This study has therefore concluded that the use of the 10 Simple Rules could potentially improve the treatment of women with adnexal masses, and in all the cases in which the algorithm cannot be used a subjective evaluation is the most accurate imaging investigation if it is performed by an experienced ultrasonographer [26,28].

In 2014 the IOTA group developed a new risk's prediction model, called ADNEX (Assessment of Different NEoplasias in the adneXa), which is capable of distinguish among 5 types of adnexal tumors: benign, borderline, stage I and II, stage III and IV, and metastatic. This new model is based on three clinical parameter (age, serum CA 125 level and type of center referred) and six ultrasound predictors (maximal diameter of lesion, proportion of solid tissue, presence of more than 10 cyst locules, number of papillary projections, acoustic shadows, and ascites), and among these serum CA-125 level and proportion of solid tissue are the strongest predictors [29,30].

According to the IOTA group and to the following external validation studies [31], the sensitivity and specificity of the ADNEX model when it comes to distinguish between benign and malignant tumor are broadly similar to those obtained with the 10 Simple Rules, and only in some circumstances is slightly higher [30]. The real innovation for the newest algorithm is represented by the ability to discern the stage of malignant tumors and to distinguish between primary tumor and secondary metastatic tumor.

Nonetheless, the ADNEX model is not standardized for adnexal

masses found during pregnancy and its performances in this population must be validated.

Other diagnostic procedures

The majority of the studies we analyzed agree on the safety of MRI during pregnancy, mainly if used after the first trimester [31,32]. Other studies are more cautious [10] and in general all of them advise against the use of Gadolinium contrast agent because its possible adverse effects on the fetus are yet to be clarified [18].

MRI has some advantages over ultrasound (even though nowadays the application of 3D ultrasound in some cases can give similar results): it's capable of producing 3D planar images, better differentiating tissue layers, more accurately analyzing the composition of bigger masses (e.g. leiomyomas, endometriomas and masses with solid components) and of the tissues surrounding the mass [32]. MRI can also define the extension of a malignant tumor [19]. Particularly, MRI is useful to differentiate those masses that on ultrasound appear to be adnexal but in reality originate from other organs [33]. Furthermore, if an advanced stage of malignancy is suspected, magnetic resonance can better examine the retroperitoneum, the abdominal cavity and lymph nodes to highlight their possible involvement [19].

Nonetheless, even if MRI can provide valid diagnostic information and can be considered superior to ultrasound, its application is restricted to cases in which ultrasound results are not clear, masses are too big or when there's a high risk on malignancy and it's necessary to investigate any possible extra ovarian involvement [10].

The application of CT scan is not advised since radiations pose a risk in terms of neurological or cardiological damages for the fetus, along with the risk of developing childhood cancers [2]. According to Hurwitz et al. if MRI is not available, after weighing up the risks for the fetus and the mother, the use of CT may be justified taking some precautions such as: (i) lowering the current tube, (ii) limiting the coverage in z axis (iii) increasing the helical pitch (iv) reducing gantry cycle time. A single multidetector-row computed tomography (MDCT) protocol exposes the foetus to 3.5 cGy; the safe limit of neurological damage is <10 cGy [10,34].

Tumor Markers can be measured at diagnosis, to evaluate the progress of the treatment or during follow-up. These markers are produced not only from cancerous cells but also in response to para-neoplastic conditions (e.g. Inflammation) [32]. For these reasons their sensitivity and specificity are low, and higher levels can be associated also with other benign conditions, as pregnancy itself [35]. In pregnancies complicated by obstetrical problems, the variation of these markers is even greater. The use of tumor markers during pregnancy or in pregnancy following a previous cancer is therefore limited [32].

Cancer antigen 125 (CA 125) is only used in non-pregnant patients to monitor the non-mucinous epithelial ovarian cancer. During pregnancy is increased, with the highest concentration reported

of 550 U/ml in the first trimester, therefore its application is not common due to high risk for false positive [32,36]. Furthermore, most of pregnant patients have a stage I disease and only 50% of tumors at early stages has a CA 125 over 30 UI outside pregnancy [2,36].

Other tumor markers such as alpha-fetoprotein (AFP), lactate dehydrogenase (LDH) and human chorionic gonadotropin (hCG) – normally increased in germ cells tumor – have alerted values during pregnancy [2,5,6,37].

Conversely, pregnancy doesn't impact on HE4 (human epididymis protein 4) levels and HE4 can be useful in doubtful cases of pelvic masses during pregnancy, but further studies are necessary [12,22,38].

Complications

Complications of an adnexal mass in pregnancy are in general similar to those of the non-pregnant population, and can be categorized in 3 general groups: emergent complications of benign or malignant masses that necessitate immediate removal (torsion, rupture), labor obstruction, and malignancy [19]. Although the unique implications of surgery during pregnancy may be considered when determining a management plan, in a urgent clinical situation when maternal health is at risk, surgery should not be delayed and women should be managed as they would be if they were not pregnant [19,22].

Ovarian torsion is defined by a partial or complete rotation of vascular pedicle on its long axis, usually involving the tube and ovary. If torsion persists over 36 to 48 hours, it is considered a surgical emergency, due to the risk of irreversible damage to the functional ovarian tissue [19,39].

Ovarian torsion is the most frequent complication in persistent masses. Its incidence is not clear: according to a study it occurs in 0.1-001% of cases [1], in other study the incidence's rate is around 0.2% and 15% [5], while in an other study the rate of occurrence goes up to 27% [7]. What is certain is that pregnancy increases the risk of torsions, especially during the first two trimester [2,5,10,40]. The reasons for most of ovarian torsions occurring during this period are the higher incidence of functional cysts during the first trimester, which are inherently at a higher risk compared to other masses [9], and the relocation of the ovaries that occurs due to the enlargement of the uterus that pushes the adnexa outside of pelvic region. Other causes are the size of adnexal masses (with a higher risk for masses among 6 and 10cm wide) [17,41] and a possible ovarian stimulation (73% of cases are associated with the use of reproductive assisted techniques) [10,19].

Ovarian torsion occurs mainly on right side, with a ratio of 3:2 between right and left side [42,43]. This could be due to surgeons being more prone to explore the right side of abdomen in order to rule out an acute appendicitis. Another possible explanation is that the sigmoid colon helps preventing torsions of left adnexal masses [44].

Clinical presentation is not specific and it's characterized by abdominal and/or pelvic pain, the evidence of a pelvic/abdominal mass by palpation, nausea, vomit, and in some cases fever and leukocytosis [15,19,45]. The diagnose is therefore difficult and requires a careful medical history that points out risk factors, an attentive physical examination and certainly an ultrasound examination of both sides [10,19].

On ultrasound imaging the ovary appears congested and edematous, and many small cysts can be seen peripherally. Doppler ultrasonography can show absence of blood flow, but only when the torsion is complete. The Whirlpool sign is very specific, and refers to the appearance of vessels coiling in a twisted vascular pedicle on color Doppler [10,19].

Treating this condition requires a surgical procedure via laparoscopy. After detorsion of the adnexa, restoration of blood flow should be assessed: if recoloring and decreasing edema are noted, it is necessary only the aspiration of the hemorrhagic content, while in case of persisting signs of ischemia, adnexectomy is mandatory [19].

The risk of ovarian malignancy is rare in pregnancy, with a reported incidence between 0.5% and 5%. Nevertheless is not an uncommon indication to surgery and it should be taken in consideration [7]. According to some Authors, since the risk of rupture for cysts greater than 5 cm of diameter persists even after the delivery, they should excised during a caesarean section [46].

Even if rare, very large adnexal masses can determine dystocia if they are located near the lower uterine segment and below the presenting part, similar to obstructing fibroids [5]. Goh et al reported a cesarean delivery rate of 25% among women with a large adnexal mass due to arrested labor [17].

Malignancy risk

The risk of ovarian malignancy is rare in pregnancy, with a reported incidence between 2.1% and 13,5% according to Aggarwal et al. [7] or ranging from 1 in 5000 to 1 in 47000 live birth according to Ngu et al [47]. Data cited by De Haan et al., Hoover et al. and Fruscio et al., report similar values: the incidence of malignant adnexal mass during pregnancy is reported to be between 1% and 8% [8,18,37] with mean reported values ranging from 4,2% to 6,1% of cases depending on the published series.

The percentage of malignant tumors or tumors of low malignant potential cited by Whitecar et al. is twice as high as previously reported (with an overall incidence of malignant adnexal masses in pregnancy of approximately 3%) [4]. The Californian study by Leiserowitz based on 4.846.505 patients suggests instead that the incidence rate is lower than 1% [48]. In closing, according to a recent meta-analysis, malignity is present in 0-4.6% of cases [5].

Most malignancies are either of low malignant potential or germ cell tumors, and usually diagnosed in early stage in contrast with malignancies outside of pregnancy: low malignant potential

tumors are almost as common as frankly malignant ones, while in the non-pregnant population borderline tumors only form a small fraction of the total ovarian cancers [5,8,19,48]. Among invasive malignancies, epithelial ovarian cancer is more common than germ cell tumors [2,48].

Management

General principle: There is no consensus in the literature regarding surgical or conservative management of benign adnexal masses during pregnancy [2], and some studies disagree even on the benefits of laparoscopy vs. laparotomy. Women with adnexal masses during pregnancy facing a complication (e.g. ovarian torsion or rupture) should be treated as non-pregnant women, which is with laparoscopic surgery [5,6]. The approach to management of an asymptomatic adnexal mass diagnosed during pregnancy requires a balance between the maternal-fetal risks of surgery, the risks of mass-related complications, and the likelihood of a malignancy, all of which are considered within each patient’s distinct clinical scenario and gestational age [5].

Observation: Expectant management of an asymptomatic adnexal mass without features suggestive of malignancy is reasonable and supported by the literature [5]. The majority of adnexal masses noted on first trimester ultrasound regresses later in gestation, with a 71% to 89% rate of regression for cysts smaller than 5 cm [5,22].

The studies by Zanetta et al, Schmeleretal, and Plateketal support a very low incidence of malignancy (0.3%), even with non-resolving complex masses in pregnancy [37]. These studies suggest that with the use of transvaginal ultrasound for risk stratification and the low likelihood of malignancy in the pregnant population, one may advocate for postponing surgery of even complex masses found in the asymptomatic pregnant patient until postpartum state [37].

In case of persistent masses, the risk of complications such as acute abdomen, dystocia or cancer, should be balanced to the possible risks of an antepartum surgery [19].

According to Naqvi et al. although the true resolution rate of adnexal masses is difficult to estimate secondary to the various clinical scenarios that may prompt removal, it is clear that the majority of smaller masses do appear to resolve and thus may be reasonably managed expectantly [5].

Surgery: Even if we don’t have specific guidelines, many Authors agree that surgery is indicated for masses that persists in the second trimester, voluminous masses larger than 6-8 cm diameter, masses that are symptomatic or that present with an acute abdomen, and with a solid or mixed component (cystic and solid) with suspicion for malignancy [5,48,49] (Table 1).

Symptoms evoking a complication or ascites
Masses larger than 6-8 cm diameter
Solid components, intracystic vegetations or multiocular appearance on ultrasound examination

Table 1: Surgery indications.

French Authors give more specific surgical indications: (1) the persistence of an adnexal mass with no evidence of spontaneous regression over the 14 th -15 th week of amenorrhea, (2) voluminous masses larger than 6-8 cm diameter, (3) symptoms evoking a complication or ascites, and (4) and solid components, intracystic vegetations or multilocular appearance on ultrasound examination, especially in case of low resistance vascularization on septa [50].

Surgical treatment, if not urgent, should in general be delayed until the second trimester because (1) organogenesis has been completed and spontaneous fetal losses due to intrinsic fetal abnormalities have already occurred; (2) the function of corpus luteum has been replaced by the placenta, therefore, if the corpus luteum would be removed due to an ovariectomy or cystectomy, the progressing pregnancy wouldn’t be interrupted; (3) most functional cysts have disappeared; (5) an acceptable operative field is still available, allowing minimal uterine manipulation and low risk of obstetric complications [19].

Surgery performed during the third trimester, may be technically more difficult and result in an adverse obstetric outcome such as preterm labor [19,22]. Besides, labor pain or possible complications would be difficult to differentiate from post-surgical pain. Thus, when an adnexal mass requires operative intervention late in pregnancy, the option of awaiting birth and intervention postpartum should be considered and contrasted with the alternative of a definitive surgery that may require a cesarean delivery [33].

Nonetheless, in those situations in which surgery cannot be delayed to the second trimester, according to a recent study by Minig et al, laparoscopic surgery performed during the first trimester seems to be safe for both the fetus and the mother [51].

Which technique is to prefer, whether laparotomy or laproscopy, is still debated in the literature [51-53]. In the past, surgical intervention for adnexal masses was performed through laparotomy [4,52]. Nowadays laparoscopy has become the standard for adnexal masses’ intervention in non-pregnant women, and its use during pregnancy has increased [4,59].

Benefits of laparoscopy (Table 3) in pregnancy are the same of those in the non-pregnant population, and include decreased postoperative pain, reduced need for narcotic medications, fewer wound infections, shorter hospital stay, lower estimated intra-operative blood loss and less uterine manipulation, with a consequently theoretical lower risk of preterm delivery [5,19,53].

However, some concerns have been raised regarding laparoscopy in pregnancy including the lack of data regarding the effects of a pneumoperitoneum; possible injection of carbon dioxide into the uterine cavity; possible injury to the gravid uterus by a Veress needle, trocar, or surgical instrument; and the potential for fetal acidosis because of maternal conversion of carbon dioxide to carbonic acid [2,37].

LAPAROSCOPY		LAPAROTOMY	
RISKS	BENEFITS	RISKS	BENEFITS
Fetal hypoxia	Shorter hospital stay	Longer hospital stay	No fetal acidosis risk
Fetal loss risk still present	Reduced fetal loss	Postoperative pain that can reduce patient's motility	No fetal hypoxia risk
Uterine wall rupture	Decreased preterm birth	Thromboembolic event	
Fetal acidosis	Decreased postoperative pain		
	Reduced need for narcotic medications		
	Fewer wound infections		
	Lower estimated intra-operative blood loss		

The Society of American Gastrointestinal and Endoscopic Surgeons (SAGES) stated that laparoscopy could be safely performed in any trimester of pregnancy. This society has developed some technical recommendations for performing laparoscopy in pregnant women, which include the following:

(1) patient must be positioned in left lateral position (to minimize inferior vena cava compression); (2) initial access to the abdominal cavity can be safely performed by open surgery (Hasson) with a Veress needle or by optical trocar, as long as the location takes into account the uterine fundal height and previous incisions; (3) CO₂ insufflation with 10-15 mmHg pressure is safe, but intraoperative CO₂ monitoring by capnography is recommended; (4) pneumatic compression devices are recommended in intra- and postoperative period as well as early postoperative ambulation (for venous thromboembolism prophylaxis); (5) tocolytics should not be used prophylactically but should be considered perioperatively in the presence of preterm labor signs [5,19,37].

At the time of this study there aren't prospective studies in the literature confronting laparotomy and laparoscopy in order to state which technique is better [53]. Nonetheless many observational studies have showed that treating adnexal masses with laparoscopic surgery is possible and shouldn't be considered contraindicated during pregnancy [37].

In favor of laparoscopic surgery is the meta-analysis conducted by Yu-Xuan Liu in 2016 that, after analyzing 240 patients in which laparoscopic surgery has been associated with lower post-

operative risks, concluded that laparoscopic surgery could be preferable to laparotomy for suspected adnexal mass during the second trimester of pregnancy [53].

Chemotherapy

If malignancy is identified, management is dependent on the histology and stage of disease. For tumors of low malignant potential, regardless of stage, chemotherapy is generally not recommended [49]. For epithelial malignancies, only well-differentiated cancers that are confined to the ovary (after comprehensive surgical staging) do not need chemotherapy. For all others, a platinum and taxane-based chemotherapy is the standard of care and has been successfully administered in pregnancy [49].

Chemotherapy for germ cell tumors, other than for stage I dysgerminoma, is typically bleomycin, etoposide, and cisplatin (BEP) [2,54]. Clearly, the use of chemotherapy during an ongoing pregnancy carries risks and toxicities not only for the mother but also for the fetus, such as abortion, congenital malformation and neonatal problematic [49,54,55]. These risks are greater during the first trimester because it coincides with organogenesis [49,55,56]. Therefore, if chemotherapy is indicated and can't be postponed, it should be initiated during the second trimester or at the beginning of the third trimester [49,54,56,57]. But considering the risks the choice between delaying treatment and interrupting the pregnancy should discuss with the patient [2]. In many reported cases of advanced disease, patients have decided to interrupt pregnancy when the diagnose was placed at the beginning of the first trimester [54]. When instead the patient wants to proceed with pregnancy neoadjuvant chemotherapy with carboplatin and paclitaxel is recommended until fetal maturity and complete surgery cytoreduction after delivery [57].

Even if the majority of the literature shows positive outcomes both for the fetus and oncological patient, many practitioners do not feel comfortable treating those patients who wish to continue their pregnancies: in the survey conducted by Han et al. to physicians from 14 European countries it appears that 44% of those surveyed stated that they would offer termination of pregnancy as a primary treatment recommendation when malignancy was diagnosed in the first or trimester of pregnancy, and 37% would not administer chemotherapy or radiotherapy when diagnosed in the third trimester of pregnancy [20].

We can therefore say that following studies and longer follow-up are necessary in order to determine oncological safety in these patients.

Materials and Methods

We based our review on Medline and PubMed search and our experience. The aim of our research was to review all the major evidences on the diagnostic process and therapy for the management of adnexal masses during pregnancy.

We searched Medline and PubMed using the terms "ovarian masses", "adnexal masses", "tumor markers", "pregnancy",

“laparoscopy”, and “laparotomy” for including articles by all authors. The bibliography of each article was reviewed to determine any further articles that could be included in this review. Using Google Scholar, we highlighted those studies with the greater citation index. Original research articles were included if they dealt with diagnosis, evaluation, or treatment of adnexal masses in pregnancy. We acquired the complete documents for all

of malignancy that doesn't get over 5% according to most recent data, among which borderline lesions are the most frequent.

In order to determine the right therapy and reduce morbidity due to overtreatment, transabdominal and transvaginal ultrasound examination of the adnexa should be placed from the first trimester of amenorrhea.

In case a significant morphological modifications of an ovarian mass is noted, it is important to take into account the possibility of a decidualised endometrioma, even though we do not have reliable data on its incidence yet.

To this date it is still not possible to define comprehensive guidelines for the management of adnexal masses during pregnancy, and the treatment of choice should be based on the ultrasound findings and particularly on the patient's preferences.

References

- Goh W, Bohrer J, Zalud I. Management of the adnexal mass in pregnancy. *Curr Opin Obstet Gynecol.* 2014; 26: 49-53.
- Mukhopadhyay A, Shinde A, Naik R. Ovarian cysts and cancer in pregnancy. *Best Pract Res Clin Obstet Gynaecol.* 2015; 33: 1-15.
- Nazer A, Czuzoj-Shulman N, Oddy L, et al. Incidence of maternal and neonatal outcomes in pregnancies complicated by ovarian masses. *Arch Gynecol Obstet.* 2015; 292: 1069-1074.
- Whitecar P, Turner S, Higby K. Adnexal masses in pregnancy: A review of 130 cases undergoing surgical management. *Am J Obstet Gynecol.* 1999; 181: 19-24.
- Mariam Naqvi, Kaimal A. Adnexal Masses in Pregnancy. *Clin Obstet Gynecol.* 2015; 58: 93-101.
- Yakasai IA, Bappa LA. Diagnosis and management of adnexal masses in pregnancy. *J Surg Tech Case Rep.* 2012; 4: 79-85.
- Aggarwal P, Kehoe S. Ovarian tumours in pregnancy: A literature review. *Eur J Obstet Gynecol Reprod Biol.* 2011; 155: 119-124.
- Fruscio R, Jorine de Haan, Kristel Van Calsteren, et al. Ovarian cancer in pregnancy. *Best Pract Res Clin Obstet Gynaecol.* 2017; 41: 108-117.
- Mimoun C, Bader G. Masse ovariche: tumori benigni e maligni. *EMC - AKOS Trattato di Med.* 2016; 18: 1-7.
- Yacobozzi M, Nguyen D, Rakita D. Adnexal Masses in Pregnancy. *Semin Ultrasound CT MRI.* 2012; 33: 55-64.
- Caserta L, Giorlandino C, Giorda G, et al. Studio ultrasonografico delle masse ovariche benigne. *G. Ital. di Ostet e Ginecol.* 2009; 31: 183-190.
- Pietro Valerio Foti, Giancarlo Attinà, Saveria Spadola, et al. MR imaging of ovarian masses: classification and differential diagnosis. *Insights Imaging.* 2016; 7: 21-41.
- Mussetto I, Rosa F, Matos J, et al. Ovarian Masses : role of MRI in the differential diagnosis. A systematic approach. *Eur Soc Radiol.* 2017; 1-21.
- Mascilini F, Moruzzi C, Giansiracusa C, et al. Imaging in gynecological disease 10: Clinical and ultrasound

Author	Operations	Maternal	Neonatal
Parker (1996)	12	Cyst rupture	none
Mathevet (2003)	47	none	1 fetal loss
Minig (2016)	13	none	none
Soriano (1999)	39	none	5 miscarriages 1 hypospadias 1 cleft lip
Ngu (2014)	21	none	2 preterm births 2 incomplete miscarriages
Chen (2014)	33	10 cyst ruptures	none
Balthazar (2011)	50	none	none

the studies, and we selected only the ones relevant to this study.

Author	Operations	Maternal	Neonatal
Soriano (1999)	54	2 pulmonary embolism	2 miscarriages 1 TGV
Ngu (2014)	14	none	1 preterm birth 1 fetal loss
Chen (2014)	36	12 cyst ruptures 6 postoperative uterine contractions	none
Balthazar (2011)	51	1 wound infections 7 postoperative ileus	none

Table 3: Maternal and neonatal complications after laparoscopy.

Table 4: Maternal and neonatal complications after laparotomy.

Conclusion

Adnexal masses are rare during pregnancy, with an overall risk

- characteristics of decidualized endometriomas surgically removed during pregnancy. *Ultrasound Obstet Gynecol.* 2014; 44: 354-360.
15. Wendy s Biggs, Sarah Tully Marks. Diagnosis and Management of Adnexal Masses. *Am Fam Physician.* 2016; 93: 676-681.
 16. Xie M, Zhang X, Wang W, et al. Benign pelvic masses masquerading as adnexal cancer during pregnancy on ultrasound: A retrospective study of 5 years. *Mol Clin Oncol.* 2015; 3: 1395-1397.
 17. Goh WA, Rincon M, Bohrer J, et al. Persistent ovarian masses and pregnancy outcomes. *J Matern Neonatal Med.* 2013; 26: 1090-1093.
 18. de Haan J, Verheecke M, Amant F. Management of ovarian cysts and cancer in pregnancy. *Facts views Vis ObGyn.* 2015; 7: 25-31.
 19. Cavaco Gomes J, Cátia Jorge Moreira, Anabela Rocha, et al. Investigation and Management of Adnexal Masses in Pregnancy. *Scientifica.* 2016.
 20. Cordeiro Christina N, Gemignani Mary LM. Gynecologic Malignancies in Pregnancy: Balancing Fetal Risks With Oncologic Safety. *Obstet Gynecol Surv.* 2017; 72: 184-193.
 21. Kurjak A, Zalud I, Alfircvic Z. Evaluation of adnexal masses with transvaginal color ultrasound. *J ultrasound Med.* 1991; 10: 295-297.
 22. Brun JL, Fritel X, Aubard Y, et al. Management of presumed benign ovarian tumors: Updated French guidelines. *Eur J Obstet Gynecol Reprod Biol.* 2014; 183: 52-58.
 23. Timmerman D, Testa AC, Bourne T, et al. Simple ultrasound-based rules for the diagnosis of ovarian cancer. *Ultrasound Obstet Gynecol.* 2008; 31: 681-690.
 24. Timmerman D, Dueholm M, Leone FPG, et al. Terms, definitions and measurements to describe the sonographic features of adnexal tumors: a consensus opinion from the International Ovarian Tumor Analysis (IOTA) group. *Ultrasound Obstet Gynecol.* 2010; 46: 500-505.
 25. Alcázar JL, Pascual MÁ, Olartecoechea B, et al. IOTA simple rules for discriminating between benign and malignant adnexal masses: Prospective external validation. *Ultrasound Obstet Gynecol.* 2013; 42: 467-471.
 26. Timmerman D, Ameye L, Fischerova D, et al. Simple ultrasound rules to distinguish between benign and malignant adnexal masses before surgery: prospective validation by IOTA group. *BMJ.* 2010; 341: c6839.
 27. Timmerman D, Van Calster B, Testa A, et al. Predicting the risk of malignancy in adnexal masses based on the Simple Rules from the International Ovarian Tumor Analysis group. *AmJ Obstet Gynecol.* 2016; 214: 424-437.
 28. Meys EM, Kaijser J, Kruitwagen RF, et al. Subjective assessment versus ultrasound models to diagnose ovarian cancer: A systematic review and meta-analysis. *Eur J Cancer.* 2016; 58: 17-29.
 29. Van Calster B, Van Hoorde K, Valentin L, et al. Evaluating the risk of ovarian cancer before surgery using the ADNEX model to differentiate between benign, borderline, early and advanced stage invasive, and secondary metastatic tumours: prospective multicentre diagnostic study. *BMJ.* 2014; 349: g5920.
 30. Van Calster B, Van Hoorde K, Froyman W, et al. Practical guidance for applying the ADNEX model from the IOTA group to discriminate between different subtypes of adnexal tumors. *Facts, views Vis ObGyn.* 2015; 7: 32-41.
 31. Testa A, Kaijser J, Wynants L, et al. Strategies to diagnose ovarian cancer: new evidence from phase 3 of the multicentre international IOTA study. *Br J Cancer.* 2014; 111: 680-688.
 32. De Haan J, Vandecaveye V, Han SN, et al. Difficulties with diagnosis of malignancies in pregnancy. *Best Pract Res Clin Obstet Gynaecol.* 2016; 33: 19-32.
 33. Glanc P, Salem S, Farine D. Adnexal Masses in the Pregnant Patient A Diagnostic and Management Challenge. *Ultrasound Q.* 2008; 24: 225-240.
 34. Hurwitz L M, Yoshizumi T, Reiman RE, et al. Radiation dose to the fetus from body MDCT during early gestation. *Am J Roentgenol.* 2006; 186: 871-876.
 35. Han SN, Anouk Lotgerink, Mina Mhallem Gziri, et al. Physiologic variations of serum tumor markers in gynecological malignancies during pregnancy: a systematic review. *BMC Med.* 2012; 10: 66-69.
 36. Sarandakou A, Protonotariou E, Rizos D. Tumor markers in biological fluids associated with pregnancy. *Crit Rev Clin Lab Sci.* 2007; 44: 151-178.
 37. Hoover K, Jenkins TR. Evaluation and management of adnexal mass in pregnancy. *AmJ Obstet. Gynecol.* 2011; 205: 97-102.
 38. Gucer F, Kiran G, Canaz E, et al. Serum human epididymis protein 4 can be a useful tumor marker in the differential diagnosis of adnexal masses during pregnancy a pilot study. *S Afr Med J.* 2015; 5736.
 39. Tobiume T, Shiota M, Umemoto M, et al. Predictive factors for ovarian necrosis in torsion of ovarian tumor. *Tohoku J Exp Med.* 2011; 225: 211-214.
 40. Caspi B, Levi R, Appelman Z, et al. Conservative management of ovarian cystic teratoma during pregnancy and labor. *Am J Obstet Gynecol.* 2000; 182: 503-505.
 41. Sherard GB, Hodson CA, Williams HJ, et al. Adnexal masses and pregnancy: a 12-year experience. *Am J Obstet Gynecol.* 2003; 189: 358-362.
 42. Özler S, Efser Oztaş, Ali Özgür Ersoy, et al. Pregnancy with Bilateral Dermoid Cyst and Unilateral Ovarian Torsion: a Case Report. *Cukurova Med J.* 2015; 40: 814-817.
 43. Walid MS, Boddy MG. Bilateral dermoid cysts of the ovary in a pregnant woman: case report and review of the literature. *Arch Gynecol Obstet.* 2009; 279: 105-108.
 44. Chang SD, Yen CF, Lo LM, et al. Surgical intervention for maternal ovarian torsion in pregnancy. *Taiwan J Obstet Gynecol.* 2011; 50: 458-462.
 45. Hasson J, Tsafirir Z, Azem F, et al. Comparison of adnexal torsion between pregnant and nonpregnant women. *Am J Obstet Gynecol.* 2010; 202: 536.e1-536.
 46. Baser E, Erkilinc S, Esin S, et al. Adnexal masses encountered during cesarean delivery. *Int J Gynecol Obstet.* 2013; 123: 124-126.

47. Ngu SF, Cheung VYT, Pun TC. Surgical Management of Adnexal Masses in Pregnancy. *JSLs J. Soc Laparoendosc Surg.* 2014; 18: 71-75.
48. Leiserowitz GS. Managing ovarian masses during pregnancy. *Obstet Gynecol Surv.* 2007; 61: 463-470.
49. Horowitz NS, Hemant Maraj. Management of adnexal masses in pregnancy. *Clin Obstet Gynecol.* 2011; 54: 519-527.
50. Azuar AS, Bouillet-Dejou L, Jardon K, et al. Laparoscopy during pregnancy: experience of the French university hospital of Clermont-Ferrand. *Gynécologie Obs Fertil.* 2009; 37: 598-603.
51. Minig L, Otaño L, Cruz P, et al. Laparoscopic surgery for treating adnexal masses during the first trimester of pregnancy. *J Minim Access Surg.* 2016; 12: 22-25.
52. Soriano D, Yefet Y, Seidman DS, et al. Laparoscopy versus laparotomy in the management of adnexal masses during pregnancy. *Fertil Steril.* 1999; 71: 955-960.
53. Liu YX, Zhang Y, Huang JF, et al. Meta-analysis comparing the safety of laparoscopic and open surgical approaches for suspected adnexal mass during the second trimester. *Int J Gynecol Obstet.* 2017; 136: 272-279.
54. Mancari R, Tomasi-Cont N, Sarno MA, et al. Treatment options for pregnant women with ovarian tumors. *Int J Gynecol Cancer.* 2014; 24: 967-972.
55. Basta P, Bak A, Roszkowski K. Cancer treatment in pregnant women. *Contemp Oncol. (Poznań, Poland).* 2015; 19: 354-360.
56. Koren G, Carey N, Gagnon R, et al. Cancer Chemotherapy and Pregnancy. *J Obstet Gynaecol Canada.* 2013; 35: 263-278.
57. Amant F, Brepoels L, Halaska MJ, et al. Gynaecologic cancer complicating pregnancy: An overview. *Best Pract Res Clin Obstet Gynaecol.* 2010; 24: 61-79.
58. Nezhat F, Nezhat C, Allan C J, et al. Clinical and histologic classification of endometriomas. Implications for a mechanism of pathogenesis. *J Reprod Med.* 1992; 37: 771-776.
59. Ueda Y, Enomoto T, Miyatake T, et al. A retrospective analysis of ovarian endometriosis during pregnancy. *Fertil Steril.* 2010; 94: 78-84.
60. Yuen PM, Ng PS, Leung PL, et al. Outcome in laparoscopic management of persistent adnexal mass during the second trimester of pregnancy. *Surg Endosc.* 2004; 18: 1354-1357.
61. Maggiore ULR, Ferrero S, Mangili G, et al. A systematic review on endometriosis during pregnancy: Diagnosis, misdiagnosis, complications and outcomes. *Hum Reprod Update.* 2016; 22: 70-103.
62. Sammour RN, Zvi Leibovitz, Israel Shapiro, et al. Decidualization of Ovarian. 2005; 24: 1289-1294.
63. Benaglia L, Somigliana E, Calzolari L, et al. The vanishing endometrioma: the intriguing impact of pregnancy on small endometriotic ovarian cysts. *Gynecol Endocrinol.* 2013; 29: 863-866.