Research Article ISSN 2639-944X

Journal of Medical - Clinical Research & Reviews

Measurement Analysis and Clinical Research of Lumbar Ligamentum Flavum and Lamina

Ding Ming* and Li Chao

Department of Orthopedics, Affiliated Hospital of Qingdao Binhai University, Qingdao, China.

*Correspondence:
Ding Ming, Department of Orthopedics, Affiliated Hospital of Qingdao Binhai University, Qingdao, China.

Received: 01 Oct 2023; **Accepted:** 03 Nov 2023; **Published:** 10 Nov 2023

Citation: Ding Ming, Li Chao. Measurement Analysis and Clinical Research of Lumbar Ligamentum Flavum and Lamina. J Med - Clin Res & Rev. 2023; 7(11): 1-8.

ABSTRACT

Objective: To measure and analyze adult lumbar ligamentum flavum and lamina on imaging and cadaver specimens and study their clinical significance.

Methods: Through lumbar spine MRI, CT imaging research and analysis and anatomical study of cadaveric upper lumbar spine, it was found that the lumbar lamina in the sagittal position is not a flat plate, but consists of a straight upper half and a backward curved lower half. Therefore, we proposed the concept of dividing the lamina into two parts: the "lamina body" which is straight above and the "lamina wing" which is curved below. There is a certain angle between the two parts, and the acute angle between them is called It is the "body wing angle". Therefore, we selected 30 elderly patients who underwent lumbar spine MRI and CT examinations in our hospital from March 2020 to December 2022 during the same period to conduct a measurement study of the ligamentum flavum and lamina on imaging, including 13 males and 17 females. Age 60 to 78 years old (67.2±5.5 years old), height 149 to 175cm (162±6.7cm), a total of 137 valid vertebral bodies were obtained for measurement. Because the lamina is displayed more clearly on CT, the lamina was measured. CT images were used for measurement, and the course and distribution of the ligamentum flavum were evaluated using MRI. Divide one side of the lamina into 3 equal parts, measure the length of the lamina body and lamina wings at the inner and outer 1/3 respectively, and take the average value; During the same period, anatomical measurements of the solid ligamentum flavum and lamina were performed on the lumbar vertebrae of 5 elderly cadavers (the specific age and height were unknown), with a total of 25 vertebral bodies. The lamina on one side was divided into 3 equal parts using the same method, and the inner and outer 1 were measured respectively. /3 The length of the lamina body, lamina wing, and body wing angle are averaged; the origin, end, and course of the ligamentum flavum of the lumbar vertebra are dissected to clarify its distribution characteristics. In order to analyze the clinical causes of secondary hypertrophy and wrinkles of the adjacent ligamentum flavum, determine the scope of laminectomy during posterior lumbar decompression and the protective measures for the adjacent ligamentum flavum.

Results: The autopsy results showed that the ligamentum flavum was discontinuous, the ventral surface of the body of the lamina was straight and smooth, and there was no distribution of ligamentum flavum. The medial surface of the wings of the lamina was rough, and the ligamentum flavum was fan-shaped and widely started from the entire lamina. The ventral surface of the wings gradually thins downwards and ends above the lower lamina, with limited distribution of insertion points. The average length of the lamina body, the inner and outer 1/3 of the lamina wings and the body wing angle on the L1-L5 CT sagittal view: L1 lamina body 9.45±2.84 mm, lamina wing 9.92 ±2.65mm, body wing angle 26.2±4.3°; L2 lamina body 9.01±2.45 mm, lamina wing 10.63±2.87 mm, body wing angle 28.3±5.6°; L3 lamina body 8.56±2.62mm, lamina wing 12.32 ±3.25mm, body wing angle 30.4±6.8 °; L4 lamina body 8.02±2.33mm, lamina wing 14.67±3.62mm, body wing angle 33.6±5.2°; L5 lamina body 7.06±2.62 mm, lamina wing 15.32±3.24 mm, body wing angle 32.4±6.9°. Autopsy lamina measurement results (average of inner and outer 1/3): L1 lamina body 13.08±1.58mm, lamina wings 18.86±1.72mm, body wing angle 21.05±2.96°; L2 lamina body 12.84±1.74mm, lamina wing 21.93±2.06mm, body wing angle 19.25±2.86°; L3 lamina body 12.29±1.47mm, lamina wing 20.44±1.6mm, body wing angle 27.25±3.74°; L4 lamina body 11.55±1.47mm, the lamina wing is 23.28±1.7mm, the body wing angle is 29.4±2.11°; the L5 lamina body is 12.75±1.76mm, the lamina wing is 20.91±2.01mm, and the body wing angle is 30±3.03°. The length of the lamina wing is greater than the length of the lamina body, and there is an acute angle between them. Although there are differences in data between the two sets of imaging and autopsy results, the length on imaging is smaller than the measurement results on autopsy, which is considered to be related to the fact that some tissues are not visualized on imaging.

Conclusion: The lamina is divided into a straight lamina body and a posteriorly curved lamina wing; the lumbar ligamentum flavum is intermittent, starting from the ventral side of the lamina wing, starting from a wide, fan-shaped distribution, and ending at the upper part of the lamina body, the insertion point is limited; the integrity of the start and end points of the ligamentum flavum can effectively maintain the tension of the ligamentum flavum. During posterior lumbar laminectomy and decompression, the upper laminectomy range is too large to destroy the insertion point of the upper ligamentum flavum, causing the ligamentum flavum to return upward. Shrinkage, wrinkles, and hypertrophy are hidden on the ventral side of the lamina wing. The rear lamina wing is bonyly restricted, causing the ligamentum flavum to protrude forward into the spinal canal, causing spinal canal stenosis in adjacent segments, which is the main cause of recurrence of spinal canal stenosis after surgery. Standardizing the scope of laminectomy during surgery and retaining the insertion point of the ligamentum flavum in the upper half of the lamina, that is, the body of the lamina, is the main strategy to reduce postoperative secondary spinal stenosis.

Keywords
Lamina body, Lamina wings, Lumbar ligamentum flavum, Spinal stenosis, Coping strategies.

Background
Posterior lumbar total laminectomy and spinal canal decompression is a classic surgical method for the treatment of lumbar spinal stenosis, lumbar spondylolisthesis and other lumbar degenerative diseases. Especially in the elderly, due to severe spinal stenosis, most of them are combined with bony stenosis, etc. Total laminectomy is effective. During the resection of the lamina, in order to completely decompress, the ligamentum flavum is required to be completely removed, so the range of resection of the upper lamina is often too large. Once the upper lamina is completely removed, the stop point of the upper ligamentum flavum is destroyed, causing the ligamentum flavum loses its tension, and secondary retraction, thickening, and wrinkles under the upper lamina form a protruding pressure forward, leading to spinal stenosis at the corresponding segment and causing clinical symptoms of secondary spinal stenosis relapse. This is often due to the fact that doctors are not familiar with the anatomical characteristics such as the origin and endpoint, course, and distribution of the ligamentum flavum. We analyzed a total of 13 patients with postoperative spinal canal stenosis due to the ligamentum flavum factor in the past 5 years, and found that all of them had spinal canal stenosis caused by posterior hypertrophy of the ligamentum flavum in the upper segment of the decompression segment. As soon as we discovered this, we measured and analyzed the anatomical characteristics of the lamina, the origin, end, course, and distribution of the ligamentum flavum through MRI/CT imaging examinations and autopsies to study and analyze the causes, and proposed that the lamina be divided into lamina body, lamina body, and lamina body. The anatomical concept of the two parts of the lamina wings, pay attention to retaining the insertion point of the superior ligamentum flavum during decompression, and clarify the response strategy for the scope of laminectomy, so as to prevent secondary spinal canal disease caused by iatrogenic factors after laminectomy. Stenosis plays a certain guiding role in standardizing intraoperative operations for clinicians.

Materials and methods
General Information on Patients with Secondary Ligamentum Flavum Stenosis
Through the analysis of patients with recurrence of spinal stenosis after posterior total laminectomy and spinal decompression in our hospital from January 2017 to December 2021, 4 patients underwent surgery in our hospital for the first time, and 4 patients underwent surgery in other hospitals. In 9 cases, excluding factors such as in-situ recurrence and adjacent intervertebral disc herniation, it was found that the recurrence of spinal stenosis occurred in the segment above the surgical segment. Among them, the hypertrophy and wrinkles of the posterior ligamentum flavum were the main factors leading to spinal stenosis. A total of 13 patients There were 7 males and 6 females; aged from 53 to 78 years old (67.2±5.5 years old). Seven cases of lumbar spinal stenosis, 3 cases of lumbar spondylolisthesis, and 3 cases of lumbar disc herniation and lumbar instability were diagnosed preoperatively. All underwent posterior lumbar total laminectomy for spinal canal decompression and bone grafting, fusion, and internal fixation. The disease recurred after surgery. Symptoms of lumbar spinal stenosis, mainly intermittent claudication, vary in severity. The recurrence time is 8 to 22 months after surgery (16.4±6.2 months). MRI examinations were performed in all patients. It was confirmed that spinal stenosis is mainly caused by hypertrophy of the posterior ligamentum flavum, Wrinkles (Figures 1 and 2). 10 cases improved after conservative outpatient treatment, and 3 patients had obvious symptoms but refused surgery and continued conservative treatment and achieved a certain degree of relief, but the symptoms recurred.

Figure 1: L3/4 ligamentum flavum retracts and shrinks after L4/5 surgery, causing spinal canal stenosis in the corresponding plane.

Figure 2: After L 2/3/4/5/S1 surgery, L1/2 ligamentum flavum retracts and shrinks, causing spinal canal stenosis in the corresponding plane.

Imaging analysis

We selected 30 elderly patients who underwent lumbar spine MRI and CT examinations in our hospital during the same period from March 2020 to December 2022 to conduct a study on the measurement of the ligamentum flavum and lamina on imaging, including 13 males and 17 females, aged 60 ~ 78 years old (67.2 ± 5.5 years old), height 149 ~ 175 cm (162 ± 6.7 cm), a total of 137 effective vertebral bodies were obtained for measurement. The effective vertebral bodies refer to the ligamentum flavum and lamina on the CT/MRI sagittal image. The vertebral bodies are clearly displayed and can effectively measure the lamina data, including L127 cases, L230 cases, L330 cases, L426 cases, and L424 cases. Because the lamina is displayed more clearly on CT, CT images are used to measure the lamina, the course and distribution of the ligamentum flavum were evaluated using MRI. Divide the lamina into lamina body and lamina wing. Divide one side of the lamina into 3 equal parts. Measure the length of the lamina body and lamina wing at the inner and outer 1/3, and the size of the body wing angle (Figures 3, 4, and 5), take the average of the two (Table 1).

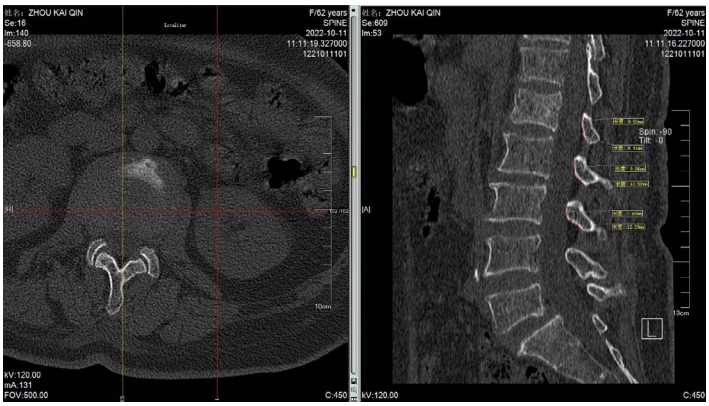

Figure 3: Length of lamina body and lamina wings on CT sagittal view.

Figure 4: CT sagittal upper body wing angle.

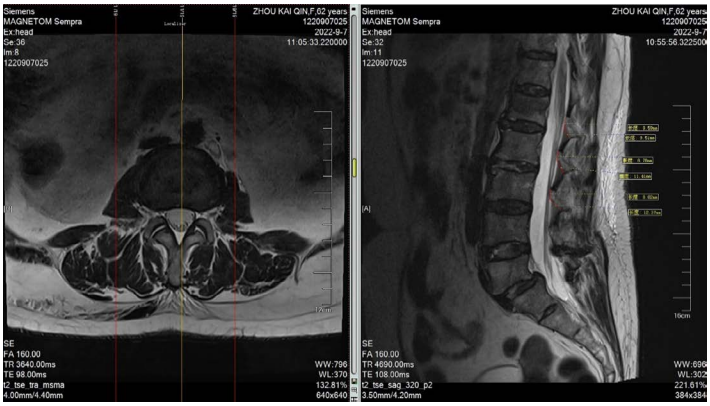

Figure 5: The length of the lamina body and lamina wings and the course and distribution of the ligamentum flavum on the sagittal view of the same site on MRI.

Table 1: Mean values of lamina body, inner and outer 1/3 lengths of lamina wings and body wing angles on lumbar spine CT sagittal view.

Lumbar spine	Lamina body length (mm)	Lamina wing length (mm)	Body wing angle (°)*
L1	9.45±2.84	9.92 ±2.65	26.2±4.3
L2	9.01±2.45	10.63±2.87	28.3±5.6
L3	8.56±2.62	12.32 ±3.25	30.4±6.8
L4	8.02±2.33	14.67±3.62	33.6±5.2
L5	7.06±2.62	15.32 ±3.24	32.4±6.9

*The angle between the lamina body and the lamina wing is an obtuse angle, and the supplementary angle is the angle between the extension line of the lamina body and the lamina wing, which is an acute angle, called the body wing angle.

Autopsy

During the same period, anatomical measurements of the solid ligamentum flavum and lamina were performed on the lumbar vertebrae of 5 elderly cadavers (the specific age and height were unknown), with a total of 25 vertebral bodies. First, remove muscles, fat and other soft tissues, retaining the ligamentum flavum (Figure 6). The electric saw cuts off the two pedicles, retaining the posterior lamina and ligamentum flavum (Figure 7). Divide one side of the lamina into 3 equal parts. Use an electric saw to cut off the inner and outer 1/3 along the sagittal position (Figure 8).

Table 2: The lamina body, lamina wing length and body wing angle in the sagittal view of cadavers.

L1																						
body length	inner	12.7	12.6	12.15	14.15	11.95	12	13.35	14.65	13.15	11.5	11.55	13.25	11.75	13.4	15.25	10.6	12.95	13.6	12.1	11.85	12.725
	outter	12.85	13.45	12.2	14.2	12.5	12.45	13.5	14.85	14.05	11.95	11.65	14.25	12.25	14.45	15.45	11.2	13.45	14.35	12.75	12.85	13.2325
	average value	12.775	13.025	12.175	14.175	12.225	12.225	13.425	14.75	13.6	11.725	11.6	13.75	12	13.925	15.35	10.9	13.2	13.975	12.425	12.35	12.97875
wing length	inner	16.5	16.5	15.6	18.95	15.35	15.85	17.3	19.1	17.75	15.3	15.85	17.55	15.5	18.25	17.85	14.8	17.15	17.7	16.85	15.55	16.7625
	outter	21.15	20.1	20.2	21.4	19.85	18.25	21.45	24.15	21.5	19.85	19.35	20.25	21.05	21.9	23.45	18.1	20.85	21.55	20.35	20.35	20.755
	average value	18.825	18.3	17.9	20.175	17.6	17.05	19.375	21.625	19.625	17.575	17.6	18.9	18.275	20.075	20.65	16.45	19	19.625	18.6	17.95	18.75875
body wing angle		22	19	18	25	25	23	20	24	22	25	18	18	17	24	18	23	17	21	18	24	21.05
L2																						
body length	inner	12.45	11.85	11.85	13.75	11.75	11.35	12.65	14.8	12.75	11.35	11.35	12.55	11.5	13.05	15.45	10.45	12.5	14.2	12.45	11.75	12.49
	outter	12.65	12.6	12.1	14.05	11.95	12.25	13.1	15.35	14.25	11.55	11.5	12.7	12.5	13.35	16.65	10.65	12.45	15.25	12.8	12.1	12.99
	average value	12.55	12.225	11.975	13.9	11.85	11.8	12.875	15.075	13.5	11.45	11.425	12.625	12	13.2	16.05	10.55	12.475	14.725	12.625	11.925	12.74
wing length	inner	19.9	20.1	18.95	22	19.15	17.2	20.1	23.15	20.8	15.15	18.2	21.15	19.65	20.65	23.95	17.45	20.25	21.1	19.25	18.95	19.855
	outter	23.9	24.35	22.4	25.25	22.05	23.3	22.95	26.05	24.7	22.5	21.95	25.65	22.75	25.65	26.85	20.85	25.1	24.45	22.95	22.35	23.8
	average value	21.9	22.225	20.675	23.625	20.6	20.25	21.525	24.6	22.75	18.825	20.075	23.4	21.2	23.15	25.4	19.15	22.675	22.775	21.1	20.65	21.8275
body wing angle		20	16	18	22	23	20	18	23	18	16	18	14	21	23	18	22	15	17	20	23	19.25
L3																						
body length	inner	11.95	11.2	11.45	13.25	11.25	10.75	12.1	13.25	13.2	11.8	10.85	11.8	12.05	12.5	13.85	9.95	11.5	12.25	11.9	12.15	11.95
	outter	12.1	12.1	11.5	14.55	11.3	11.65	12.65	14.5	13.75	11.35	11.8	12.05	12.2	13.05	14.4	10.75	11.55	13.5	12.15	11.55	12.4225
	average value	12.025	11.65	11.475	13.9	11.275	11.2	12.375	13.875	13.475	11.575	11.325	11.925	12.125	12.775	14.125	10.35	11.525	12.875	12.025	11.85	12.18625
wing length	inner	18.75	17.35	17.7	20.3	17.45	16.75	19.15	21.05	18.95	16.9	17	18.55	17.75	19.05	21.85	15.85	18.15	19.65	18	17.7	18.395
	outter	23.3	21.55	22.15	25.35	21.75	20.65	20.55	22.65	23.7	22.25	21.25	22.75	23.65	21.75	23.4	20.65	22.25	21.15	22.25	22.55	22.2775
	average value	21.025	19.45	19.925	22.825	19.6	18.7	19.85	21.85	21.325	19.575	19.125	20.65	20.7	20.4	22.625	18.25	20.2	20.4	20.125	20.125	20.33625
body wing angle		28	28	26	26	27	22	22	26	25	23	24	25	32	25	34	30	25	31	33	33	27.25
L4																						
body length	inner	11.4	10.95	10.75	12.6	10.6	10.55	11.5	12.55	11.5	10.1	10.2	11.6	10.2	11.9	13.15	9.35	11.3	11.65	11.2	10.4	11.1725
	outter	11.55	11.9	10.85	12.45	11.45	11.45	11.45	12.9	12.65	11.05	10.35	12.35	10.95	12.5	13.55	10.25	12.15	11.95	12.15	10.75	11.7325
	average value	11.475	11.425	10.8	12.525	11.025	11	11.475	12.725	12.075	10.575	10.275	11.975	10.575	12.2	13.35	9.8	11.725	11.8	11.675	10.575	11.4525
wing length	inner	20.6	20.55	20.15	24.4	20.35	20.85	20.6	21.3	20.75	20.5	19.55	20.65	20.75	20.1	25.1	18.7	20.55	20.55	20.5	20.15	20.8325
	outter	24.75	25.15	23.65	27.75	25.3	27.45	25.15	27.55	26.15	24.75	25.8	24.45	25	26.15	28.35	24.45	23.95	25.95	23.75	25	25.525
	average value	22.675	22.85	21.9	26.075	22.825	24.15	22.875	24.425	23.45	22.625	22.675	22.55	22.875	23.125	26.725	21.575	22.25	23.25	22.125	22.575	23.17875
body wing angle		30	28	31	28	26	26	31	27	33	30	33	31	28	31	32	30	27	27	30	32	29.55
L5																						
body length	inner	12.15	11.2	11.5	14.35	11.35	10.55	13.15	14.4	13.35	11.5	10.95	11.65	11.75	13.55	15.05	10.05	11.4	13.35	13.05	11.85	12.3075
	outter	13.2	11.55	12.5	14.6	12.35	11.95	13.4	15.55	13.5	11.95	11.05	12.95	11.25	14.75	15.3	11.25	11.85	14.5	14	12.35	12.99
	average value	12.675	11.375	12	14.475	11.85	11.25	13.275	14.975	13.425	11.725	11	12.3	11.5	14.15	15.175	10.65	11.625	13.925	13.525	12.1	12.64875
wing length	inner	18.95	18.5	18	20.55	17.75	17.75	19.45	21.15	20.45	17.25	17.55	19.5	18.05	19.9	22.55	16.55	19.15	19.75	18.5	17.55	18.9425
	outter	22.65	22.05	21.55	25.05	21.2	21.25	23.05	25.55	23.4	20.95	20.95	23.3	22.15	23.5	26.95	19.4	22.55	24.85	21.9	21.2	22.6725
	average value	20.8	20.275	19.775	22.8	19.475	19.5	21.25	23.35	21.925	19.1	19.25	21.4	20.1	21.7	24.75	17.975	20.85	22.3	20.2	19.375	20.8075
body wing angle		31	29	28	27	29	31	27	31	28	27	30	30	30	27	34	33	35	35	35	26	30.15

Figure 6: General image of the lumbar spine; **Figure 7:** Posterior wall of the spinal canal cut off from the pedicles on both sides; **Figure 8:** Cut off from the inner 1/3 of the lamina.

Use a vernier caliper to measure the length of the lamina body and lamina wings at the inner and outer 1/3, as well as the size of the body wing angle. Its average value; the origin, end, and course of the lumbar ligamentum flavum were dissected to clarify its distribution characteristics. The results are as follows.

Results

All 13 patients underwent posterior total laminectomy for spinal canal decompression during the first surgery. Through CT and MRI examination, it was found that the upper laminectomy was a total laminectomy, which destroyed the insertion point of the superior ligamentum flavum, resulting in the formation of superior ligamentum flavum. Retraction, wrinkles, and hypertrophy caused spinal stenosis in the upper space. Among them, 3 patients had no obvious symptoms, 7 patients had mild symptoms, and improved after treatment and received conservative treatment. 3 patients had obvious symptoms and refused surgery or had no conditions for surgery, continued conservative treatment, and all achieved a certain degree of relief. All patients were followed up for 10-36 months (22.4±7.6 months). The symptoms of 10 patients were relieved without obvious waist and leg pain. The symptoms of intermittent claudication were also improved, and the symptoms of 3 patients were recurrent.

It was found on CT/MRI and autopsy that the lumbar lamina in the sagittal position is not a flat plate, but consists of a straight upper

part and a backward-warped lower part. Therefore, we proposed to divide the lamina into The straight "lamina body" at the top and the "lamina wing" at the bottom (Figure 9), their respective lengths and angles were measured through MRI/CT and cadavers, L1-L5 CT sagittal view the average length of the inner and outer thirds of the lamina body, lamina wing, and body wing angle: L1 lamina body 9.45±2.84mm, lamina wing 9.92 ±2.65mm, body wing angle 26.2±4.3°; L2 lamina body 9.01 ±2.45mm, lamina wing 10.63±2.87 mm, body wing angle 28.3±5.6°; L3 lamina body 8.56±2.62mm, lamina wing 12.32 ±3.25mm, body wing angle 30.4±6.8°; L4 lamina body 8.02 ±2.33mm, lamina wing 14.67±3.62mm, body wing angle 33.6±5.2°; L5 lamina body 7.06±2.62mm, lamina wing 15.32±3.24mm, body wing angle 32.4±6.9°.

Autopsy lamina (Figure 10) measurement results (average of inner and outer 1/3): L1 lamina body 13.08±1.58mm, lamina wing 18.86±1.72mm, body wing angle 21.05±2.96°; L2 lamina body 12.84±1.74mm, lamina wing 21.93±2.06mm, body wing angle 19.25±2.86°; L3 lamina body 12.29±1.47mm, lamina wing 20.44±1.6mm, body wing angle 27.25±3.74°; L4 lamina body 11.55±1.47mm, lamina wing 23.28±1.7mm, body wing angle 29.4±2.11°; L5 lamina body 12.75±1.76mm, lamina wing 20.91±2.01mm, body wing angle 30±3.03°. The length of the lamina wings is greater than the length of the lamina body, and there is an acute angle between them, gradually increasing from L1 to L5.

There are differences between the two sets of imaging and autopsy results. Considering that soft tissue and cartilage are removed on CT/MRI, the measurement data are smaller, while the autopsy data are relatively larger, but the trends of the two are consistent. Comprehensive CT/MRI and autopsy, the course and distribution of the ligamentum flavum were analyzed. The ligamentum flavum is intermittent, and there is no ligamentum flavum distribution in the body of the lamina. The starting point is the ventral side of the lamina wing, the starting point is broad, fan-shaped distribution, and the ending point is the upper part of the lamina body has limited insertion points. Therefore, the ventral side of the lamina body and the ventral side of the ligamentum flavum together form a flat posterior wall of the spinal canal; the integrity of the starting and ending points of the ligamentum flavum can effectively maintain the tension of the ligamentum flavum. The destruction of the lamina wing will not affect the overall tension of the ligamentum flavum. Even if the lamina wing is destroyed, due to the loss of the posterior bony barrier and the destruction of the starting point of the ligamentum flavum, it will not protrude forward to form spinal canal stenosis. However, if the upper vertebrae are affected, Excessive laminectomy destroys the insertion point of the upper ligamentum flavum, causing the ligamentum flavum to retract upward, wrinkle, and become thickened, hiding on the ventral side of the lamina wing. The rear lamina wing is bonyly restricted, causing the ligamentum flavum to protrude forward into the spinal canal. Spinal canal stenosis in adjacent segments is the main cause of postoperative recurrence of spinal canal stenosis. Therefore, standardizing the scope of laminectomy during surgery and retaining the insertion point of the ligamentum flavum in the upper half of the lamina, that is, the body of the lamina, is the main strategy to reduce postoperative secondary spinal stenosis.

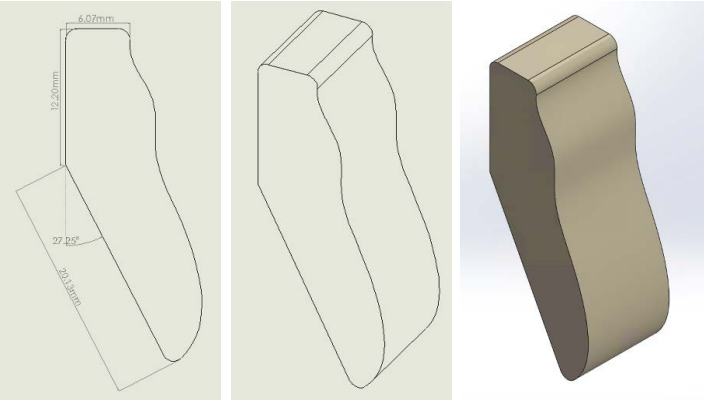

Figure 9: Schematic diagram of the lamina (sagittal, oblique, gross image).

Figure 10: Autopsy showing the course and distribution of the lamina body, wings, body wing angle and ligamentum flavum.

Discussion

Anatomy and Composition of Ligamentum Flavum:

The ligamentum flavum has a yellow appearance and is mainly composed of yellow elastic fibers. It is discontinuous. It connects adjacent laminae and together with the laminae forms the posterior wall of the spinal canal. The ligamentum flavum is the thickest in the lumbar spine [1]. Anatomical studies have found that the lumbar ligamentum flavum is divided into two layers, shallow and deep [2,3]. Olszewski et al. [2] described the layering of the ligamentum flavum. The dorsal side of the ligamentum flavum is a layer of light yellow tissue with more fibrous tissue, and the deep layer is dark yellow, more elastic fibers. Iwanaga et al. [4] found through anatomical and histological studies that the superficial layer of the ligamentum flavum is actually the continuation of the interspinous ligament, while the deep layer is the real ligamentum flavum. Studies have found that the ligamentum flavum is attached from the lower edge of the lamina on the cranial side to the middle of the lamina, and the ligamentum flavum is attached on the upper

edge and anterosuperior surface of the lamina on the caudal side [2,3]. However, the shape of the lamina was not mentioned in previous descriptions, and the specific attachment site and shape of the ligamentum flavum were not specified.

Normal ligamentum flavum is mainly composed of elastic fibers, accounting for about 60% to 80% [5,6]. Kosaka et al. [7] reported that elastic fibers account for about 75% in the ventral part of the ligamentum flavum in fetuses and adults. The elastic fibers are parallel to the long axis of the ligamentum flavum and have approximately the same diameter, and a small amount of collagen fibers can be seen between the elastic fibers [8]. There are a large number of nerve fibers in the ligamentum flavum, which are arranged parallel to elastic fibers and collagen fibers. Vascular structures can also be seen in the ligamentum flavum [9]. The ligamentum flavum on both sides fuses at the midline, and there is a gap in the middle without fusion. Lirk et al. [10] measured the incidence of gaps in the middle of L1/2 in 45 lumbar vertebra specimens to be 22.2%, and the incidence of gaps in L2 to L5. Is about 10%. The ligamentum flavum on both sides forms a triangular space opening forward on the posterior wall of the spinal canal, with an epidural fat pad underneath [11].

Anatomy of Lumbar Lamina and Distribution of Ligamentum Flavum:

The lamina refers to the bony plate on the vertebral body that connects the vertebral arch, vertebral body, anterior and posterior articular processes, transverse processes and spinous processes. The ligamentum flavum is located between two adjacent laminae, and together they form the posterior part of the spinal canal. On the lateral wall, the description of the lamina in anatomy books is limited to this, and there is no further description of the shape of the lamina. However, according to our measurement studies on MRI/CT and cadavers, we found that the vertebral lamina is not a straight plate in the sagittal plane, but consists of a straight upper part and a backward curved lower part. An anatomical feature is of great significance in studying the distribution of ligamentum flavum. Therefore, we proposed to divide the lamina into two parts: the "lamina body" which is straight above and the "lamina wing" which is curved below. The lower edge of the lamina body is "lamina body". V" shape, the body of the lamina is the smooth part that forms the posterior wall of the spinal canal, and the wings of the lamina are the starting point of the ligamentum flavum. That is, above the starting point of the ligamentum flavum is the lower edge of the lamina body, completely covering it backward and downward. The wings of the lamina are distributed in a fan shape with a length of about 10-20mm. Such attachment characteristics form a smooth surface behind the spinal canal, which gradually thins downward and stops above the lower lamina body, with a relatively limited stop.

The Mechanism of Spinal Stenosis Caused By Retraction of Ligamentum Flavum

The ligamentum flavum is mainly composed of elastic fibers, so it is very elastic and can return to its original shape after being stretched. The ligamentum flavum maintains a certain tension under normal body loads. When degeneration occurs, the biomechanical performance of the ligamentum flavum is an increase in stress, a decrease in strain, an increase in elastic modulus [12], an increase in stress relaxation, and a decrease in creep [13]. Studies have found that after degenerative changes occur in the ligamentum flavum, the ligamentum flavum cannot completely restore its original length after the load is unloaded, and can fold inward, bulge, and become hypertrophic, causing compression. Therefore, maintaining moderate tension of the ligamentum flavum can maintain the normal thickness and shape of the ligamentum flavum, thereby maintaining the normal spinal canal area and avoiding the occurrence of spinal canal stenosis [14-16]. After lumbar fusion, stress concentration in adjacent unfused segments will lead to aggravation of adjacent segment degeneration. If it only shows degeneration on imaging but has no corresponding clinical symptoms, it is called adjacent segment degeneration. If it merges with imaging, it is called adjacent segment degeneration. The corresponding clinical symptoms are called adjacent segment lesions, and their incidence rates are approximately 26.6% and 8.5% respectively [17,18]. Kazunori et al. used New Zealand rabbits as experimental animals. Fusion of L2/3 and L4/5 increased the mobility and stress of the L3/4 segment. They observed an increase in the thickness of the unfused segment, namely the L3/4 ligamentum flavum, and an increase in collagen fibers. Changes such as decreased elastic fibers and increased expression of fibroblast growth factor 9 (FGF9) [19,20]. This is a cause of hypertrophy of the ligamentum flavum at adjacent segments. Although various studies have shown that hypertrophy of the ligamentum flavum of adjacent segments will occur after lumbar fusion, our observation found that there is no obvious hypertrophy of the ligamentum flavum below the surgical segment, nor does it cause spinal canal stenosis. It is the hypertrophy of the ligamentum flavum that occurs in the upper segment of the decompression segment, especially the obvious hypertrophy of the ligamentum flavum that can lead to spinal stenosis. This requires us to further analyze the main reasons for its occurrence.

The ligamentum flavum is mainly composed of elastic fibers. The elastic fibers are parallel to the long axis of the ligamentum flavum and have a certain stretch and retraction force. The maintenance of the tension and length of the ligamentum flavum relies on the existence of complete starting and ending points. Once the fixation of the ending points is lost, the ligamentum flavum will naturally gradually retract, forming wrinkles and hypertrophy. If the ligamentum flavum starts from the lower edge of the upper lamina and ends at the upper edge of the lower lamina as described in the previous anatomy, then there should be a soft tissue structure behind it. Even if the ligamentum flavum is hypertrophic, it can be displaced posteriorly to alleviate its impact. The compression of the dural sac, and imaging shows that the upper intervertebral disc plane generally passes through the middle of the lamina wing, that is, the retracted hypertrophic ligamentum flavum is just in front and below the lamina wing. It is precisely because of the bony structure of the lamina wing behind it. Blockage causes the shriveled and hypertrophic ligamentum flavum to protrude into the spinal canal, causing spinal canal stenosis and corresponding clinical symptoms.

Coping Strategies

Lumbar decompression and fusion is a classic surgical procedure for the treatment of lumbar degenerative diseases and has certain efficacy [21]. In order to achieve complete decompression during spinal canal decompression, complete resection of the ligamentum flavum is the key. The resection of the ligamentum flavum is generally performed from the upper part to its starting point, and the lower part is resected from its stopping point. The upper part of the ligamentum flavum is resected through laminectomy. Expose and complete, because the lower edge of the lamina body and the starting point of the ligamentum flavum are distributed in a "V" shape. When resecting the "V" shaped starting point of the ligamentum flavum, the lamina body will be completely removed first on the midline, and then the lamina body will be completely removed on the midline. When resecting the ligamentum flavum on both sides without realizing it, the laminae on both sides are often completely removed and destroyed, thereby destroying the insertion point of the superior ligamentum flavum, causing the superior ligamentum flavum to retract, become thickened, and shrink, leading to spinal stenosis at the upper intervertebral space level.

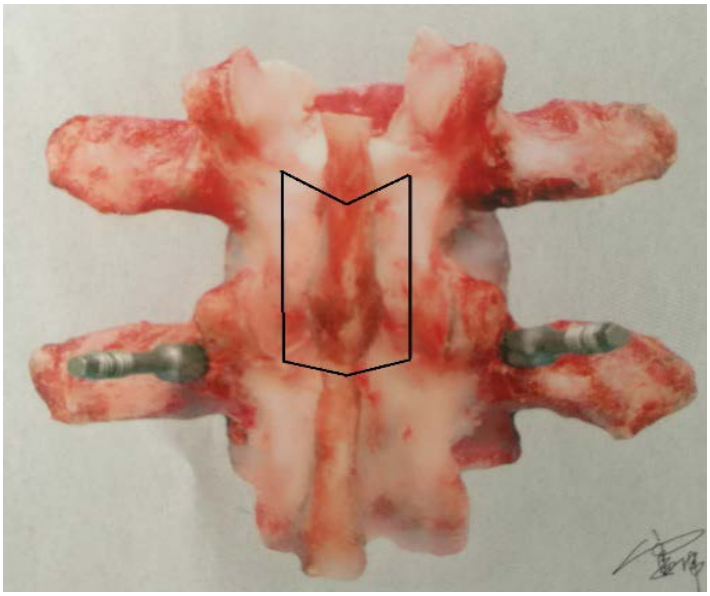

Figure 11: The scope of laminectomy, just remove the wing of the laminar plate, which is the attachment point of the ligamentum flavum, in a "V" shape.

In order to achieve effective spinal canal decompression and avoid secondary hypertrophy of the ligamentum flavum caused by human factors, the lamina wing should be the main focus when exposing and resecting the starting point. Once the insertion point of the ligamentum flavum is determined on the midline, do not bite off the lamina from the middle upward, but bite off the lamina obliquely to both sides and gradually upward, the range is bounded by the top end of the ligamentum flavum (Figure 11), that is bite off the lamina wings, including at most the lower edge of the lamina body is preserved, and the upper half of the lamina body is preserved, that is, the insertion point of the superior ligamentum flavum is preserved. This clarifies the scope of laminectomy, thereby effectively avoiding the occurrence of secondary spinal stenosis caused by shrinkage and hypertrophy of the ligamentum flavum.

The shortcomings of this study are:

(1) The sample size in this article's measurement of the ligamentum flavum on MRI and CT is small, and there are many interference factors in the measurement, including the patient's position, degree of degeneration, visualization, etc.;

(2) There are subjective factors of the measurer, which have a certain impact on the accuracy of the results.

References

1. Standring S. Gray's Anatomy. The Anatomical Basis of Clinical Practice. London UK. Elsevier. 2016; 731-733.
2. Olszewski AD, Yaszemski MJ, White AA. The anatomy of the human lumbar ligamentum flavum new observations and their surgical importance. J Spine. 1996; 21: 2307-2312.
3. Chau AM, Pelzer NR, Hampton J, et al. Lateral extent and ventral laminar attachments of the lumbar ligamentum flavum cadaveric study. J Spine. 2014; 14: 2467-2471.
4. Iwanaga J, Ishak B, Saga T, et al. The lumbar ligamentum flavum does not have two layers and is confluent with the interspinous ligament anatomical study with application to surgical and interventional pain procedures. J Clin Anat. 2020; 33: 34-40.
5. Nachemson AL, Evans JH. Some mechanical properties of the third human lumbar interlaminar ligament ligamentum flavum. J Biomechanics. 1968; 1: 211-220.
6. Troyer KL, Puttlitz CM. Nonlinear viscoelasticity plays an essential role in the functional behavior of spinal ligaments. J Biomech. 2012; 45: 684-691.
7. Kosaka H, Sairyo K, Biyani A, et al. Pathomechanism of loss of elasticity and hypertrophy of lumbar ligamentum flavum in elderly patients with lumbar spinal canal stenosis. J Spine. 2007; 32: 2805-2811.
8. Boezaart AP, Prats-Galino A, Nin OC, et al. The posterior lumbar epidural space three dimensional reconstruction of high-resolution mri real and potential epidural spaces and their content in vivo. J Pain Med. 2019; 20: 1687-1696.
9. Viejo-Fuertes D, Liguoro D, Vital JM, et al. Morphogenesis anatomy and histology of the ligamentum flavum. J Eur J Orthop Surg Traumatol. 2000; 10: 77-83.
10. Lirk P, Moriggl B, Colvin J, et al. The incidence of lumbar ligamentum flavum midline gaps. J Anesth Analg. 2004; 98: 1178-1180.
11. Yong-hing K, Reilly J, Kirkaldy-Willis WH. The Ligamentum flavum. J Spine. 1976; 1: 226-234.
12. Shang Guanlei, Fan Xing, Zhong Xiaopeng, et al. Biomechanical determination of lumbar degeneration of ligamentum flavum. J Chinese Journal of Spine and Spinal Cord. 2009; 19: 749-752.

13. Wang Xiyuan, Yuan Fusheng, Zhang Yuanshi, et al. Experimental study on the viscoelasticity of the spinal ligamentum flavum in young and elderly people. J Medical Biomechanics. 2011; 26: 75-80.
14. Ohtori S, Orita S, Yamauchi K, et al. Change of lumbar ligamentum flavum after indirect decompression using anterior lumbar interbody fusion. J Asian Spine. 2017; 11: 105-112.
15. Nakashima H, Kanemura T, Satake K, et al. Indirect decompression on MRI chronologically progresses after immediate post lateral lumbar interbody fusion the results from a minimum of 2 years follow-up. J Spine. 2019; 44: E1411-E1418.
16. Mahatthanatrakul A, Kim HS, Lin GX, et al. Decreasing thickness and remodeling of ligamentum flavum after oblique lumbar interbody fusion. J Neuroradiology. 2020; 62: 971-978.
17. Hashimoto K, Aizawa T, Kanno H, et al. Adjacent segment degeneration after fusion spinal surgery-a systematic review. J Int Orthop. 2019; 43: 987-993.
18. Jichao Ye, Shen Huiyong. Adjacent segment disease after lumbar fusion. J Chinese Journal of Orthopedics. 2017; 37: 1294-1299.
19. Hayashi K, Suzuki A, Abdullah Ahmadi S, et al. Mechanical stress induces elastic fibre disruption and cartilage matrix increase in ligamentum flavum. J Sci Rep. 2017; 7: 13092.
20. Hayashi K, Suzuki A, Terai H, et al. Fibroblast growth factor 9 is upregulated upon intervertebral mechanical stress-induced ligamentum flavum hypertrophy in a rabbit model. J Spine. 2019; 44: E1172-E1180.
21. Mobbs RJ, Phan K, Malham G, et al. Lumbar interbody fusion techniques indications and comparison of interbody fusion options including PLIF TLIF MI-TLIF OLIF/ATP LLIF and ALIF. J Spine Surg. 2015; 1: 2-18.

© 2023 Ming D, et al. This article is distributed under the terms of the Creative Commons Attribution 4.0 International License