Case Report

International Journal of Orthopedic Surgery & Research

Mixed Gangrene of the Pelvic Limb Secondary to a Tibial Osteochondroma

ABDOUL WAHAB Allassane Mohamed[1,2*], Garba IDE, Alzouma Atinine Moutalibi, Ismael Manou, Cheffou M Soumaila, and Souna Badio Seyni

[1]*Department of Orthopaedic Surgery and Traumatology, General Hospital of Reference, Niamey, Niger.*

[2]*Department of Surgery and Surgical Specialties, Faculty of Health Sciences, Abdou Moumouni University, Niamey, Niger.*

[*]Correspondence:

ABDOUL WAHAB ALLASSANE Mohamed, Department of Surgery and Surgical Specialties, Faculty of Health Sciences, Abdou Moumouni University, Department of Orthopaedic Surgery and Traumatology, General Hospital of Reference, Niamey, Niger.

Received: 07 May 2025; **Accepted:** 21 Jun 2025; **Published:** 29 Jun 2025

Citation: ABDOUL WAHAB Allassane Mohamed, Garba IDE, Alzouma Atinine Moutalibi, et al. Mixed Gangrene of the Pelvic Limb Secondary to a Tibial Osteochondroma. Int J Orthop Surg Res. 2025; 1(1): 1-3.

ABSTRACT

Osteochondroma, also known as exostosis, is a common benign tumor that develops during growth, and is usually asymptomatic. It occurs preferentially on the distal femur (30%) and proximal tibia (20%). Its radiographic appearance, when solitary, is frequently pathognomonic, enabling a diagnosis of certainty even in the absence of anatomopathological confirmation. Its discovery is most often fortuitous, but can exceptionally be revealed during a vascular-nervous complication. We report the case of a 38-year-old patient with a history of traumatic left tibio-talar disarticulation, admitted to the surgical emergency department with mixed gangrene of the left pelvic limb, revealing an exostosis at the level of the tibial disarticulation stump. Standard radiographs of the left knee showed a solitary pedunculated osteochondroma of the posterior aspect of the upper end of the tibia. A long posterior valve disarticulation of the left knee was indicated, and the post-operative course was straight forward.

Keywords

Mixed gangrene, Pelvic limb, Limb ischemia, Bone tumor.

Introduction

Osteochondroma, commonly known as exostosis, is the most common benign bone tumour, accounting for 35% of all benign bone tumours. However, it accounts for 8% of all bone tumors, and predominates in males (75%). It is a bony outgrowth of a cartilage island, growing ectopically and maturing according to a normal enchondral ossification process [1]. The most frequent location is the metaphysis of long bones (90%), with a predilection for the distal femur (30%), proximal tibia (20%) and proximal humerus (17%) [1].

The radiographic appearance of solitary exostosis, particularly in long bones, is frequently pathognomonic. In the majority of cases, it provides a definitive diagnosis, even in the absence of anatomopathological confirmation [2].

It develops during growth and can be multiple or localized [1,3]. Its discovery is often fortuitous and can occur at any age, due to its generally asymptomatic nature [4,5]. Exceptionally, it may be revealed by a vascular-nervous compression complication [4]. We describe the case of a patient admitted to emergency surgery with mixed gangrene of the left lower limb, revealing an exostosis of the tibia.

Case Presentation

A 38-year-old male patient with a history of traumatic left tibiotalar disarticulation was admitted to the surgical emergency department with necrosis of the disarticulation stump.

The history of the left tibio-talar disarticulation dates back 3 months to the onset of acute ischemia of the left foot. He had initially opted for traditional treatment, but the worsening of his clinical picture led him to consult the Niamey General Reference Hospital for medical treatment. Given the evolution of the foot

ischemia into gangrene that extended up the leg, with mortification of the tissues, all in a febrile context, a tibio-talar disarticulation was performed.

The late evolution of the tibio-talar disarticulation was marked by necrosis of the disarticulation stump, which led to an emergency return visit.

Clinical examination on admission revealed a febrile patient with a core temperature of 38°C, pulse 102 beats per min, blood pressure 108/64 mm Hg, oxygen saturation (SaO2) at 97% at room air. Physical examination revealed a tibio- talar disarticulation stump, covered with patches of necrosis extending to the middle 1/3 of the leg, leaking pus on pressure (Figure 1).

A mass located in the popliteal fossa, retro tibial, compressive, firm consistency, painless, with regular contours, fixed to the deep plane. The popliteal pulse was absent. The lymph nodes were free.

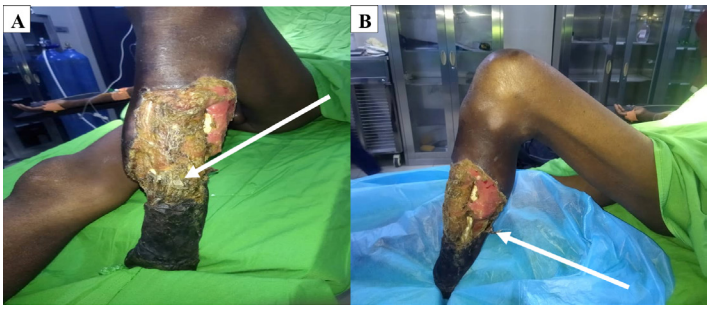

Figure 1: Preoperative photograph of the patient's left leg, showing the necrosis of the stump in front (A) and in profile (B) (white arrow).

Biological workup revealed hyperleukocytosis at 14,400/µL with granulocytic predominance at 11,500/µL, anemia at 7.4g /dL, thrombocytosis at 565,000/µL, normal capillary blood glucose at 3.86 mmol/L, uremia at 2.64 mmol/L, creatinine at 53 mmol/L, and C-Reactive Protein (CRP) at 12mg/L. Standard radiographs of the left knee showed a solitary pedunculated osteochondroma of the posterior aspect of the upper end of the tibia (Figure 2).

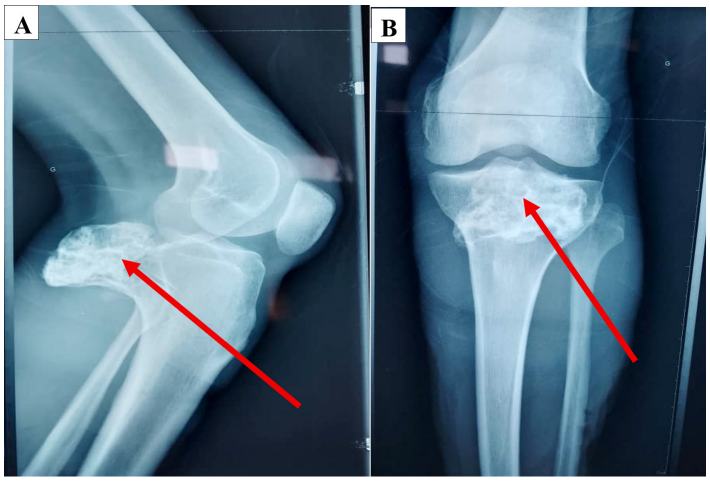

Figure 2: Standard preoperative X-ray image of the patient's left knee, showing a solitary pedunculated osteochondroma of the posterior aspect of the upper end of the tibia (red arrow) in front view (A) and profile view (B).

The indication for surgical treatment was long posterior valve disarticulation of the left knee (Figure 3), and the post-opérative course was straightforward.

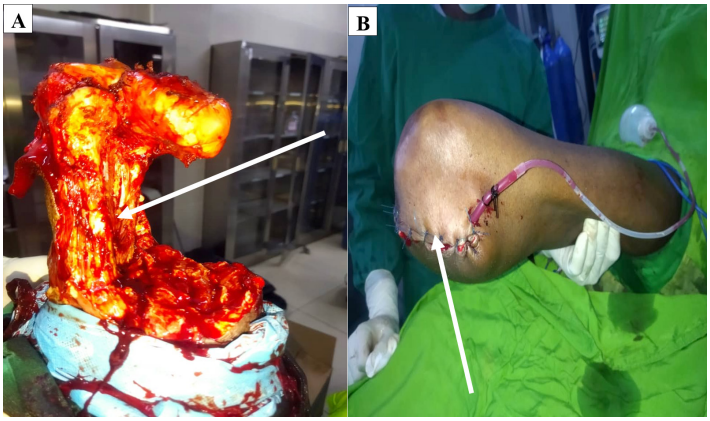

Figure 3: Intraoperative (A) and postoperative (B) photographs of long-valve posterior knee disarticulation surgery (white arrow).

Discussion

Vascular complications of bone exostosis are rare and include perforation, pseudoaneurysm and thrombosis, all resulting from compression, repeated injury or direct perforation by the exostosis [5,6]. As exostoses are often discovered incidentally, vascular complications often have an acute onset and are managed urgently [6].

The clinic most commonly reported in the literature concerns signs of acute or progressive ischemia of the limbs, with intermittent claudication resulting in the classic trapped popliteal artery syndrome. This was not the case in our patient, who presented with gangrene of the limb, explained by the delay in diagnosis [4,7]. Numerous case reports of exostoses causing vascular complications suggest that the optimal approach to the management of these pathologies involves a combination of vascular and orthopaedic surgeons, i.e. excision of the exostosis and vascular reconstruction by direct repair, end-to-end anastomosis or surgical bypass. Thromboembolectomy or thrombolysis, if necessary, has also been used [6,8-10]. Few cases report limb disarticulation or amputation, as patients are usually seen and managed early before irreversible ischemia sets in.

Conclusion

Bone exostoses are fairly frequent benign tumors, often asymptomatic, but which can be revealed by complications, particularly vascular ones. The diagnosis should be made in any young patient, without cardiovascular factors, presenting with acute ischemia or gangrene of a lower limb.

References

1. Stolz H, Rod Fleury T, Boudabbous S, et al. Tumeurs cartilagineuses. Rev Med Suisse. 2018; 14: 2259-2263.
2. Moatassim Billah N, Idrissi MM, Idrissi Kaitouni R, et al. Imaging of solitary exostoses. Service de radiologie des urgences, CHU Ibn Sina, Rabat, Maroc. 2013; 53: 11-20.
3. Almaghraoui O, Ezzahraoui R, Abdou A, et al. Acute lower limb ischemia secondary to femoral osteochondroma. Service de chirurgie vasculaire, Hôpital Militaire Avicenne, Marrakech, Maroc. J Med Vasc. 2019; 44: 213-215.
4. Alami M, Mekkaoui J, Ismael F, et al. Complication rare d'exostose: rupture de faux anévrisme de l'artère poplitée (à propos d'un cas). Service de Traumato-Orthopédie, Hôpital Ibn Sina, Rabat-Salé, Maroc. 2011; 36: 50-55.
5. AlHamzah M, Alshaygy I, Alanezi T, et al. Popliteal artery occlusion due to femur exostosis in a patient with rheumatoid arthritis: A rare cause of chronic limb-threatening ischemia. Cureus. 2024; 16: e69926.
6. Chaouch N, Alimi F, Kortas C, et al. Complications vasculaires poplitées bilatérales d'une exostose héréditaire multiple. Ann Cardiol Angeiol. 2011; 60: 109-112.
7. Vasseur MA, Fabre O. Vascular complications of osteochondromas. J Vasc Surg. 2000; 31: 532-538.
8. Angelini A, Cerchiaro M, Maturi C, et al. Vascular complications caused by tibial osteochondroma: Focus on the literature and presentation of a popliteal artery thrombosis with acute lower limb ischemia. Diagnostics (Basel). 2022; 12: 1191.
9. Pellenc Q, Capdevila C, Julia P, et al. Ruptured popliteal artery pseudoaneurysm complicating a femoral osteochondroma in a young patient. J Vasc Surg. 2012; 55: 1164-1165.
10. Douis H, Saifuddin A. The imaging of cartilaginous bone tumours. I. Benign lesions. Skeletal Radiol. 2012; 41: 1195-2212.

© 2025 Allassane Mohamed AW. This article is distributed under the terms of the Creative Commons Attribution 4.0 International License