Case Report ISSN 2639-944X

Journal of Medical - Clinical Research & Reviews

Rectal Malakoplakia Presenting as Multiple Rectal Polyps -A Case Report

Kankanamge A[1,2]*, Elham A[1], Haddad A[1,3] and Soni P[1]

[1]Anatpath services, Australia.

[2]Ministry of health Sri Lanka, Colombo, Sri Lanka.

[3]University of Notre dame, Australia.

*Correspondence:

Ayomi Kankanamge, Anatpath Services, 120 Gardenvale Rd, Gardenvale, 3185, Victoria, Australia, Fax: 0395967766; Tel: 0395960777.

Received: 20 Dec 2023; **Accepted:** 27 Jan 2024; **Published:** 05 Feb 2024

Citation: Kankanamge A, Elham A, Haddad A, et al. Rectal Malakoplakia Presenting as Multiple Rectal Polyps -A Case Report. J Med - Clin Res & Rev. 2024; 8(2): 1-4.

ABSTRACT

Malakoplakia is a rare chronic granulomatous disease that may affect many organs, the genitourinary tact being the most common site. The second most common site is gastrointestinal tract. Here, we present a case of a 72year old immunocompetent female with a past history of Barrett's oesophagus who underwent upper and lower GI endoscopy. Apart from three rectal polyps, the endoscopic examination was normal. Histological examination confirmed polypoid mucosa with malakoplakia manifested by the presence of characteristic Michaelis-Gutmann bodies. This is a rare case of isolated rectal polyposis with malakoplakia diagnosed on endoscopic specimens. Most of the reported cases of rectal malakoplakia have shown an association with systemic disease and/or colorectal carcinoma. Furthermore, there has been strong association with immunodeficiency or infective aetiologies.

Keywords

Malakoplakia, Rectal, Michaelis-Gutmann, Polyps, Genitourinary.

Introduction

Malakoplakia, also known as von Hansemann's disease, is an exceedingly rare chronic granulomatous inflammatory condition characterized by dense histiocytic infiltration. It was initially reported by Michaelis and Gutmann in 1902 [1,2]. Malakoplakia can affect various organs and tissues throughout the body, with the urogenital tract being the most common site. The bladder is the most frequently affected organ, followed by the prostate, kidney, ureter, testes, and epididymis. The gastrointestinal tract ranks second in frequency, with the colon and rectum being the most commonly involved sites. Moreover, other organs, such as the skin, central nervous system, lung, bone, female genital tract, and thyroid gland, may rarely be affected [3,4]. Malakoplakia tends to develop more frequently in immunocompromised patients, with a higher prevalence in females [3]. Malakoplakia of the rectum is an exceptionally rare entity, with only a few cases reported in the literature [5]. We present a case of incidental rectal polyposis diagnosed as isolated rectal malakoplakia in an immunocompetent elderly female patient.

Case Report

A 73-year-old female with a history of hypercholesterolemia was diagnosed with Barrett's esophagus. On follow-up GI endoscopies, she was found to have four rectal polyps (Figure1). Apart from this, the lower GI endoscopy showed no abnormalities. Upper GI endoscopic findings were consistent with persistent Barrett's esophagus. Histological examination of the rectal polyps exhibited preserved crypt architecture and lamina propria expansion with a dense mixed inflammatory cell infiltrate. Distinctive features included aggregates of histiocytes forming subtle granulomas, with histiocytes displaying small intracytoplasmic basophilic inclusions surrounded by a clear halo (target-like lesions) (Figure 2). These inclusions exhibited a Prussian blue coloration characteristic of Michaelis-Gutmann bodies, confirming the diagnosis of Malakoplakia (Figure 3). Additionally, CD68 immunoperoxidase stain highlighted these histiocytes (Figure 4).

Discussion

Malakoplakia was first reported in 1902 by Michaelis and Gutmann. The term is derived from the Greek adjectives "Malakos" (soft) and "Plakos" (plaque) and describes a rare chronic granulomatous condition [1,2]. This pathology is most frequently encountered in the genitourinary tract (75%). The

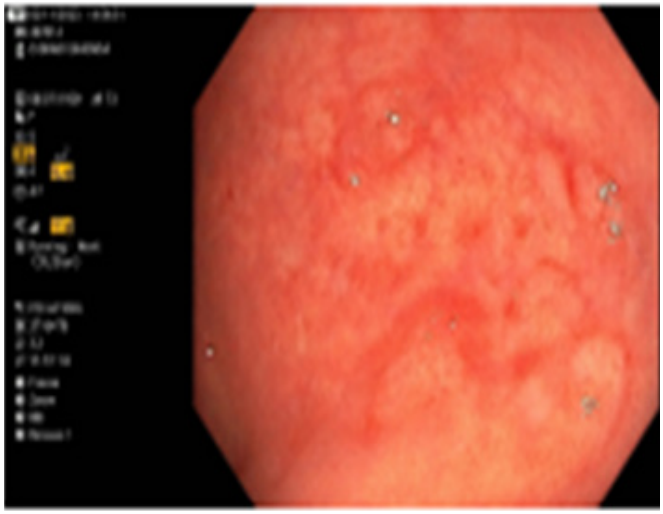

Figure 1: Four rectal polyps -Colonoscopy appearance.

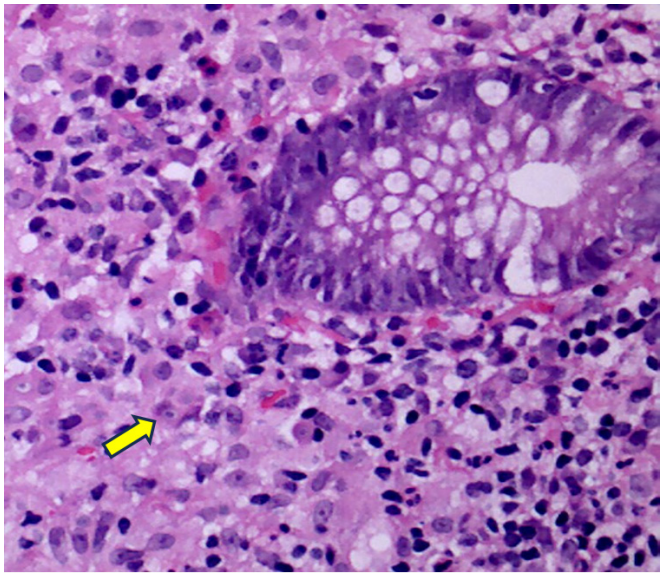

Figure 2: A Michaelis-Gutmaan body (Characteristic inclusion) in histiocytes with a background heavy inflammation (Arrow) X 200 H&E.

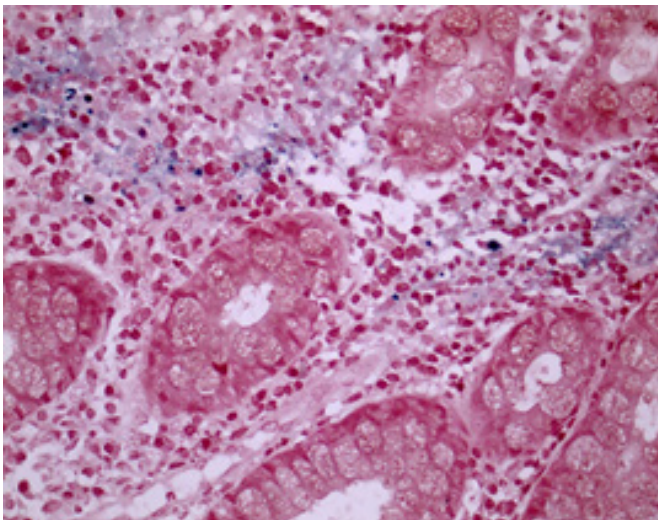

Figure 3: Prussian Blue colour of Michaelis Gutmann bodies X 100 Pearl's stain.

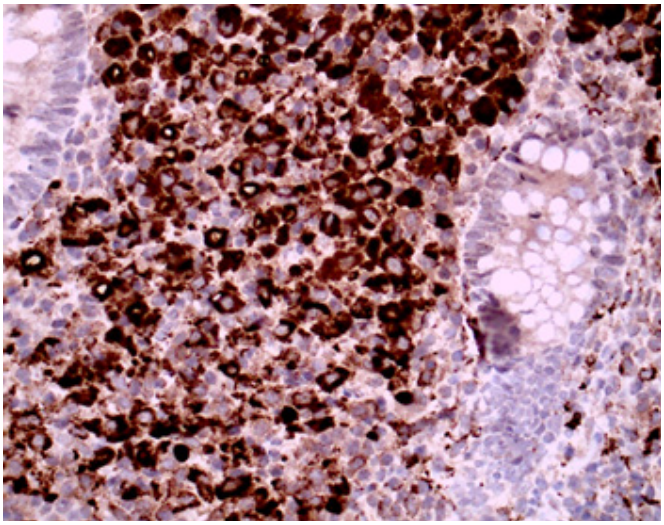

Figure 4: CD 68 positive histiocytes X 200.

gastrointestinal tract is the second most common site, primarily affecting the descending colon, sigmoid, and the rectum [3,4]. The other organs where Malakoplakia can be presented include the liver, pancreas, retroperitoneum, respiratory tract, lymph nodes, and the brain [3,4]. It is four times more common in females and has non-specific, diverse clinical presentations and radiological findings similar to different diseases and cancers [3-5].

Cases related to isolated rectal malakoplakia are rare in the literature, with only a few cases reported, particularly rectal malakoplakia mimicking advanced rectal cancer [5]. The clinical presentation and signs of rectal malakoplakia are not specific and can vary from asymptomatic to diarrhea, abdominal pain, abdominal discomfort, melena, constipation, anorexia, and intestinal obstruction [6,7]. In our case, the patient was asymptomatic, and it was only an incidental finding on colonoscopy.

Although the exact etiology of the disease is debatable, it is hypothesized that a defect in macrophage phagolysosomal response to bacterial infection is the cause [8]. Malakoplakia mostly affects patients with immunodeficiency status, such as those with diabetes, cytotoxic chemotherapy, renal transplantation, tuberculosis, malignancies, and AIDS [9]. Our patient is an immunocompetent individual without a history of illness or drug history causing immunosuppression.

Histology is the gold standard for diagnosing Malakoplakia [10]. Endoscopically, the lesions can be focal or diffuse with varied sizes and shapes, presenting three typical patterns: thickened areas of mucosal erythema, multinodular or massive conditions resembling polyps and cancers, and large mass lesions [7]. The lesions may appear as soft yellow to brown mucosal plaques in the early stages or as gray to tan lesions with different shapes, surrounding congestion, and central depression in the late stages [7]. Histologic examination demonstrates histiocytes with small nuclei and acidophilic granular cytoplasm containing Michaelis-Gutmann bodies, which are calcium and iron inclusions positive for PAS, Pearl's stain, and Von Kossa stain—pathognomonic for Malakoplakia [2,11].

The therapeutic management of Malakoplakia varies, including medical therapy with antibiotics and surgical interventions using different techniques depending on the patient's needs. Medical treatment modalities include antibiotic therapy using agents that interact directly with macrophages, such as quinolones or trimethoprim-sulfamethoxazole, and control of associated immunosuppressive pathology [12]. Endoscopic resections are considered for cases with localized lesions, while surgical resection is recommended for cases with multiple organ infiltration or suspected malignancy [2].

Conclusion

Clinically, radiologically, and endoscopically, Malakoplakia can mimic various pathologies. Therefore, it is crucial to accurately diagnose this rare condition to avoid unnecessary surgical interventions. As highlighted in our case, histology stands as the gold standard for diagnosing Malakoplakia. It should be considered a significant histological differential diagnosis when evaluating colorectal biopsies, even in the absence of a significant history of immunodeficiency.

References

1. Han SH, Joo M, Chang S, et al. Malakoplakia affecting the umbilical cord. J Pathol Transl Med. 2015; 49: 177-179.
2. Șerban C, Toma A, Voicu DC, et al. A Surgical Challenge Generated by Colonic Malakoplakia in Disguise as a Locally Advanced Colonic Malignancy-A Case Report. Medicina Kaunas. 2023; 59: 156.
3. Sagaert X, Tousseyn T, De Hertogh G, et al. Macrophage-related diseases of the gut A pathologist's perspective. Virchows Arch. 2012; 460: 555-567.
4. Zhang Y, Byrnes K, Lam-Himlin D, et al. Gastrointestinal Malakoplakia. Am J Surg Pathol. 2020; 44: 1251-1258.
5. Liu X, Yu C, Zhao Z, et al. Rectal malakoplakia mimicking advanced rectal cancer A case report. Heliyon. 2023; 9: e20780.

6. Yousef GM, Naghibi B, Hamodat MM. Malakoplakia outside the urinary tract. Arch Pathol Lab Med. 2007; 131: 297-300.
7. Hyun KH, Shin HD, Kim DH. Malakoplakia in a healthy young female patient. Korean J Intern Med. 2013; 28: 475-480.
8. Ted George Achufusi, Kegan Jessamy, Philip Chebaya, et al. Rectal malakoplakia Baylor University Medical Center Proceedings. 2020; 33: 389-390.
9. Stanton MJ, Maxted W. Malacoplakia a study of the literature and current concepts of pathogenesis diagnosis and treatment. J Urol. 1981; 125: 139-146.
10. Cipolletta L, Bianco MA, Fumo F, et al. Malacoplakia of the colon. Gastrointest. Endosc. 1995; 41: 255-258.
11. Dario Pastena, Mauro Giambusso, Federica Castri, et al. Malakoplakia of the appendix in a young healthy adult a case report and literature review. J Surg Case Rep. 2022; 8. https://doi.org/10.1093/jscr/rjac357
12. Jeong JW, Noh JH, Kang JH, et al. Cecal malakoplakia A case report. Korean J Clin Oncol. 2021; 17: 44-47.