

## Relapsing of Sever the Pulmonary Hypertension in A Neonate with Low Blood Level of L-Arginine

Nabo Manal Mohamed Helmy<sup>1,2\*</sup> and El Fayomi Sherif<sup>3</sup>

<sup>1</sup>Al Madinah Al Munawwarah, Mouwasat Hospital Department of Pediatric Cardiology.

<sup>2</sup>Sohag Teaching Hospital, Pediatric Cardiology Department, Egypt.

<sup>3</sup>Port Said University, Egypt.

### \*Correspondence:

Nabo Manal Mohamed Helmy, Al Madinah Al Munawwarah, Mouwasat Hospital Department of Pediatric Cardiology, Tel: 00966547090034.

Received: 02 Jan 2023; Accepted: 05 Feb 2023; Published: 10 Feb 2023

**Citation:** Helmy NMM, El Fayomi Sherif. Relapsing of Sever the Pulmonary Hypertension in A Neonate with Low Blood Level of L-Arginine. J Pediatr Neonatal. 2023; 5(1): 1-4.

### Introduction

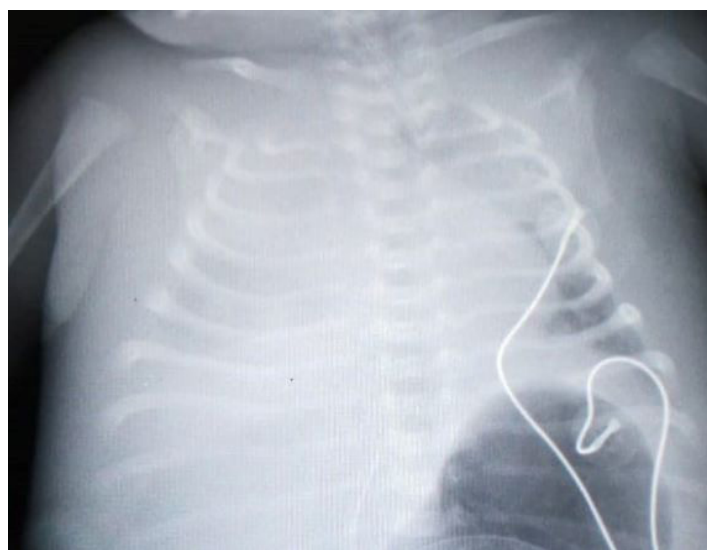
Pulmonary hypertension is a critical condition that need a great attention to the patient condition. The crisis for the first time may looks like cyanotic heart disease. In both condition the oxygen saturation is lower than the normal saturation. The difference between them is done by echocardiography. The importance of diagnosis of pulmonary hypertension is the plan of treatment. There is a great role of nitric oxide to improve the oxygen saturation.

The case is full term baby delivered by caesarian section and had sever meconium aspiration syndrome. The baby presented by cyanosis the oxygen saturation was around 45%. The X ray was done (Figure 1). Urgent echocardiography was done. The finding was severe tricuspid regurgitation (TR) the gradient was 60 mmHg. The mean arterial pressure was 45mmHg. Mild pulmonary regurgitation (PR) and right ventricular dilation. The patient ductus arteriosus (PDA) was right to left shunt. There is right to left shunt at the level of patent foramen oval (PFO).

The patient was admitted and intubated. Nitric oxide was started on the level of 10 PPM. The baby still distressed and the oxygen saturation was still low. The decision was to increase the nitric oxide to the level of 20 PPM. Inhalation of nitric oxide also lowers pulmonary artery pressure in both adults and infants with pulmonary hypertension [1,2]. Nitric oxide directly inhibits endothelin-1 production and release [3].

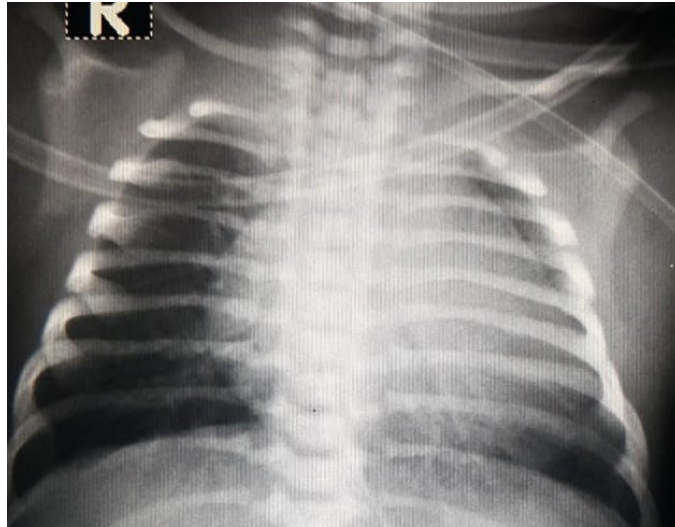
The patient was on ampicillin and gentamycin for 2 days. The baby developed signs of shock on the fifth day. Antibiotic was changed and the piperacillin and vancomycin were started. The blood culture was negative. Metabolic screening was done as routine investigation. The surprise was low level of L- Arginine.

There was advice to start supplementation of L- arginine for 3 days. L-Arginine decreases circulating plasma endothelin-1 levels [4,5] and is likely an added benefit for pulmonary hypertension. The clinical course of the baby was interesting. After ten days of using nitric oxide the baby condition was normal (Figure 2).

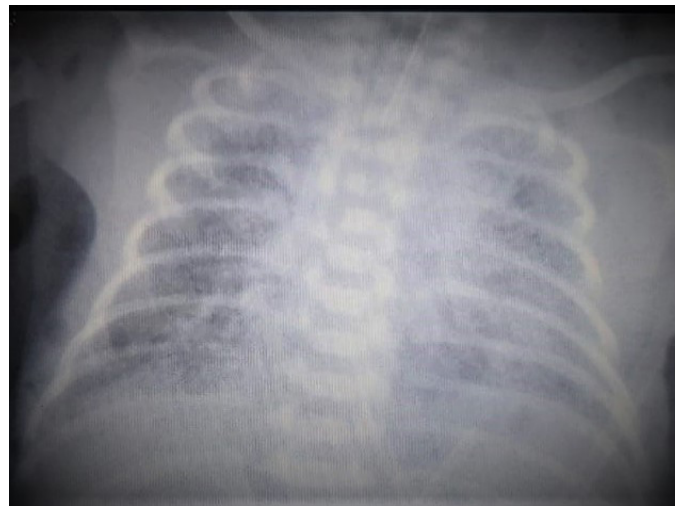


**Figure 1:** Sever pulmonary hypertension due to meconium aspiration syndrome. The x ray shows massive opacities in both the right and the left lungs.

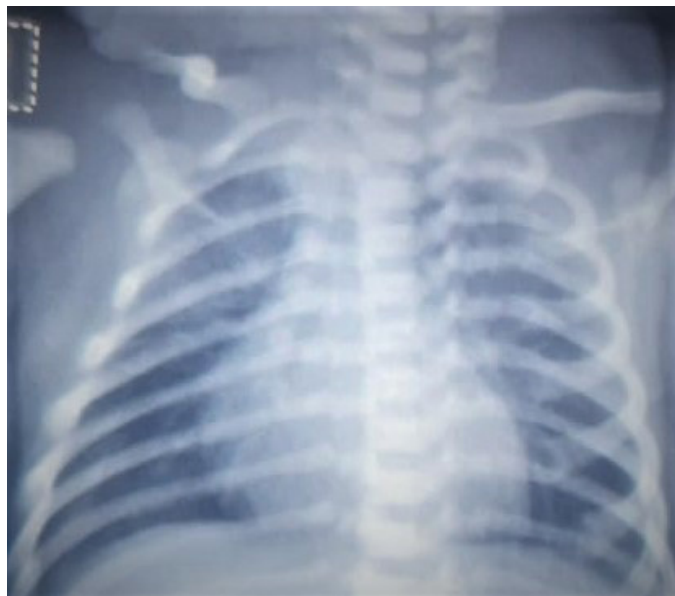Self ex tubation was done and the baby was stable for 2 days. The plan is to discharge the baby, suddenly after 5 days, the general condition of the baby was deteriorated and the signs of pulmonary hypertension was appeared again. At that time, feeding was started with normal formula and no L- Arginine supplementation was used.



**Figure 2:** The right and left lungs start to be inflated. The right atrium is dilated.



**Figure 3:** The x ray was done at the time of clinic follow up. Pulmonary hypertension was diagnosed.



**Figure 4:** The x ray at time of discharge.

---

The baby was re intubated and nitric oxide was started again. For the second time on rebounding of the bad general condition the level of L- Arginine was low. There was no sign or symptom of necrotizing enter colitis (NEC), as there is association between the low level of L- Arginine and the occurrence of NEC. So the plan to start on the maintenance L- Arginine enteral and parenteral infusion. The advice was done and followed up by dietitian. The complete course for nitric oxide and L- Arginine was for 3 weeks. The relation between the low level of L-Arginine and the relapsing of signs and symptom of pulmonary hypertension are highly linked. The baby was stable by the end of the fourth week in the neonatal intensive care unit (NICU). The baby was discharged at home on supplemental L- Arginine. At that time the age was 1 month and planned to follow up in the cardiology and dietitian clinic after discharge by 1 week. Follow up echocardiography shows the presence of sever TR and dilation of the right ventricle and sever pulmonary regurgitation. Complete history was revised. The mother was not give her child the L-Arginine supplementation for 1 weeks as advised by the dietitian. The general condition was deteriorated. Pulmonary hypertension was diagnosed. There was readmission and the decision was to start sildenafil every 12 hour. There was sever respiratory distress. The X ray was done on re admission (Figure 3). There was bad lung condition a picture of sever pulmonary hypertension. After starting sildenafil, the level of L- Arginine was normal for the whole one week of admission. This point should be studied in which the relation between the sildenafil and the level of L-Arginine. The X ray was done at the time discharge (Figure 4). The patient was discharged on sildenafil after one week of admission. The baby was follow up regularly with cardiology clinic and the course was smooth. For two months and half the baby still was on sildenafil.

The plan was to follow up the patient every 2 weeks. Follow up was done and sildenafil was decreased and plan to be stopped at the age of 4 months. Cardiology follow up showed no evidence of pulmonary hypertension. Remolding of the right ventricle was noticed and the amplitude of the tricuspid regurgitation was decreasing. Last visit at the age of 6 months, the cardiac examination by echocardiography was normal. The patient was clear from pulmonary hypertension.

## Discussion

Pulmonary hypertension is a lung pathology. The pathology affects the blood vessels and characterized by new blood vessels formation. The vasa vasorum is the main pathology. This new blood vessel formation result in more delivery of the inflammatory cells that result in remodeling of the blood vessel and narrowing of the lumen of the blood vessels. Optical Coherence Tomography (OCT) is a new technology. The lumen can be visualized and evaluated to how extent the lumen is occupied by new vessels. The all information about the lumen diameter and shape can be seen. Our hope is to use this for clear evaluation and follow up of the patients. The ability of nutritional support using L- Arginine is cheaper and applicable to be used in comparison with medication.

The hypnosis of use of L- Arginine may be related to the effect on the potassium channels. That need more clinical trial on the effect of L- Arginine on the potassium channels.

There are many new line of treatment of pulmonary hypertension. One of this line is the use of inhalation of nitric oxide. Nitric oxide is effective in lowering the pulmonary artery pressures in both adults and infants with pulmonary hypertension [1,2]. Endothelial dysfunction may contribute to the pathogenesis of pulmonary hypertension through impaired production of nitric oxide [6-9].

Plasma levels of endothelin-1, the most potent endothelial derived vasoconstrictor [3,12], are elevated in patients with pulmonary hypertension [10,11]. Nitric oxide directly inhibits endothelin-1 production and release [3]. L- Arginine also decreases circulating plasma endothelin-1 levels [4,5] and is likely an added benefit for pulmonary hypertension.

Pulmonary hypertension in neonates affect both term and preterm baby that results in about 10% to 20% of the mortality rate. There are several causes of pulmonary hypertension in neonates including congenital heart disease, congenital diaphragmatic hernia and sepsis. Persistent pulmonary hypertension of the newborn (PPHN) is a specific type of pulmonary hypertension in neonates. It occurs when the high pulmonary vascular resistance characteristic of fetal circulation fails to decrease at birth, resulting in right-to-left shunting of blood through fetal channels, diminished pulmonary blood flow and profound hypoxemia.

Pulmonary hypertension can be a primary condition or can be secondary to a variety of disorders causing hypoxic ending in respiratory failure. One of the most important causes is meconium aspiration syndrome.

Other causes that result in pulmonary hypertension include sever respiratory distress in premature neonates who suffering from bronchopulmonary dysplasia (BPD). The management of pulmonary hypertension in neonates includes good dealing and observation of vital signs. Good aerations and fluid balance. Continuous monitoring of oxygenation, blood pressure, and perfusion are highly recommended. Sildenafil increases cyclic guanosine monophosphate (cGMP) within pulmonary vascular smooth muscle cells, resulting in relaxation of constricted pulmonary blood vessels. In people with pulmonary arterial hypertension, this can lead to vasodilation of the pulmonary vascular bed and, to a lesser degree, vasodilatation in the systemic circulation.

## Future Plan

The relation between the level of sildenafil and L-Arginine can be studied in clinical trials. In this case, after starting sildenafil, the level of L- Arginine was normal for the whole one week of admission. This point should be studied in which the relation between the sildenafil and the level of L- Arginine.

---

## References

1. Roberts J, Fineman J, Morin F, et al. Inhaled nitric oxide and persistent pulmonary hypertension of the newborn. *N Engl J Med.* 1997; 336: 605-610.
2. Pepke-Zaba J, Higenbottam TW, Dinh-Xuan A, et al. Inhaled nitric oxide as a cause of selective pulmonary vasodilation in pulmonary hypertension. *Lancet.* 1991; 338: 1173-1174.
3. Bassenge E. Endothelial function in different organs. *Prog Cardiovasc Dis.* 1996; 39: 209-228.
4. Lerman A, Burnett JC, Higano St, et al. Long term L-arginine supplementation improves small-vessel coronary endothelial function in humans. *Circulation.* 1998; 97: 2123-2128.
5. Rector TS, Bank AJ, Mullen KA, et al. Randomized, double-blind, placebo-controlled study of supplemental oral L-arginine in patients with heart failure. *Circulation.* 1996; 93: 2135-2141.
6. Mehta S, Stewart D, Langleben D, et al. Short-term pulmonary vasodilation with l-arginine in pulmonary hypertension. *Circulation.* 1995; 92: 1539-1545.
7. Archer S, Djaballah K, Humbert M, et al. Nitric oxide deficiency in fenfluramine and dexfenfluramine-induced pulmonary hypertension. *Am J Respir Crit Care Med.* 1998; 158: 1061-1067.
8. Cooper CJ, Landzberg MJ, Anderson TJ, et al. Role of nitric oxide in the local regulation of pulmonary vascular resistance in humans. *Circulation.* 1996; 93: 266-271.
9. Kaneko FT, Arroliga AC, Dweik RA, et al. Biochemical reaction products of nitric oxide as quantitative markers of primary pulmonary hypertension. *Am J Respir Crit Care Med.* 1998; 158: 917-923.
10. Rubin LJ, Badesch BD, Barst RJ, et al. Bosentan therapy for pulmonary arterial hypertension. *N Engl J Med.* 2002; 346: 896-903.
11. Dupuis J. Endothelin-receptor antagonists in pulmonary hypertension. *Lancet.* 2001; 358: 1113-1114.
12. Phelan M, Perrine SP, Brauer M, et al. Sickle erythrocytes, after sickling, regulate the expression of the endothelin-1 gene and protein in human endothelial cells in culture. *J Clin Invest.* 1995; 96: 1145-1151.