

## Rhabdomyosarcoma of the Testicle in a young adult-Case Report

Dr. Jéshua W Dos santos<sup>1\*</sup>, Dr. Víctor Castillo Celis<sup>2</sup> and Dr. Elizabeth Orellana<sup>3</sup>

<sup>1</sup>Second-year Resident of Surgical Oncology, INCAN, Guatemala.

<sup>2</sup>Head of Unit at INCAN, Guatemala.

<sup>3</sup>Head of Pathology at INCAN, Guatemala.

### \*Correspondence:

Dr. Jéshua W Dos santos, Second-year Resident of Surgical Oncology, INCAN, Guatemala, 1street 10-92, B1 sector 8th zone, Mixco, Guatemala, Tel: (+502) 58438880.

**Received:** 07 Mar 2026; **Accepted:** 10 Apr 2026; **Published:** 21 Apr 2026

**Citation:** Jéshua W Dos santos, Víctor Castillo Celis, Elizabeth Orellana. Rhabdomyosarcoma of the Testicle in a young adult-Case Report. J Pathol Res. 2026; 5(2): 1-3.

### ABSTRACT

*Rhabdomyosarcoma is a type of tumor originating from soft tissues, sifically from striated muscles [1-4]. This type of muscle is mostly in the skeleton between the bones [1]. Meanwhile tumors of the testicle in adults are mostly formed from the germinal cells [2]. The possibilities of a tumor in the testicle formed from striated muscle in adults are very low [2] with only twentyfour cases documented in the world as today [1]. We present a case of rhabdomyosarcoma in a young adult in Guatemala and the result obtained during the diagnosis and treatment of this cancer.*

### Keywords

Rhabdomyosarcoma, Testicular tumors, Young adults.

### Introduction

Rhabdomiosarcoma of the testis is an extremely rare malignant tumor and such as other sarcomas it is very agressive [4]. In children and adolescents it may be more common but in adults especialy over 30 years it is estadisticly unusual with only twenty four case reports as today [1]. Sarcomas come from soft tissue and rhabdo comes from striated muscle cell, this cáncer si very strange tu happen in a organ where the bast mayority of cell are germinal o reprotudctive [2,4]. We present a case of a 31 year male patient with a primary testicular rhadomyosarcoma its managment and evolution.

### Case Description

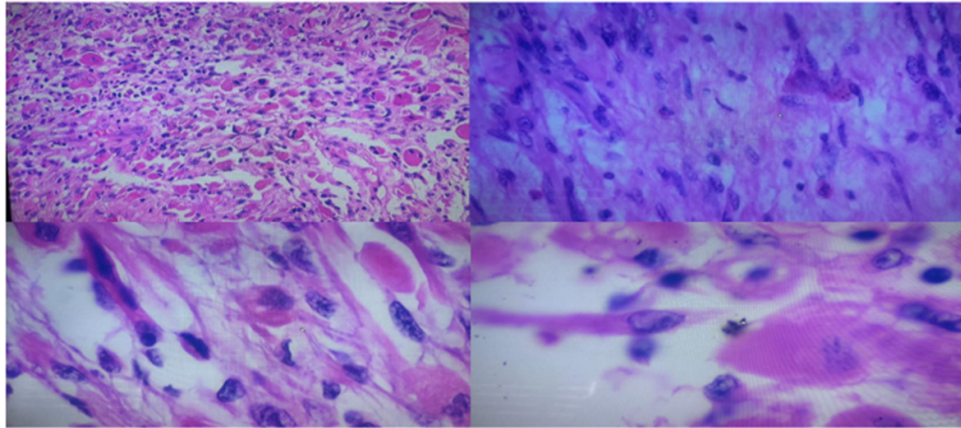
Male patient 30 years old, from a rural village in Guatemala, the patient consulted in July of 2,025 for a progressively growing mass in the left testicle of three months evolution, without other associated symptoms, after the respective evaluation, he underwent surgery in august of 2,025 being a radical orchiectomy performed, without any complications. Testicular markers, lactic dehydrogenase, alpha-fetoprotein abdominal human chorionic gonadotrophin were realized after the surgery with results in

normal range. Also, CT scan of the thorax and abdomen which did not identify any metastatic disease.

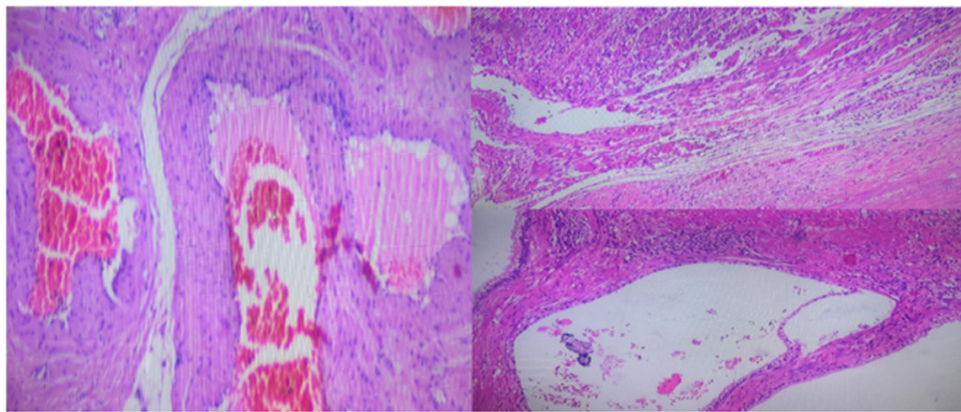
Until now, the case is very similar to others, but when the surgical piece was evaluated, the final diagnosis was a rhabdomyosarcoma. This was a surprising result, so now we are going to describe the findings of the surgical piece after the pathology study. Firstly, like other evaluations it started with a hematofilina and eosine tinction, after the microscopic evaluation the things to notice are the tadpole-shaped cells, where seen this is a classic finding in cells of the stride muscle, also pink eosinophilic round cells, this is showed in Figures 1-4, where we see different takes of the microscopic evaluation and the cells previously mentioned.

Then other interesting founding was tunica albuginea in contact with the neoplasm, without invasion, like showed on Figure 5-7.

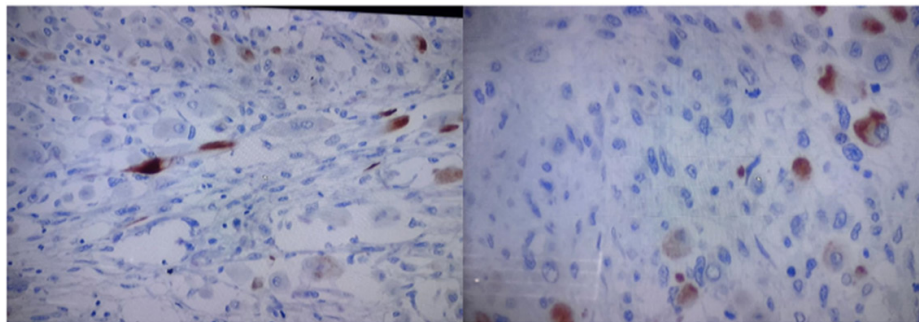
After that immunohistochemistry was performed on the surgical specimen, with the following panel: Smooth muscle actin: weakly positive, Desmin: weakly positive, Myogenin: weakly positive in 3% of spindle and rhabdoid cells, Myo D1: negative, Ki67: positive in 2% of spindle and rhabdoid cells (less than 10%).



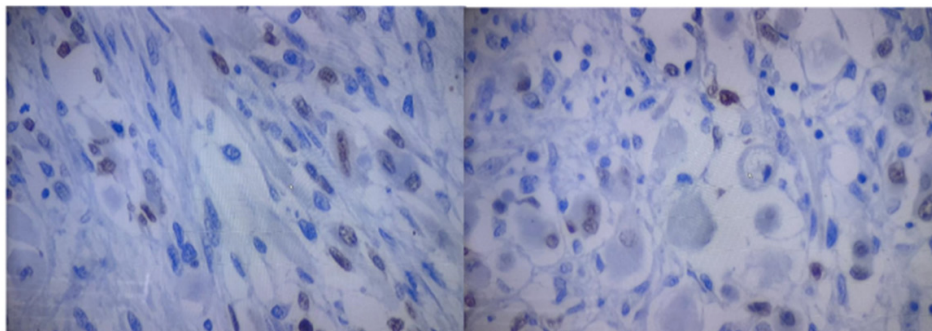
**Figures 1-4:** Mesenchymal type cell with Tadpole-shaped cells, round pink eosinophilic cells.



**Figures 5-7:** Tunica albuginea in contact with neoplasm, without invasion. Vessels lined with endothelium, with an erythrocyte in the center, no malignant cells, therefore no vascular infiltration.



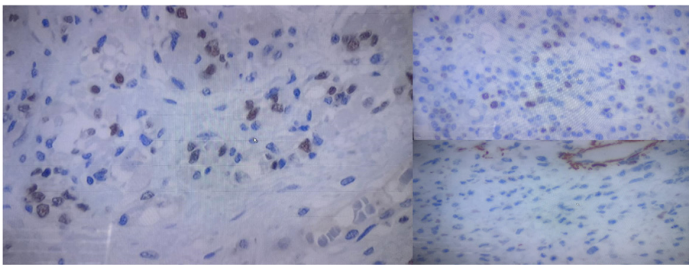
**Figures 8, 9:** Panel of Immunohistochemistry. Desmine.



**Figures 10, 11:** Panel of immunohistochemistry. Myogenine and MYO D1.

This corresponds to a mesenchymal tumor with muscle differentiation, exhibiting a spindle pattern. 80% of cells are positive for Myo-D and 80% for desmin. Smooth muscle actin and mammoglobin are negative (Figures 8-11).

Final pathological diagnosis Embryonic spindle cell rhabdomyosarcoma with foci of mature teratoma. The patient was sent to medical oncology and received 6 cycles of chemotherapy with ifosfamide and doxorubicine, ending in March 2,026. Now patient is under surveillance, studies of image have been performed after the last cycle of chemotherapy and there has not been reported recurrences.



**Figures 12-15:** Panel of immunohistochemistry. Actine and Ki 67

## Discussion

Sarcomas are tumors of soft tissues there are various types and they develop in all the body but mostly where there is more soft tissue, part like the extremities, head and neck [1,4], parts like the testis where soft tissue is not the principal cell sarcomas are really strange and rare. Of the types of sarcomas the rhabdomyosarcoma is a tumor that forms in the striated cells of the muscle [1,4], the testis has this kind of muscle but the formation of tumor from these cells is not the main form of cancer in this anatomic part.

There are two theories about how these tumors originated, the first says that since the muscle cells are embryonic they develop a displacement that mutates during the early life of the patient and until a certain time presents like a tumor, the second says that there is rhabdomyolysis due to dedifferentiated mesenchymal cells. However, neither of the theories has been demonstrated yet [3].

Diagnosis initially is not different from other testicular tumor, because it presents clinically with the same symptoms. Patients present with a testicular mass that grows and produces pain or discomfort so it makes the young male seek medical attention, typically the mass is only in one testicle [1]. Tumor markers of germinal testicular cancers are in this case normal because of the origin cell of the tumor being a muscular cell and not a germinal cell, so this tool is not useful in this case only for suspecting a non

germinal tumor [3,5].

Other points like the clinical examination of image studies are not different from patients with other kind of testicular cancer. What makes the huge difference is the pathologic examination of the surgical piece, this should include histopathologic and immunohistochemistry review [2,3,5], where muscle tests like actin, desmin, MYO D1 and especially myogenin are key for the diagnosis [2]. Also the negativity of other markers like SMA (smooth muscle actin) and others of the category of CD (cluster of differentiation) make a diagnosis by exclusion [2,3,5].

Management if we see it in a surgical field is the same as other tumor, we know that sarcomas are not tumors likely to make metastasis to lymph nodes so the treatment is a radical orchiectomy. The adjuvant treatment is what makes it controversial and is not standard, with every case being individualized, due to the rareness of the cases. But a logical treatment is after the surgical part that is and should be the main treatment, include chemotherapy, with or without radiation, this because the rhabdomyosarcomas are aggressive tumors that disseminate through the bloodstream and make metastasis in distant parts that can not be cured just with the radical orchiectomy. The regimen of chemotherapy and radiation are not well defined and most of the articles include the same kind of treatments as other tumors of the testis not sarcomas [3]. Also other types of treatment like the use only of radiotherapy has been used but the results have been poor [3]. Prognosis has increased because of the better knowledge in general of the treatment of rhabdomyosarcomas and the recent use of multidisciplinary groups [3].

## References

1. Zou J, Luo P, Chen T, et al. Embryonal rhabdomyosarcoma of the testis in a young male: a rare case report. *Asian J Surg.* 2023; 3: S1015-S9584.
2. Wu R, Liu X, Song Y, et al. Spontaneous rupture of rhabdomyosarcoma of the testis with unilateral ptosis: a case report and literature review. *Front Pediatr.* 2022; 10: 904275.
3. Yahaya JJ, Mremi A. Primary intratesticular rhabdomyosarcoma in children: a case report and review of the literature. *J Med Case Rep.* 2021; 15: 37.
4. WHO Classification of Tumours Editorial Board. Soft tissue and bone tumours. WHO Classification of Tumours Series, International Agency for Research on Cancer, Lyon (France). 2020.
5. Chen X, Zou C, Yang C, et al. Pleomorphic rhabdomyosarcoma of the spermatic cord and a secondary hydrocele testis: a case report. *World J Clin Cases.* 2020; 8: 2641-2646.